

# EAU GUIDELINES ON PRIMARY URETHRAL CARCINOMA

*(Limited text update April 2024)*

Y. Neuzillet, J.A. Witjes (Chair), H.M. Bruins, A. Carrión, R. Cathomas, E.M. Compérat, J.A. Efstathiou, R. Fietkau, A.G. van der Heijden, A. Lorch, P. Mariappan, R.P. Meijer, M.I. Milowsky, V. Panebianco, M. Rink, M. Rouanne, G.N. Thalmann

Patient Advocates: J. Redlef, S. Sæbjørnsen

Guidelines Associates: M. Kailavasan, A. Martini, L.S. Mertens

Guidelines Office: E.J. Smith, H. Ali

## **Epidemiology**

Primary Urethral Carcinoma is a rare cancer, accounting for < 1% of all genitourinary malignancies. The age-standardised ratio is 4.3/million in men and 1.5/million in women, with a male to female ratio of 2.9:1.

## **Aetiology**

Predisposing factors in males include urethral strictures, chronic irritation after intermittent catheterisation/ urethroplasty, external beam irradiation therapy, radioactive seed implantation, chronic urethral inflammation following sexually transmitted diseases (especially human papilloma virus) and lichen sclerosus. In females, urethral diverticula and recurrent urinary tract infections have been associated with the development of primary urethral carcinoma.

## Staging and Grading systems

The 2017 TNM classification (8<sup>th</sup> edition) is used for the staging of urethral carcinoma. Of note, a separate staging system exists for urothelial carcinoma (UC) of the prostatic urethra.

<b>T - Primary Tumour</b>	
TX	Primary tumour cannot be assessed
T0	No evidence of primary tumour
<b>Urethra (male and female)</b>	
Ta	Non-invasive papillary, polypoid, or verrucous carcinoma
Tis	Carcinoma <i>in situ</i>
T1	Tumour invades subepithelial connective tissue
T2	Tumour invades any of the following: corpus spongiosum, prostate, periurethral muscle
T3	Tumour invades any of the following: corpus cavernosum, beyond prostatic capsule, anterior vagina, bladder neck (extraprostatic extension)
T4	Tumour invades other adjacent organs (invasion of the bladder)
<b>Urothelial (transitional cell) carcinoma of the prostate</b>	
Tis pu	Carcinoma <i>in situ</i> , involvement of prostatic urethra
Tis pd	Carcinoma <i>in situ</i> , involvement of prostatic ducts
T1	Tumour invades subepithelial connective tissue (for tumours involving prostatic urethra only)
T2	Tumour invades any of the following: prostatic stroma, corpus spongiosum, periurethral muscle
T3	Tumour invades any of the following: corpus cavernosum, beyond prostatic capsule, bladder neck (extraprostatic extension)
T4	Tumour invades other adjacent organs (invasion of the bladder or rectum)

<b>N - Regional Lymph Nodes</b>	
NX	Regional lymph nodes cannot be assessed
N0	No regional lymph node metastasis
N1	Metastasis in a single lymph node
N2	Metastasis in multiple lymph nodes
<b>M - Distant Metastasis</b>	
M0	No distant metastasis
M1	Distant metastasis

## Histopathology

Urothelial carcinoma of the urethra is the predominant histological type in men with primary urethral carcinoma followed by squamous cell carcinoma (SCC) and adenocarcinoma (AC).

In women, recent studies report higher rates of adenocarcinoma, followed by SCC rather than UC. Specimen handling should follow the general rules as published by the International Collaboration on Cancer Reporting.

<b>Recommendation for staging and grading</b>	<b>Strength rating</b>
Use the 2017 TNM classification and 2022 WHO grading system for pathological staging and grading of primary urethral carcinoma.	Strong

## Diagnosis

Diagnosis of primary urethral carcinoma is based on clinical examination, urine cytology, urethroscopy with biopsy and cross-sectional imaging for the assessment of the primary tumour, lymph nodes (LNs) and distant organs. Patients with clinically enlarged inguinal or pelvic LNs often exhibit pathological LN metastasis.

Recommendations	Strength rating
Use urethrocytostcopy with biopsy and urinary cytology to diagnose urethral carcinoma.	Strong
Assess the presence of distant metastases by computed tomography of the thorax and abdomen/pelvis.	Strong
Use pelvic magnetic resonance imaging to assess the local extent of urethral tumour and regional lymph node enlargement.	Strong

## Prognosis

The majority of patients are diagnosed late, with local symptoms due to advanced disease and the prognosis is poor.

Risk factors for survival include age, race, tumour stage, grade, nodal stage, presence of distant metastasis, histological type, tumour size, tumour location, concomitant bladder cancer and the type and modality of treatment, as well as the type of treating facility. In locally-advanced UC and SCC of the urethra, treatment in academic centres improves overall survival (OS).

## Disease management

### *Primary disease in males*

Distal urethral tumours exhibit significantly improved survival rates compared with proximal tumours. Therefore, optimising treatment of distal urethral carcinoma has become the focus of clinicians to improve functional outcome and quality of life, while preserving oncological safety. Penile-preserving surgery for tumours confined to the corpus spongiosum (stage  $\leq$  T2) using various reconstructive techniques has been investigated. In distal urethral tumours performing a partial urethrectomy with a minimal safety margin does not increase the risk of local recurrence when complete circumferential assessment of the margins shows no evidence of disease.

Recommendations	Strength rating
Offer distal urethrectomy as an alternative to penile amputation in localised distal urethral tumours, if negative surgical margins can be achieved intra-operatively.	Weak
Ensure complete circumferential assessment of the proximal urethral margin if penile-preserving surgery is intended.	Strong

### *Localised primary disease in females*

In women with distal tumours, urethra-sparing surgery and local radiotherapy (RT) present alternatives to primary urethrectomy but are associated with increased risk of tumour recurrence and local toxicity.

Recommendations	Strength rating
Offer urethra-sparing surgery, as an alternative to primary urethrectomy, to females with distal urethral tumours, if negative surgical margins can be achieved intra-operatively.	Weak
Offer local radiotherapy, as an alternative to urethral surgery, to females with localised urethral tumours, but discuss local toxicity.	Weak

### *Multimodal therapy in advanced disease in both males and females*

Multimodal therapy in primary urethral carcinoma consists of definitive surgery plus chemotherapy with the option of additional RT. Multimodal therapy is often underutilised in locally-advanced disease. It confers an OS benefit in primary urethral carcinoma of urothelial origin.

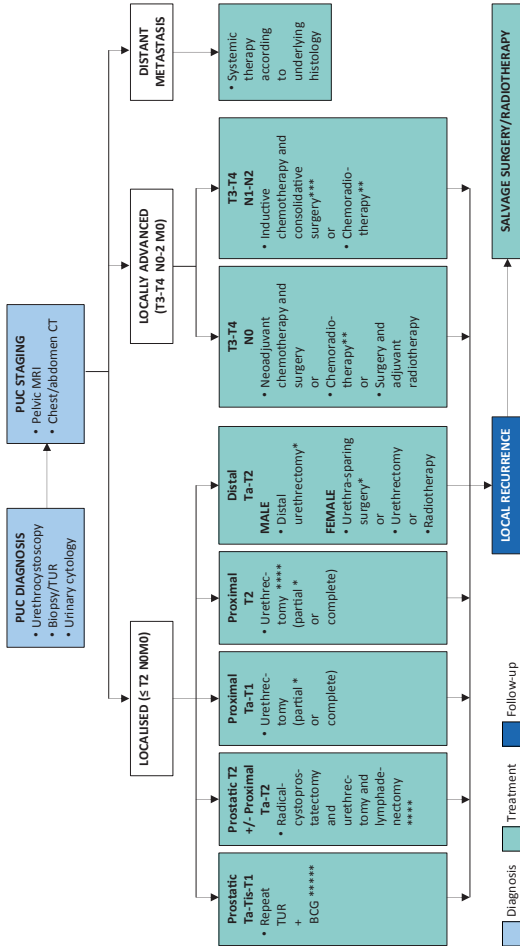
<b>Recommendations</b>	<b>Strength rating</b>
Refer patients with advanced urethral carcinoma to academic centres.	Strong
Discuss treatment of patients with locally-advanced urethral carcinoma within a multidisciplinary team of urologists, radiation-oncologists, and oncologists.	Strong
In locally-advanced urethral carcinoma, use cisplatin-based chemotherapeutic regimens with curative intent prior to surgery.	Weak
In locally-advanced squamous cell carcinoma (SCC) of the urethra, offer the combination of curative radiotherapy (RT) with radiosensitising chemotherapy for definitive treatment and genital preservation.	Weak
Offer salvage surgery or RT to patients with urethral recurrence after primary treatment.	Weak
Offer inguinal lymph node (LN) dissection to patients with limited LN-positive urethral SCC.	Weak

### Treatment of urothelial carcinoma of the prostate

Local conservative treatment with extensive transurethral resection (TUR) and subsequent bacillus Calmette-Guerin (BCG) instillation is effective in patients with Ta or Tis prostatic urethral carcinoma. Patients undergoing TUR of the prostate for prostatic urethral carcinoma prior to BCG treatment show superior complete response rates compared to those who do not.

Recommendations	Strength rating
Offer a urethra-sparing approach with transurethral resection (TUR) and bacillus Calmette-Guérin (BCG) to patients with non-invasive urethral carcinoma or carcinoma <i>in situ</i> of the prostatic urethra and prostatic ducts.	Strong
In patients not responding to BCG, or in patients with extensive ductal or stromal involvement, perform a cystoprostatectomy with extended pelvic lymphadenectomy.	Weak

**Figure 1: Management of primary urethral carcinoma**





- \* Ensure complete circumferential assessment if penile-preserving/urethra-sparing surgery or partial urethrectomy is intended.
- \*\* Squamous cell carcinoma.
- \*\*\* Regional lymphadenectomy should be considered in clinically enlarged lymph nodes.
- \*\*\*\* Consider neoadjuvant chemotherapy.
- \*\*\*\*\* In extensive or BCG-unresponsive disease: consider (primary) cystoprostatectomy +/- urethrectomy + lymphadenectomy.

*BCG = bacillus Calmette-Guérin; CT = computed tomography; MRI = magnetic resonance imaging; PUC = primary urethral carcinoma; TUR = transurethral resection.*

## Follow-up

Given the low incidence of primary urethral carcinoma, follow-up has not been systematically investigated. Therefore, it seems reasonable to tailor surveillance regimens according to patients' individual risk factors. In patients undergoing urethra-sparing surgery, it seems prudent to advocate a more extensive follow-up with urinary cytology, urethrocystoscopy and cross-sectional imaging despite the lack of specific data.

*This short booklet is based on the more comprehensive EAU Guidelines (ISBN 978-94-92671-23-3), available on the EAU website: <http://www.uroweb.org/guidelines/>.*