

EAU-ASCO Collaborative Guidelines on Penile Cancer

O.R. Brouwer (co-chair), S.T. Tagawa (co-chair), M. Albersen,
B. Ayres, J. Crook, M.S. van der Heijden, P.A.S. Johnstone,
A. Necchi, P. Oliveira, L.C. Pagliaro, A. Parnham,
C.A. Pettaway, C. Protzel, R.B. Rumble,
D. Sánchez Martínez, P.E. Spiess
Patient Advocates: K. Manzie, J-D. Marcus, J. Osborne
Panel Associates: T. Antunes-Lopes, L. Barreto, R. Campi,
S. Fernandez Pello, H.A. Garcia-Perdomo, I. Greco,
M. Kailavasan, A. Sachdeva, V. Sakalis, L. Zapata



© European Association of Urology 2024
& American Society of Clinical Oncology



TABLE OF CONTENTS

PAGE

1.	INTRODUCTION	5
	1.1 Aim and objectives	5
	1.2 Panel composition	5
	1.3 Available publications	5
	1.4 Publication history	5
	1.5 Preface	5
2.	METHODS	6
	2.1 Data identification	6
	2.2 Review and future goals	7
3.	EPIDEMIOLOGY, AETIOLOGY AND PATHOLOGY	7
	3.1 Definition of penile cancer	7
	3.2 Epidemiology	8
	3.3 Risk factors, prognosis, and prevention	9
	3.4 Pathology	10
	3.4.1 Gross handling of pathology specimens	10
	3.4.2 Pathology report	11
	3.4.3 Grading	11
	3.4.4 Pathological prognostic factors	12
	3.4.5 Penile cancer and HPV	12
	3.4.6 Penile biopsy: pathological and technical considerations	13
	3.4.7 Summary of evidence and guidelines for the pathological assessment of tumour specimens	13
4.	CLASSIFICATION SYSTEMS	13
	4.1 TNM classification	13
	4.2 Cancer stage grouping	15
5.	DIAGNOSTIC EVALUATION AND STAGING	15
	5.1 Primary lesion	15
	5.1.1 Physical examination	15
	5.1.2 Imaging of the primary tumour	15
	5.1.3 Penile biopsy: indications	15
	5.2 Lymph node staging	15
	5.2.1 Physical examination	16
	5.2.2 Clinically node-negative patients (cN0)	16
	5.2.2.1 Non-surgical staging options	16
	5.2.2.2 Indications for surgical staging	16
	5.2.2.3 Surgical staging options	17
	5.2.3 Clinically node-positive patients (cN+)	17
	5.3 Summary of evidence and guidelines for the diagnosis and staging of penile cancer	17
6.	DISEASE MANAGEMENT	18
	6.1 Treatment of the primary tumour	18
	6.1.1 Treatment of superficial non-invasive disease (PeIN, Ta)	19
	6.1.1.1 Topical therapies	19
	6.1.1.2 Laser ablation	19
	6.1.1.3 Surgery	19
	6.1.2 Treatment of invasive disease confined to the glans (cT1/T2)	20
	6.1.2.1 Width of negative surgical margins	20
	6.1.2.2 The use of intra-operative frozen section assessment	20
	6.1.2.3 Laser ablation	21
	6.1.2.4 Moh's micrographic surgery	21
	6.1.2.5 Wide local excision and circumcision	21
	6.1.2.6 Glans resurfacing	21

	6.1.2.7	Glansectomy	22
	6.1.2.8	Partial penectomy	22
	6.1.2.9	Radiotherapy for T1 and T2 disease	22
6.1.3		Locally advanced disease (T3–T4)	23
	6.1.3.1	Resectable disease	23
	6.1.3.2	Non-resectable disease	23
6.1.4		Local recurrence after organ-sparing surgery	24
6.1.5		Summary of evidence and guidelines for local treatment of penile carcinoma	24
6.2		Regional lymph node management: clinically evident disease (cN1–cN3)	25
	6.2.1	Introduction	25
	6.2.2	cN1–N2 disease: radical inguinal lymph node dissection	25
	6.2.2.1	Indication for radical inguinal lymph node dissection	25
	6.2.2.2	What is an acceptable definition?	26
	6.2.2.3	Quality metrics	26
	6.2.2.3.1	Lymph node yield and density	26
	6.2.2.3.2	Timing of surgery	26
	6.2.2.4	Complications	27
	6.2.2.5	Open versus minimally-invasive approach	27
	6.2.2.6	Summary of evidence and guidelines for radical inguinal lymph node dissection in cN1-2 disease	28
	6.2.3	Prophylactic pelvic lymph node dissection	28
	6.2.3.1	Indications for prophylactic pelvic lymph node dissection	28
	6.2.3.1.1	Risk factors for pelvic nodal metastasis	28
	6.2.3.2	What is an acceptable dissection?	28
	6.2.3.3	Survival and recurrence	29
	6.2.3.4	Complications	29
	6.2.3.5	Minimally-invasive versus open pelvic lymph node dissection	29
	6.2.3.6	Summary of evidence and guidelines for prophylactic pelvic lymph node dissection	29
6.3		Clinical N3 disease (cN3)	29
	6.3.1	Diagnostic evaluation	29
	6.3.2	Management strategy	29
	6.3.3	Patient selection for consolidative radical inguinal/pelvic lymphadenectomy	30
	6.3.4	Surgical technique	30
	6.3.4.1	Inguinal lymph node dissection	30
	6.3.4.2	Lymphadenectomy boundaries	30
	6.3.4.3	Pelvic lymph node dissection	30
	6.3.4.4	Surgical complications in cN3 disease	30
	6.3.5	Summary of evidence and guidelines for the surgical management of cN3 disease	30
6.4		Role of multimodal chemotherapy/radiotherapy in the management of (regional) lymph nodes	31
	6.4.1	Systemic therapy	31
	6.4.1.1	Neoadjuvant chemotherapy	31
	6.4.1.2	Adjuvant chemotherapy	32
	6.4.1.3	Summary of evidence and guidelines for neoadjuvant and adjuvant chemotherapy	32
	6.4.2	Radiotherapy	33
	6.4.2.1	Pre-operative radiation therapy	33
	6.4.2.2	Post-operative radiation therapy	33
	6.4.2.3	Summary of evidence and guidelines for pre- and post-operative radiotherapy	34
6.5		Systemic and palliative therapies for advanced disease	34
	6.5.1	Introduction	34
	6.5.2	Chemotherapy	35
	6.5.2.1	Immunotherapy	35
	6.5.2.2	Targeted therapies	36
	6.5.3	Role of radiotherapy in palliation	36
	6.5.4	Summary of evidence and guidelines for systemic and palliative therapies for advanced penile cancer	36

7.	FOLLOW-UP AND QUALITY OF LIFE	36
7.1	Unmet needs	36
7.2	Rationale for follow-up	37
7.2.1	When and how to follow-up	37
7.2.2	Recurrence of the primary tumour	37
7.2.3	Regional recurrence	37
7.3	Patient support services	38
7.3.1	Psychological support	38
7.3.2	Quality of life	38
7.3.3	Urinary function	39
7.3.4	Sexual function	40
7.3.5	Lymphoedema	40
7.4	Centralisation of penile cancer services	41
7.5	Summary of evidence and guidelines for follow-up and quality of life	42
8.	REFERENCES	43
9.	CONFLICT OF INTEREST	61
10.	CITATION INFORMATION	61

1. INTRODUCTION

1.1 Aim and objectives

The European Association of Urology (EAU) - American Society of Clinical Oncology (ASCO) Guidelines on Penile Cancer provide up-to-date information on the diagnosis and management of penile squamous cell carcinoma (SCC).

It must be emphasised that clinical guidelines present the best level of evidence available to the experts but following guideline recommendations will not necessarily result in the best treatment-related outcomes for a given patient. Guidelines can never replace clinical expertise when making treatment decisions for individual patients, but rather help to focus decisions. Taking patient's personal values and preferences/individual circumstances into account is of paramount importance. Guidelines are not mandates and do not purport to be a legal standard of care.

1.2 Panel composition

The EAU-ASCO Penile Cancer Guidelines Panel consists of an international multi-disciplinary group of clinicians, including urologists, pathologists, oncologists, radiation oncologists, and patient advocates. The members of this Panel have been selected based on their expertise and to represent the multi-disciplinary professionals caring for patients suspected of having penile cancer. All experts involved in the production of this document have submitted potential conflict of interest statements, which can be viewed on the EAU website Uroweb: <http://uroweb.org/guideline/penile-cancer/>.

1.3 Available publications

A quick reference document (Pocket guidelines) is available. This is an abridged version which may require consultation together with the full text version. This 2023 updated document presents a complete revision of the prior (2018) publication. All prior versions can be viewed at the EAU website: <https://uroweb.org/guidelines/archive/penile-cancer>.

1.4 Publication history

The EAU Penile Cancer Guidelines were first published in 2000; the current 2023 EAU-ASCO publication presents a complete revision of the prior print. The next update of the Penile Cancer Guidelines will be published in 2026.

1.5 Preface

Penile cancer has a significant impact on quality of life (QoL) in many ways. Patients not only suffer the psychological and emotional stress of a cancer diagnosis and what that means for the rest of their lives, but also the psychological impact and stigma of cancer on an intimate part of the body. The treatments also cause significant physical and emotional changes, resulting in feelings of mutilation, loss of masculinity and coping with the impact on voiding and sexual function, which in turn can result in relationship breakdowns and withdrawal from society. Long-term managing lymphoedema also presents a challenge for many of these men.

As a Guideline Panel, we have chosen to stress the importance of QoL in penile cancer at the beginning of our guidelines, we feel strongly that these significant emotional, social, and physical needs are discussed and addressed early in the patient pathway, through a holistic and multi-disciplinary approach. An important part of a holistic approach is access to palliative care. The World Health Organization (WHO) definition of palliative care states it *"is a crucial part of integrated, people-centered health services. Relieving serious health-related suffering, be it physical, psychological, social, or spiritual, is a global ethical responsibility"* [1]. As a result, access to palliative care should be available to patients throughout their cancer pathway.

It is important to recognise the evolving needs of a patient with a diagnosis of penile cancer, even several months following the completion of treatment, and therefore appropriate follow-up and patient support services are also a critical aspect of penile cancer care.

Reality is that much of the literature on this rare cancer over the last two decades has focused on oncological outcomes rather than functional- and QoL outcomes. So much more needs to be done to investigate these issues and address the many unmet needs of patients diagnosed with penile cancer, some of which are described in Table 1.1 [2].

Table 1.1: Unmet needs of penile cancer patients

Emotional needs	Relationship needs	Medical needs
Loss of masculinity	Impact on relationship with partner	Lack of advice on how to cope
Shock/disbelief	Sexual	Lymphoedema
Depression/sadness	Performance anxiety/cannot satisfy partner	Lack of information on what to expect after surgery
Fear	Concerns on how to tell family	Sit down to urinate/cleanliness of toilets
Anxiety	Relationships damaged or lost	Lack of rehabilitation/supportive care
Embarrassment/stigma	Avoiding meeting friends/new relationships	Missed/incorrect diagnosis

2. METHODS

2.1 Data identification

For the 2023 Penile Cancer Guidelines, new and relevant evidence has been identified, collated and appraised through a structured assessment of the literature. Comprehensive literature searches were done for two major sections: epidemiology, aetiology, pathology and patient support services. Databases searched included Medline, EMBASE and the Cochrane Libraries.

All search histories are available online, as are the protocols and publications of the various systematic reviews (SRs).

For the remaining sections of the text three SRs were conducted:

- Review 1. What Is the Most Effective Management of the Primary Tumor in Men with Invasive Penile Cancer: A Systematic Review of the Available Treatment Options and Their Outcomes [3].
- Review 2. Management of lymph node-positive penile cancer: a systematic review (in peer review).
- Review 3. Systematic review and meta-analysis of minimally-invasive procedures for inguinal nodal staging in penile carcinoma: DSNB and VEIL (manuscript in preparation).

Recommendation within the Guidelines are developed by the panels to prioritise clinically important care decisions. The strength of each recommendation is determined by the balance between desirable and undesirable consequences of alternative management strategies, the quality of the evidence (including certainty of estimates), and the nature and variability of patient values and preferences [4, 5]. This decision process, which can be reviewed in the strength rating forms which accompany each guideline statement, addresses a number of key elements:

1. the overall quality of the evidence which exists for the recommendation [6];
2. the magnitude of the effect (individual or combined effects);
3. the certainty of the results (precision, consistency, heterogeneity and other statistical or study related factors);
4. the balance between desirable and undesirable outcomes;
5. the impact of patient values and preferences on the intervention.

Strong recommendations typically indicate a high degree of evidence quality and/or a favourable balance of benefit to harm and patient preference. Weak recommendations typically indicate availability of lower quality evidence, and/or equivocal balance between benefit and harm, and uncertainty or variability of patient preference [7].

Additional information can be found in the general Methodology section of this print, and online at the EAU website; <http://www.uroweb.org/guideline/>. A list of associations endorsing the EAU Guidelines can also be viewed online at the above address.

2.2 Review and future goals

This document was subject to independent peer review prior to publication. Publications ensuing from published SRs have all been peer reviewed.

The results of ongoing SRs will be included in the 2026 update of the ASCO-EAU Penile Cancer Guidelines. One such review is currently ongoing:

- Systematic review and meta-analysis of minimally-invasive procedures for inguinal nodal staging in penile carcinoma: DSNB and VEIL.

3. EPIDEMIOLOGY, AETIOLOGY AND PATHOLOGY

3.1 Definition of penile cancer

More than 95% of penile cancers are SCCs. There are several recognised subtypes of penile SCC with different clinical features and natural history (see Table 3.1). Penile SCC usually arises from the epithelium of the inner prepuce or the glans.

Table 3.1: Histological subtypes of penile carcinomas according to the 2020 WHO Classification [8, 9], frequency and outcomes (Modified from [10])

Subtype	Frequency (% of cases)	Mortality (%)	Other features
HPV-independent SCC			
Usual	45 – 75	20 – 38	Diagnosis of exclusion. Various degrees of differentiation
Pseudohyperplastic*	< 1	0	Well-differentiated, superficially spreading simulating pseudoepitheliomatous hyperplasia
Pseudoglandular*	< 1	30	Poorly-differentiated carcinoma with acantholytic pseudolumina simulating glands
Verrucous	3 – 8	0	Extremely well-differentiated, broad-based, and pushing tumour front. No metastasis reported
Cuniculatum	< 1	0	Endophytic labyrinthine growth pattern with broad-based pushing margins.
Papillary	2 – 15	0 – 6	Papillae covered by well- to moderately differentiated cells without koilocytes
Sarcomatoid	1 -7	45 – 90	Biphasic epithelial and spindle cell neoplasia. Most aggressive and worse prognosis.
Mixed	10 – 19	3 – 7	Two or more subtypes in the same specimen. Prognosis is related to the subtypes involved.
HPV-associated			
Basaloid	4 – 10	21 – 67	Uniform basaloid cells in nests or sheets, with comedonecrosis or abrupt keratinisation.
Warty	5 – 10	0 – 10	Condylomatous papillae with central fibrovascular cores and koilocytes.
Clear cell	< 1	20 – 30	Nests or sheets of cells with ample, clear cytoplasm with central of geographical necrosis.
Lymphoepithelioma-like	< 1	Unknown	Poorly differentiated cells intermixed with dense lymphoplasmacytic and eosinophilic infiltrate.
Mixed	4 - 10	30 - 50	Mainly Warty-basaloid carcinoma according to the WHO 2022.

Others			
SCC NOS (not-otherwise specified)	Unknown	Unknown	Keratinizing carcinoma. This must be used only when evaluation of p16 is not available.
Adenosquamous	1 – 2	0–14	Squamous tumour nests intermixed with a minor mucinous glandular component.
Mucoepidermoid	Unknown	Unknown	Clear separation between adenosquamous and mucoepidermoid is not provided in the WHO classification. Salivary glands criteria can be applied but there is no consensus.

HPV = human papillomavirus; SCC = squamous cell carcinoma; WHO = World Health Organization.

* WHO 2022 classification consider these subtypes part of usual SCC.

** This is considered a variant of the cuniculatum carcinoma.

3.2 Epidemiology

Penile cancer incidence varies across the world (Fig. 3.1). In industrialised countries, penile cancer is uncommon, with an overall incidence of around 0.94/100,000 males in Europe and 0.5 in the USA [11, 12]. In contrast, in South America, Southeast Asia and parts of Africa, the incidence is much higher and can account for 1–2% of malignant disease in men [12]. The annual age-adjusted incidence is 0.7–3.0 in India, 8.3 in Brazil (per 100,000, respectively) and is higher in parts of Africa such as Uganda [12, 13].

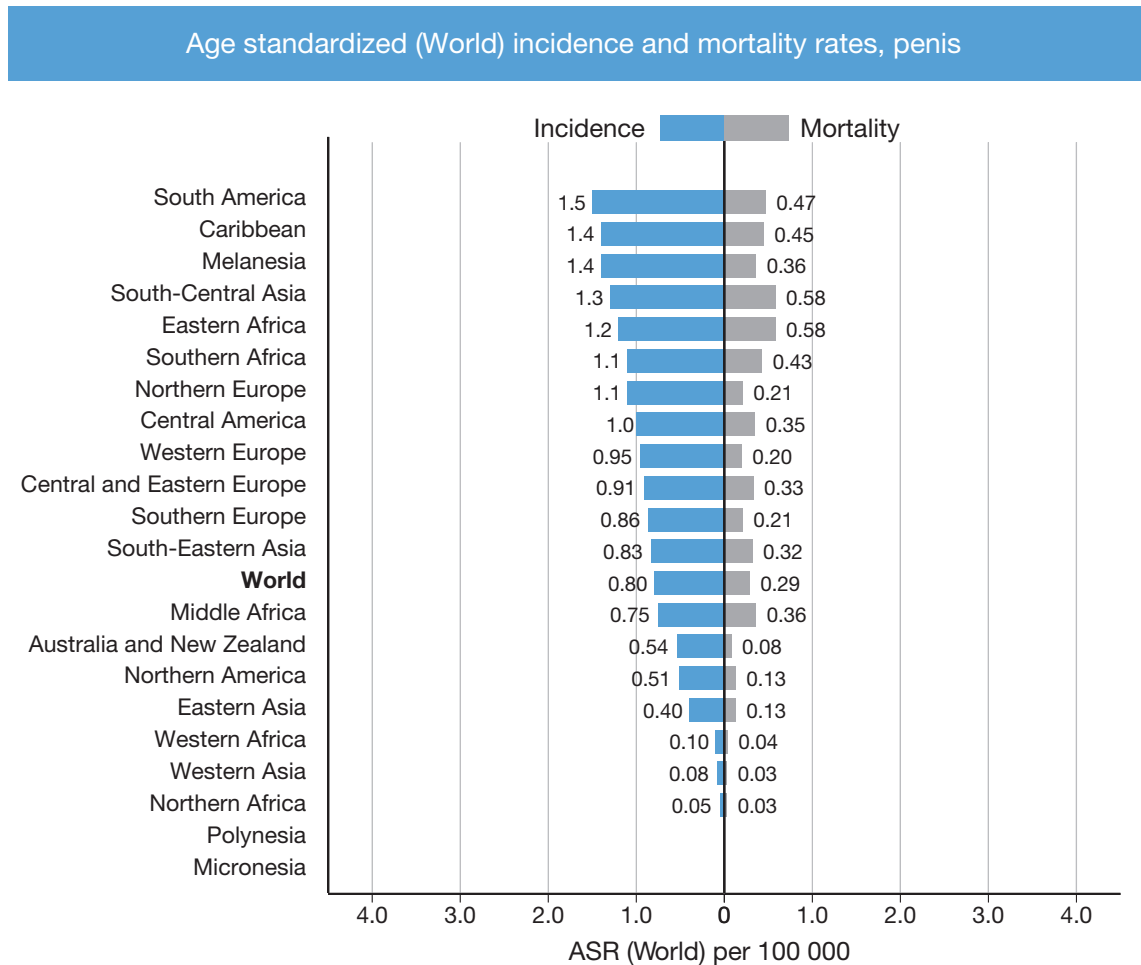
In Europe, there is considerable variation across countries. Data from Norway showed an increase in the age-standardised incidence rates in 5-year periods from 2001-2015 compared to the previous periods (0.65/100,000 in 1956–60 vs. 0.91/100,000, in 2011-2015) with an Estimated Annual Percent Change of +0.80% [14]. In the United Kingdom, the age-standardised incidence rate increased 28% between 1993 and 2018. This trend was seen in age groups from 50–79 years old. Incidence rates remained unchanged for both age extremes (< 50 and > 79 years) [15]. Based on 16 cancer registries in France, incidence rates between 2009 and 2011 were 0.59 per 100,000 men (95% CI: 0.50–0.68) and these rates have remained stable since 1989 [16].

In the USA, the incidence of penile cancer is affected by race and ethnicity, with the highest incidence in white Hispanics (1.01), followed by Alaskans and Native American Indians (0.77), African Americans (0.62) and white non-Hispanics (0.51), per 100,000 males, respectively. The overall age-adjusted incidence rate decreased between 1973 and 2002; per decade from 0.84 (1973–1982), to 0.69 (1983–1992), and 0.58 (1993–2002) per 100,000 males, respectively [17]. An increasing trend, slightly surpassing the previous incidence rates, was described using the Surveillance, Epidemiology and End Result (SEER) 2000–2016 data [18], showing an estimated annual percent change of +3.5% from 2004-2016 [19].

The incidence increases with age [15, 20], with a peak in the sixth decade but it does occur in younger men [21]. Penile cancer is common in regions with a high prevalence of human papillomavirus (HPV), and approximately one-third to half of cancer cases are attributed to HPV-associated carcinogenesis [22, 23]. There are no reports linking this cancer to human immunodeficiency virus (HIV) or acquired immune deficiency syndrome (AIDS).

In summary, it seems that a slight increase in incidence is seen in Western/developed countries, most likely caused by higher infection rates of HPV which is a trend also observed in oropharynx carcinoma [24].

Figure 3.1: Annual incidence rate (world standardised) by world area [25]



3.3 Risk factors, prognosis, and prevention

Several risk factors for penile cancer have been identified, such as phimosis, chronic penile inflammation, lichen sclerosus, smoking, ultraviolet A phototherapy, and low socio-economic status, amongst others [26].

Patient outcome is influenced by clinical and histologic features. United States SEER data from 18 cancer registries indicated an overall 5-year relative survival of 67% with no significant changes when comparing 5-year spans between 2000–2014. Patients with localised disease showed the best outcome with up to 81% 5-year relative survival. Patients with distant metastases have the worst outcomes with only 16% 5-year relative survival [27].

Human papilloma virus infection is the main risk factor for penile cancer [28]. Human papilloma virus deoxyribonucleic acid (DNA) has been identified in intraepithelial neoplasia and invasive penile cancer tissue samples. The HPV virus interacts with oncogenes and tumour suppressor genes (*p16*, *P53*, *Rb* genes) [29, 30]. The rate of HPV-positivity differs between different histological subtypes of penile SCC. Human papilloma virus is a co-factor in the carcinogenesis of some subtypes of penile SCC, while others are not related to HPV. The risk of penile cancer is increased in patients with condyloma acuminata [31]. A SR of 52 studies concluded that the overall HPV prevalence in penile cancer is 50.8% (95% CI: 44.8–56.7). Among HPV-associated carcinomas, basaloid carcinoma showed the highest prevalence (84%) followed by warty-basaloid carcinoma (75.7%) and warty carcinomas (58.7%). In histologically HPV-independent carcinomas, HPV prevalence was 19.4%. The most frequent HPV genotypes were HPV16 (68.3%, 95% CI: 58.9–77.1), followed by the low-risk HPV6 genotype (8.1%, 95% CI: 4.0–13.7) [23].

In early studies, HPV has shown an inconsistent association with prognosis. In one study, a significantly better 5-year disease-specific survival (DSS) was reported for HPV-positive vs. HPV-negative cases (93% vs. 78%) [32], while no difference in lymph node (LN) metastases and 10-year survival was reported in another study [33]. This variable relationship with outcome remains unexplained but some studies suggested that it can be related to specific treatment [34] and linked to different histologic subtypes [35]. A meta-analysis published in 2018 [36] reported a pooled HR of 0.61 for penile cancer HPV-positive cases, which is in line with head, neck [37]

and anal cancers [38], with a HR of 0.34 and 0.54, respectively. Positivity for p16 immunohistochemistry (IHC), a surrogate for HPV activity, showed a prognostic value for DSS (hazard ratio [HR]: 0.45) based on two meta-analyses [36, 39]. Similar trends were reported in vulvar and anal cancers [38, 40].

There is no significant association between the incidence of penile and cervical cancer, although half of penile cancer and virtually all cervical cancer cases are linked to HPV [41]. Female sexual partners of patients with penile cancer have not been found to have an increased incidence of cervical cancer [42].

At present, except in a limited number of countries, there is no general recommendation for HPV vaccination in males because of the different HPV-associated risk patterns in penile- and cervical cancer. A meta-analysis showed that the incidence of anal (risk ratio [RR]: 0.42), oral (RR: 0.16), and cervical HPV infections (RR: 0.22) were reduced in vaccinated groups when compared against control groups, indicating that HPV vaccination leads to the prevention of HPV infection [43]. Human papilloma virus vaccination in males showed more than 50% efficacy against anal intraepithelial lesions but no meaningful estimates were obtained for penile, anal, and head and neck invasive carcinomas [44]. Since up to 50% of invasive penile carcinomas and 80% of pre-neoplastic lesions are HPV-associated, HPV vaccination is encouraged [45].

Phimosis is strongly associated with invasive penile cancer [46-49], due to associated chronic infections. However, smegma is not a carcinogen [48]. The incidence of lichen sclerosus is relatively high in penile cancer patients but is not associated with adverse histopathological features, including penile intraepithelial neoplasia (PeIN). Other epidemiological risk factors are cigarette smoking, low socio-economic status, and a low level of education [47, 49].

Neonatal circumcision reduces the incidence of penile cancer; however, it does not seem to reduce the risk of PeIN [46]. The lowest incidence of penile cancer is reported in Israeli Jews (0.3/100,000/year). One matched-pair case-control study reported that the protective effect of neonatal circumcision against invasive penile cancer (OR: 0.41) was much weaker when the analysis was restricted to men without a history of phimosis (OR: 0.79, 95% CI: 0.29–2) [46].

3.4 Pathology

Squamous cell carcinoma accounts for over 95% of penile malignancies. It is not known how often SCC is preceded by premalignant lesions [50-53]. Penile intraepithelial neoplasia is considered the precursor lesion of penile SCC, PeINs are classified into HPV-independent, known as differentiated PeIN, HPV-associated, following the same scheme as the invasive counterparts (see Table 3.2). Clinical terms such as ‘Erythroplasia of Queyrat, Bowenoid papulosis and Bowen’s disease’ are discouraged, based on the 2022 WHO classification [8, 54].

Different histological types of penile SCC with different growth patterns, clinical aggressiveness and HPV associations have been identified (see Table 3.1). Numerous mixed forms exist such as the warty-basaloid form, with 50–60% the most common mixed form, the usual- verrucous (hybrid), usual-warty, usual-basaloid and the usual-papillary, as well as other rarer combinations.

Other malignant lesions of the penis, all much less common than penile SCC, are melanocytic lesions, mesenchymal tumours, lymphomas, and metastases. Penile metastases are frequently of prostatic, urinary bladder or colorectal origin [55]. Different types of penile sarcoma have been reported [8].

Table 3.2: Classification of penile intra-epithelial neoplasia [8]

• HPV-independent
o Differentiated PeIN
• HPV-associated PeIN
o Common patterns: basaloid (undifferentiated), warty (condylomatous), and mixed
o Other (less frequent) patterns: pagetoid, clear cell, and spindle cell histology

3.4.1 Gross handling of pathology specimens

Tissue sections determine the accuracy of histological diagnosis. Small lesions should be fully included, bigger lesions should have at least 3-4 blocks of tumour with the anatomical landmarks. Specimens should be properly oriented by the surgeons and, in case of circumcision or glans resurfacing, properly pinned to allow clear evaluation of the resection margins. Penectomy specimens must be canalised through the urethra and cut longitudinally in two halves for the evaluation of invasion of the penile structures. In larger tumours identification of distal urethra on gross (as also microscopy) may be difficult. Whole-mount inclusion and sections are recommended as they provide a better background for the appropriate identification of anatomical structures that can improve accurate staging, with a minimal increase in cost [56]. Sentinel LN should be evaluated according to a standardised IHC protocol [57] for detection of micro-metastases; lymphadenectomy/

lymph node dissection (LND) specimens should be inked, and the LNs evaluated properly since extra-capsular extension profoundly influences nodal staging and treatment decisions. Second-opinion pathology review is highly desirable for this rare tumour entity [58], as is setting up comprehensive referral centres for penile cancer management on a national level [58, 59].

3.4.2 Pathology report

For standardisation and data collection purposes the dataset template from the International Collaboration on Cancer Reporting (ICCR) should be used when possible. The pathology report must include the anatomical site of the primary tumour, the histological type of SCC, grade, perineural invasion, depth of invasion, vascular invasion (venous/lymphatic), pattern of invasion, urethral invasion, invasion of corpus spongiosum/corpora cavernosum, surgical margins and p16 IHC results [60-63] (Table 3.3). The confirmation of the presence of HPV in the specimen (e.g., polymerase chain reaction [PCR], *in-situ* hybridization [ISH] for viral DNA/ribonucleic acid [RNA]) is desirable but currently only carried out in research settings.

Table 3.3: Information to include in pathology reports for penile carcinomas

Type of information*	Recommended	required
Clinical information • Prior treatments (topic, radiotherapy, chemotherapy)	x	
Surgical procedure		x
Tumour localisation • Anatomic structures involved externally (e.g.: foreskin, glans, etc.) and in depth (e.g.: dartos, corpus spongiosum, etc.)		x
Macroscopic tumour dimension • Size of tumour • Maximum thickness		x
Photographic documentation	x	
Block identification with description of the localization of the samples		x
Histological tumour type		x
Histological grade		x
Microscopic maximum dimensions • Depth of invasion (i.e., millimetres from basement membrane to deepest point of invasion) • Combination of gross and microscopic if large tumours		x
Extent of invasion (microscopic confirmation of all the involved anatomic structures)		x
Tumour invasion front (Broadly-based pushing, destructive but well-delineated, destructive irregular/finger-like invasion/tumour budding) [64-66]	x	
Lymphovascular invasion [67, 68]		x
Perineural invasion		x
Margin status in mm (margins as per specimen)		x
Lymph node status • Size of largest nodal tumour deposit (not LN size) Total number of LNs, number of positive LNs, extra-capsular spread (ECS), inguinal or pelvic, to be reported in every site separately		x
pTNM Stage		x
HPV assessment (at least p16 IHC based)		x

* See also ICCR dataset: <https://www.iccr-cancer.org/datasets/published-datasets/urinary-male-genital/penis/>.

3.4.3 Grading

The tumour, node, metastasis (TNM) classification for penile cancer includes tumour grade based on its prognostic relevance. Tumour grading in penile cancer has been shown to be highly observer-dependent and can be problematic, especially in large tumours which may be heterogeneous. This may have implications on the clinical management, as there may be discordance between biopsy and resection grading [50]. Inter-observer agreement varies according to the experience and specialisation of the pathologist. In general, inter-observer

agreement is poor to moderate (Fleiss' kappa 0.07–0.55) [69]. Nevertheless, until a new methodology to grade penile SCC is developed, grading based on the WHO/The International Society of Urological Pathology (ISUP) classification is recommended (see Table 3.4) with grade 3 and sarcomatoid being considered as poorly differentiated.

Table 3.4: Grading recommendations for penile SCC

Feature	Grade 1	Grade 2	Grade 3	Sarcomatoid
Cytological atypia	Mild	Moderate	Anaplasia	Sarcomatoid
Keratinisation	Usually abundant	Less prominent	May be present	Absent
Intercellular bridges	Prominent	Occasional	Few	Absent
Mitotic activity	Rare	Increased	Abundant	Abundant
Tumour margin	Pushing/well	Infiltrative/ill defined	Infiltrative/ill defined	Infiltrative/ill defined

3.4.4 **Pathological prognostic factors**

Pathological subtype, peri-neural invasion, lymphovascular invasion [67], depth of invasion and grade in the primary tumour are strong predictors of poor prognosis and high cancer-specific mortality [70]. Higher grade and lymphovascular invasion are predictors of metastatic spread. Lymphovascular space involvement/invasion is often seen in advanced stages but may also be seen in early invasive tumours of high grade and some histologic subtypes [71, 72]. The extent of LN metastasis and extracapsular spread are also strong predictors of prognosis.

Urethral invasion is not considered a prognostic factor (UICC, 8th Edn) [73]. Nevertheless, invasion of the more proximal urethra can signify a highly aggressive SCC with a poor prognosis probably due the invasion of subjacent erectile corpora (see Table 4.1). A SR found that invasion of the corpus spongiosum (pT2) showed better cancer-specific survival (CSS), but no overall survival (OS) benefit compared to invasion of the corpora cavernosa [74]. A modified pT2/T3 has been proposed, taking into consideration high-grade, lymphovascular- and perineural invasion features in response to this inconsistency [75]. Extra-capsular extension in even one single LN carries a poor prognosis and is denoted as pN3 [76-78].

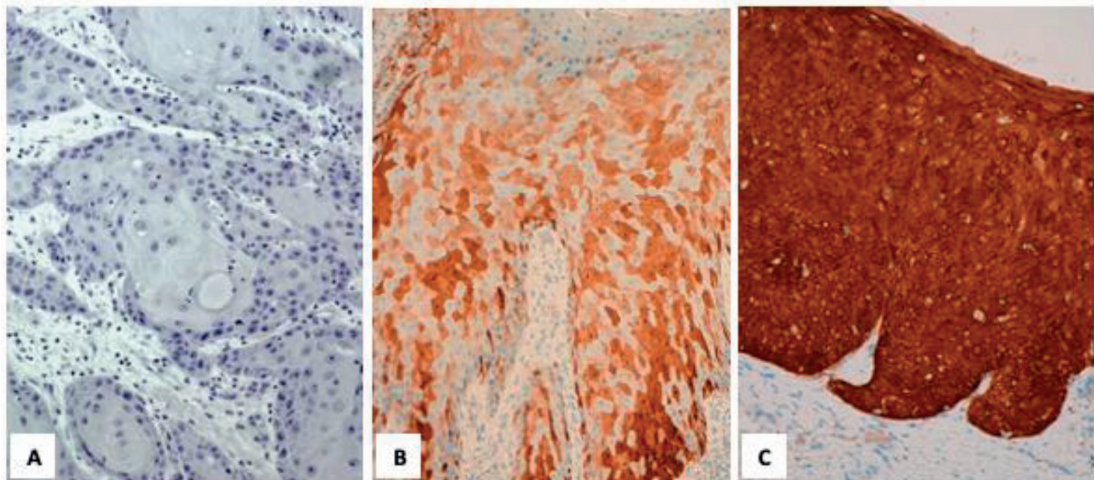
Chaux *et al.*, suggested a prognostic index which incorporates grade, anatomical level of infiltration and perineural invasion to predict the likelihood of inguinal LN metastases and 5-year survival [79]. Sali *et al.*, proposed a histopathological risk scoring incorporating grade, anatomical level of involvement and replaced perineural invasion with pattern of infiltration [66]. Other clinical-, pathological- and radiological scores, as well as nomograms have been described but none of these have been comparatively validated which precludes making a recommendation.

3.4.5 **Penile cancer and HPV**

In the 2022 WHO classification the presence of HPV is a key determinant for the broad classification of penile SCC [8]. However, in most clinical settings, standard molecular assessment of HPV status is not available.

p16 IHC is used as a surrogate for high-risk HPV genotype presence and marker of oncogenic activity. In the absence of more advanced techniques, it is helpful in assigning penile SCC to HPV-associated subtypes. The p16 IHC overall positivity in penile cancer was 41.6% [23]. Higher positivity was seen in morphological HPV-associated SCCs (85.8%) as compared with HPV-independent SCCs (17.1%)[23]. Comparing with RNA ISH, p16 IHC showed a sensitivity of 100% and a specificity of 71%, the latter improved to 89% when considering a high intensity for p16 IHC positivity [80]. These data indicate that sensitivity, specificity, and predictive values for HPV positivity can be improved using the stringent p16 IHC cut-off suggested by Cubilla *et al.* [81] (Figure 3.2). The ISUP reported that 80% of their respondents during a consultation conference on molecular pathology of urogenital cancers used p16 IHC to separate HPV-associated from HPV-independent PeIN and SCCs and made recommendations on the use of p16 IHC [82].

Fig 3.2: Patterns of p16 expression. (A) no staining; (B) mosaic staining pattern; (C) en-bloc staining pattern. Only (C) is considered positive for p16.



3.4.6 **Penile biopsy: pathological and technical considerations**

The quality of biopsy is important [50]. In most cases, acquiring a punch biopsy (e.g., 2–3 mm) under local anaesthesia is sufficient to confirm the diagnosis. In biopsies with an average size of 1 mm, it was difficult to evaluate the depth of invasion in 91% of cases [50]. Furthermore, vascular and lymphatic tumour emboli were detected in only 9–11% of cases [50]. Therefore, in cases where assessment of depth of invasion is necessary, an incisional biopsy which is deep enough to properly assess the degree of invasion and stage is preferable.

3.4.7 **Summary of evidence and guidelines for the pathological assessment of tumour specimens**

Summary of evidence	LE
Incidence of penile cancer varies according to geographical location, race and ethnicity.	2a
Western developed countries have seen a slight increase in incidence, which may be caused by higher HPV infection rates.	2a
In analogy to other HPV-associated cancers, HPV status may influence DSS of penile cancer, but more data is needed, underlining the importance of routine assessment of HPV status in all penile cancer patients.	2b

Recommendations	Strength rating
The pathological evaluation of penile carcinoma specimens must include the pTNM (see Chapter 4) stage and an assessment of tumour grade.	Strong
The pathological evaluation of penile carcinoma specimens must include an assessment of p16 by immunohistochemistry.	Strong
The pathological evaluation of penile carcinoma specimens should follow the ICCR dataset synoptic report.	Strong

ICCR = International Collaboration on Cancer Reporting.

4. CLASSIFICATION SYSTEMS

4.1 **TNM classification**

The 8th edition of the UICC/AJCC TNM is the currently used classification system for penile cancer which was last updated in 2017 [73, 83]. Compared to the previous (7th) edition, some changes were introduced. The T1 category is stratified into two different risk groups depending on the absence or presence of lymphovascular invasion, perineural invasion, or poor differentiation (T1a vs. T1b, respectively, see Table 4.1) [84]. Furthermore, invasion into the urethra was previously classified as T3 disease. However, a tumour near the meatus

may directly invade into the distal urethra through the corpus spongiosum, which is not associated with worse outcome. In addition, previous studies have shown that corpus spongiosum invasion is associated with a lower incidence of inguinal LN metastasis and has better survival compared to corpus cavernosum invasion. Therefore, invasion into the corpus spongiosum and corpus cavernosum is classified into T2 and T3, respectively [85, 86]. Patients with T4 tumours have extension into adjacent tissues (e.g., prepubic fat, scrotum, spermatic cord, pubic bone, prostate).

The pN1 category was modified to include up to two unilateral inguinal LN metastases, while the pN2 category was modified to be three or more unilateral, or any bilateral LN metastases. This was based on data showing poor outcomes in cases involving three or more unilateral or bilateral LNs compared with those involving one or two unilateral LNs [86, 87]. pN3 stage is defined as pelvic nodes (uni- or bilateral) or presence of extranodal extension (ENE) (inguinal or pelvic, regardless of the number of LN metastases) [73, 83]. Further retroperitoneal LN spread cranial to the pelvic template is classified as extra-regional and therefore as distant metastases.

Table 4.1: UICC/AJCC 8th edition TNM clinical and pathological classification of penile cancer [73, 83]

Clinical classification	
T - Primary Tumour	
TX	Primary tumour cannot be assessed
T0	No evidence of primary tumour
Tis	Carcinoma <i>in situ</i> (Penile Intraepithelial Neoplasia – PeIN)
Ta	Non-invasive verrucous carcinoma*
T1	Tumour invades subepithelial connective tissue
T1a	Tumour invades subepithelial connective tissue without lymphovascular invasion or perineural invasion and is not poorly differentiated
T1b	Tumour invades subepithelial connective tissue with lymphovascular invasion or perineural invasion or is poorly differentiated
T2	Tumour invades corpus spongiosum with or without invasion of the urethra
T3	Tumour invades corpus cavernosum with or without invasion of the urethra
T4	Tumour invades other adjacent structures
N - Regional Lymph Nodes	
cNX	Regional lymph nodes cannot be assessed
cN0	No palpable or visibly enlarged inguinal lymph nodes
cN1	Palpable mobile unilateral inguinal lymph node
cN2	Palpable mobile multiple or bilateral inguinal lymph nodes
cN3	Fixed inguinal nodal mass or pelvic lymphadenopathy, unilateral or bilateral
M - Distant Metastasis	
cM0	No distant metastasis
cM1	Distant metastasis
Pathological classification	
The pT categories correspond to the clinical T categories.	
The pN categories are based upon biopsy or surgical excision	
pN - Regional Lymph Nodes	
pNX	Regional lymph nodes cannot be assessed
pN0	No regional lymph node metastasis
pN1	Metastasis in one or two inguinal lymph nodes
pN2	Metastasis in more than two unilateral inguinal nodes or bilateral inguinal lymph nodes
pN3	Metastasis in pelvic lymph node(s), unilateral or bilateral or extranodal extension of regional lymph node metastasis
pM - Distant Metastasis	
pM1	Distant metastasis microscopically confirmed

G - Histopathological Grading	
GX	Grade of differentiation cannot be assessed
G1	Well differentiated
G2	Moderately differentiated
G3	Poorly differentiated
G4	Undifferentiated

**Including verrucous carcinoma.*

4.2 Cancer stage grouping

In the UICC TNM 8th edition, stage II was newly subdivided into Stage IIA and Stage IIB based on T categories. Stage IIA is defined as T1b–2N0M0, while Stage IIB is defined as T3N0M0 [73] (Table 4.2).

Table 4.2 UICC TNM Stage/Prognostic Groups [73]

Stage	T	N	M
0	Tis	N0	M0
	Ta	N0	M0
I	T1a	N0	M0
IIA	T1b	N0	M0
	T2	N0	M0
IIB	T3	N0	M0
IIIA	T1–3	N1	M0
IIIB	T1–3	N2	M0
IV	T4	Any N	M0
	Any T	N3	M0
	Any T	Any N	M1

5. DIAGNOSTIC EVALUATION AND STAGING

5.1 Primary lesion

5.1.1 Physical examination

Primary penile carcinoma are usually clinically evident lesions often presenting as raised or ulcerous lesions which can be locally destructive [88]. It is critically important to note that the appearance of penile tumours can be heterogeneous and can sometimes be hidden under the foreskin in case of phimosis. Physical examination should include inspection and palpation of the entire penis (to identify potential skip lesions). The dimensions, anatomic location, and extent of local invasion should be noted, and assessment of stretched penile length is recommended.

5.1.2 Imaging of the primary tumour

Physical examination is a reliable method for estimating penile tumour size and clinical T stage [89]. For distinguishing T1 from T2 disease, magnetic resonance imaging (MRI) does not outperform physical examination. However, when there is uncertainty if the tumour invades the cavernosal bodies (cT3), and if organ-sparing treatment options (e.g., glansectomy) are considered, MRI can be helpful [90, 91]. A SR showed a sensitivity and specificity of MRI in predicting corporal invasion of 80% (95% CI: 70–87%) and 96% (95% CI: 85–99%), respectively [92, 93]. Magnetic resonance imaging can also provide useful information regarding resectability in case of large (T4) tumours with invasion in adjacent structures. Magnetic resonance imaging with and without artificial erection showed similar accuracy in local staging [93]. If MRI is not available, penile ultrasound (US) can be considered [94].

5.1.3 Penile biopsy: indications

A biopsy of the penile tumour should be obtained when there is doubt about the exact nature of the lesion. However, even in clinically obvious cases, histological information from a biopsy can facilitate treatment decisions (such as

indications for surgical staging). Histological confirmation is also necessary to guide management when treatment is planned with topical agents, radiotherapy or laser surgery [88]. For technical and histopathological considerations for penile biopsy see Section 3.4.6.

5.2 Lymph node staging

Penile cancer metastasizes in a stepwise manner through the lymphatic system, initially to the inguinal nodes, then the pelvic nodes and finally to distant nodes [95]. Fewer than 5% of patients will present with distant metastases and these are generally accompanied by regional LN involvement. As a result, the most important prognostic factor for survival of penile cancer is the presence and extent of nodal metastases, with a 5-year CSS of approximately 95%, 80%, 65% and 35% for N0, N1, N2 or N3 disease, respectively [96, 97].

In patients with clinically node-negative groins (no suspicious palpable nodes, cN0), a non-randomised controlled trial (RCT) observed that early LN surgery led to a 3-year survival rate of 84% compared to 35% in those receiving delayed LN surgery, with an ENE incidence of 20% compared to 95% in the early vs. delayed surgery groups, respectively [98]. Therefore, detecting lymphatic spread as early as possible is a crucial element in penile cancer management. Since penile cancer disseminates to the inguinal LNs first, initial LN staging is focused on identifying (micro)metastatic disease in the inguinal LNs as early as possible, and imaging for distant metastases is only indicated in clinically node-positive patients.

5.2.1 Physical examination

Careful palpation of both groins for enlarged/pathologic inguinal LNs must be part of the initial physical examination of patients suspected of having penile cancer. However, reliable physical examination can be challenging in case of obesity and in patients with previous inguinal surgery. Also, enlarged LNs secondary to infection of the primary tumour (rather than metastasis) can occur. The use of antibiotics with the aim to resolve enlarged nodes may delay further staging and treatment and is not recommended [99]. Based on physical examination, patients can be divided into those without suspicious nodes at physical examination (clinically node-negative, cN0), and those with suspicious palpable nodes (clinically node-positive, cN+). In case of suspected pathologic LNs at palpation; the number, location, size and whether the node is fixed or mobile, should be noted.

5.2.2 Clinically node-negative patients (cN0)

If no suspicious nodes are present at palpation (cN0), approximately 20-25% of patients may still harbour occult metastases, so additional staging is warranted [100].

5.2.2.1 Non-surgical staging options

Unfortunately, there are no validated nomograms or tumour markers that can reliably predict LN involvement. Conventional imaging modalities such as US, computed tomography (CT) or MRI cannot detect micro-metastases, and ¹⁸F-fluoro-2-deoxy-D-glucose positron emission tomography (¹⁸FDG-PET) does not detect LN metastases < 10 mm [101-103]. Therefore, these imaging modalities are of limited value and are not recommended for routine use in clinically node-negative patients in which the aim is to identify small, sub-clinical, LN metastasis [104, 105]. However, these imaging modalities can be of value to detect enlarged/abnormal nodes in patients when physical examination is challenging (e.g., due to obesity).

In centres that offer dynamic sentinel node biopsy (DSNB) as a surgical staging option (see Section 5.2.2.3.), inguinal US is obtained prior to DSNB. If sonographically suspicious nodes are detected, fine needle aspiration cytology (FNAC) can easily be performed in the same session to confirm the diagnosis of inguinal LN metastasis [106]. Studies incorporating US + FNAC as an initial investigation in clinically node-negative patients prior to surgical staging, reported a sensitivity and specificity of 39% and 100%, respectively. Hence, a negative US is unreliable to exclude LN metastasis in clinically node-negative patients and US should be combined with surgical staging when indicated. However, if US + FNAC is positive, it can reduce the need for DSNB by 10–13%, allowing for additional staging and therapeutic LN dissection at an earlier stage [107, 108]. Therefore, it is recommended to perform US + FNAC in clinically node-negative patients, before surgical staging with DSNB.

5.2.2.2 Indications for surgical staging

Since delayed treatment of occult LN metastasis results in a lower CSS rate and current non-invasive staging options (nomograms, imaging) are not reliable enough to detect micrometastatic disease, invasive/surgical staging remains indispensable to identify micro-metastasis before nodal metastases become palpable/visible [98]. However, surgical staging is over-treatment in the majority of patients since only 20–25% of all clinically node-negative patients harbour occult metastasis.

To select patients that are especially at risk of nodal metastases, risk categories have been established based on T stage, grade of differentiation, and the presence of lymphovascular/perineural invasion in the primary tumour. Well-differentiated (G1), pTa, pTis and pT1 tumours without lymphovascular/perineural invasion (pT1a) are considered low-risk tumours. In patients with low-risk tumours, the risk of metastases is too low to justify surgical staging. Moderately differentiated (G2) pT1a tumours are considered intermediate-risk and are associated with a 6–8% probability of (micro-)metastatic LN disease, whereas in pT1b G2 tumours, the risk is 22–30%. Therefore, all tumours that are stage T1b, or higher, are considered high-risk tumours [72, 109].

Based on these predictors, surgical staging is recommended in all high-risk tumours (T1 with presence of lympho-vascular invasion, peri-neural invasion or poorly differentiated, and T2–T4 with any grade). In intermediate-risk tumours (pT1a G2), the risk of LN metastasis should be balanced against the morbidity of surgical staging on a case-by-case basis.

5.2.2.3 *Surgical staging options*

By definition, radical inguinal lymph node dissection (ILND) is the most accurate surgical staging method. However, ILND is also associated with the highest complication rates (see Section 6.2 - LN management). To lower morbidity while maintaining sufficient sensitivity, modified ILND templates were developed (consisting of a shorter skin incision; no dissection lateral to the femoral artery or caudal to the fossa ovalis, and preservation of the saphenous vein) [110]. However, modified ILND is still associated with considerable complication rates of 35–49% and false-negative rates of 15–20% [111, 112]. More recently, video-endoscopic/robot-assisted radical LND was introduced (see Section 6.2 - LN management). Initial reports indicate a reduction mainly in wound-related complications compared to open ILND [113]. However, a significant reduction of lymphatic complications is not to be expected since the main predictor of lymphatic complications was shown to be the number of removed LNs [114–116], and the LN yield of the video-endoscopic approach is comparable to open ILND [117].

To avoid resecting unnecessary LNs and thereby minimising the morbidity of surgical staging, DSNB was developed [118]. A sentinel node (SN) is defined as the first LN on a direct drainage pathway from the primary tumour. Based on this concept, it is assumed that if the SN is negative, this indicates the absence of lymphatic tumour spread in the corresponding inguinal basin. In case histopathology identifies SN (micro)metastasis, ipsilateral completion ILND is indicated (see Section 6.2.2) [119]. Dynamic SN biopsy is typically performed using a combination of a radioactive tracer and patent blue dye in order to achieve optimal visualization of the lymphatic drainage system prior and during surgery. Recent innovations include the incorporation of single-photon emission computed tomography/CT (SPECT/CT) and hybrid radioactive and fluorescent tracers [120]. Throughout the years, the procedure has matured into a reliable staging technique with high diagnostic accuracy and low complication rates, especially when performed in experienced centres (sensitivity 92–96%, false-negative rates 4–8%, complication rate 6–14%) [108, 114, 121]. A recent meta-analysis reported a higher pooled false-negative rate of 12% and showed that the false-negative rate was lower in high-volume centres [122]. This might indicate a potential learning curve and supports the call for centralisation of penile cancer care.

If DSNB is not available, and referral to a centre with experience with DSNB is not feasible, or if the patient does not want to run the risk of a false-negative procedure, ILND (modified/superficial/video-endoscopic) can be considered after informing the patient of the inherent risk of higher morbidity associated with these procedures.

5.2.3 **Clinically node-positive patients (cN+)**

In patients with palpable nodes, nodal metastases are present in approximately 45–80% of cases [123]. Lymph node metastasis should preferably be histopathologically confirmed by image-guided biopsy (e.g., US or CT). While in cN0 patients further abdominal and thoracic imaging is not recommended (See Section 5.2.2.1), it is of value in cN+ patients to clinically stage the pelvis and exclude distant metastases. Computed tomography of the chest/abdomen is broadly available, however CT has a sensitivity of only 20–38% for the detection of pelvic LNs. Magnetic resonance imaging constitutes another diagnostic staging modality; in particular in those patients with a contra-indication to iodine-based contrast agents who cannot be staged by CT. A meta-analysis comparing CT and MRI showed comparable results with a pooled sensitivity of 42% for CT and 39% for MRI and pooled specificity was 82% for both [124]. Imaging with ¹⁸FDG-PET/CT is likely to be more accurate than CT alone in the pre-operative staging of pelvic LNs, as shown in other malignancies [125]. In penile cancer, ¹⁸FDG-PET/CT showed a sensitivity and specificity of 91% and specificity of 100%, respectively, for the detection of pelvic metastases in patients with an US + FNAC-confirmed positive inguinal LN [126]. In patients initially staged as cN0 and who are subsequently upstaged to pN+ at surgical staging, additional imaging of the chest/abdomen should also be considered. Treatment of node-positive disease is further discussed in Section 6.2.

5.3 Summary of evidence and guidelines for the diagnosis and staging of penile cancer

Summary of evidence	LE
For distinguishing T1 from T2 disease, MRI does not outperform clinical staging.	2b
For predicting corporal invasion (T3 disease), MRI showed a pooled sensitivity and of 80% (95% CI: 70–87%) and 96% (95% CI: 85–99%), respectively.	2b
Magnetic resonance imaging with and without artificial erection showed similar accuracy in local staging.	2b
Computed Tomography, PET/CT and MRI imaging cannot detect micro-metastases and are therefore of limited value in clinically node-negative patients in which the aim is to identify small sub-clinical LN metastasis.	2a
Inguinal US + FNAC of sonographically abnormal nodes can reduce the need of DSNB when tumour positive, allowing for earlier therapeutic treatment of node-positive disease.	2a
For surgical staging of cN0 patients, DSNB has shown a high diagnostic accuracy.	2a
Sentinel node biopsy has been shown to lower complication rates compared to modified-, superficial-, or video-endoscopic inguinal LND.	2b
Imaging with ¹⁸ FDG-PET/CT in clinically node-positive patients showed higher sensitivity/specificity than CT alone in the pre-operative staging of the pelvic LNs and distant metastasis.	2b

Recommendations	Strength rating
Primary tumour	
Perform a detailed physical examination of the penis and external genitalia, recording morphology, size and location of the penile lesion, including extent and invasion of penile (adjacent) structures.	Strong
Perform magnetic resonance imaging (MRI) of the penis/primary tumour (artificial erection not mandatory) when there is uncertainty regarding corporal invasion and/or the feasibility of (organ-sparing) surgery. If MRI is not available, offer ultrasound (US) as alternative option.	Weak
Obtain a pre-treatment biopsy of the primary lesion when malignancy is not clinically obvious, or when non-surgical treatment of the primary lesion is planned (e.g., topical agents, laser, radiotherapy).	Strong
Inguinal lymph nodes (LN)	
Perform a physical examination of both groins. Record the number, laterality and characteristics of any palpable/suspicious inguinal nodes.	Strong
Clinically node-negative (cN0)	
If there are no palpable/suspicious nodes (cN0) at physical examination, offer surgical LN staging to all patients at high risk of having micro-metastatic disease (T1b or higher).	Strong
In case of T1a G2 disease, also discuss surveillance as an alternative to surgical staging with patients willing to comply with strict follow-up.	Weak
When surgical staging is indicated, offer dynamic sentinel node biopsy (DSNB). If DSNB is not available and referral is not feasible, or if preferred by the patient after being well informed, offer inguinal lymph node dissection (ILND) (open or video-endoscopic).	Strong
If DSNB is planned, perform inguinal US first, with fine needle aspiration cytology (FNAC) of sonographically abnormal LNs.	Strong
Clinically node-positive (cN+)	
If there is a palpable/suspicious node at physical examination (cN+), obtain (image-guided) biopsy to confirm nodal metastasis before initiating treatment.	Strong
In cN+ patients, stage the pelvis and exclude distant metastases with ¹⁸ F-fluoro-2-deoxy-D-glucose positron emission tomography (¹⁸ FDG-PET) computed tomography (CT) or CT of the chest and abdomen before initiating treatment.	Strong

6. DISEASE MANAGEMENT

6.1 Treatment of the primary tumour

Besides its role in sexual functioning and urination, a fully functional penis is central to a patient's sense of wholeness, desirability and masculinity. Hence, the aims of the treatment of the primary tumour are complete tumour removal with as much organ preservation as possible, without compromising oncological control.

There are no RCTs or observational comparative studies for any of the treatment options for localised penile cancer. Penile preservation appears to be superior in functional and cosmetic outcomes as compared to partial or total penectomy and is considered to be the primary treatment method for localised penile cancer, based on retrospective studies.

Histological diagnosis and local staging must be obtained before non-surgical treatments can be considered. For small tumours, excisional biopsy can equal treatment, while for larger lesions which necessitate more complex or mutilating surgery, an incisional biopsy is advised (see Section 3.4.6). Histology provides confirmation of the diagnosis before treatment and informs on the risk group of the primary tumour which has important consequences for invasive staging of the groins. With surgical treatment, negative surgical margins for invasive carcinoma must be obtained. Treatment of the primary tumour and of the regional nodes can either be simultaneous or staged.

Local treatment modalities for small and localised penile cancer include topical therapy, laser ablation, excisional surgery, external beam radiotherapy (EBRT) and brachytherapy. Unfortunately, the SR of the Guidelines Panel revealed a complete absence of both RCTs and prospective trials assessing and comparing the effectiveness of interventions for managing the primary tumour [3]. Treatment recommendations can therefore only be based on retrospective data and expert opinion. In the absence of comparative evidence supporting treatment modalities, patients should be informed about all appropriate treatment options for their specific tumour and situation, and the potential advantages and disadvantages for each technique which are discussed per disease stage in the following sections.

6.1.1 Treatment of superficial non-invasive disease (PeIN, Ta)

Penile intra-epithelial neoplasia can progress to invasive lesions in 2.6–13% of patients, despite treatment; hence, definitive eradication and diligent follow-up monitoring are important [127-129]. Most PeIN lesions are located on the mucosal surfaces of the glans or prepuce whilst lichen sclerosus also affects the prepuce [128]. Thus, circumcision should be the primary surgical option [129]. Following circumcision, the glans mucosa keratinizes over a period of 3–6 months and any residual PeIN or lichen sclerosus may resolve. Close monitoring before starting additional therapy has been advocated, but to date, data supporting this concept are limited [129]. Considering a median time to progression to malignancy of thirteen months [128], this approach seems reasonable to test in future clinical trials.

6.1.1.1 Topical therapies

Topical therapy with imiquimod (IQ) or 5-fluorouracil (5-FU) are effective non-invasive first-line treatment options which use is increasingly reported [130]. 5-Fluorouracil exerts its effects through inhibition of the enzyme thymidylate synthase. Although no standard protocol exists, leaving the 5-FU ointment on for 12 hours every 48 hours during a 4 to 6-week treatment course is often recommended in reported series of PeIN therapy [131]. Imiquimod acts through several pathways including activation of immune cells via toll-like receptor 7, creating an inflammatory response, and is commonly used 3 times per week for 12 weeks. There is no consensus or comparative data on the optimal treatment schedules for these therapies and the evidence for these treatments is heterogenous as it only relies on retrospective studies. A SR based on the aforementioned low-quality data illustrated that topical agents showed response- and recurrence rates of 40–100% and 20% for IQ, vs. 48–74% and 11% for 5-FU, respectively [132]. Because use of 5-FU typically results in marked erythema, erosions, and crust lasting for a month or longer, decreased patient compliance with treatment regimens may result in diminished effectiveness. Similarly, IQ use is complicated by the resultant tissue effects, including erythema, oedema and erosions, ulceration and crust, that are not consistent from one individual to the next [133]. Discontinuation of topical agents because of side effects was observed in 12% of cases [132]. It is advised that treatment effects must be clinically assessed and in cases of doubt evaluated by biopsy and long-term surveillance is warranted. Insufficient responses and recurrences may signify underlying invasive disease, hence, if topical treatment fails, it should not be repeated.

6.1.1.2 Laser ablation

Laser ablation is an alternative treatment option. Energy-based therapies discussed in the literature include Neodymium:Yttrium-Aluminium-Garnet (Nd:YAG, penetration 4–6 mm, wavelength 1064 nm) or Carbon dioxide (CO₂, penetration < 1 mm, wavelength 10600 nm) lasers and photodynamic therapy [134]. Laser treatment

has shown total response rates of 52–100% with recurrence reported in 7–48% of patients [132]. Altered penile sensitivity following laser treatment has been described, including increased sensitivity in 50% and decreased sensitivity in 15% of patients. Reports show relatively high rates of local recurrence, possibly owing to inadequate penetration, difficulties in assessing borders of affected areas and missing lesions that have invaded the subepithelial tissue [10, 135, 136]. Repeat laser treatment for recurrence has been described in some series without compromising long-term oncological outcomes, which is likely a result of the low risk of the lesions treated in those series [137, 138]. For cryotherapy, with or without topical therapy, and photodynamic therapy, which induces photo-selective cell death, there are only limited data for the treatment of PeIN.

6.1.1.3 *Surgery*

Extensive PeIN, residual PeIN in resection margins or recurrent disease after ablative or topical therapy, can be treated by surgical excision. Glans resurfacing consists of full thickness removal of the glandular epithelium followed by reconstruction with a graft (split skin [139] or buccal mucosa for urethral reconstruction [140]). Grafts tend to have excellent engraftment rates on this well-vascularized wound bed [141]. Recurrences are reported to be low (0–20%) and cosmesis is acceptable [139, 141, 142]. If feasible, preservation of the coronal ridge helps maintain sexual function and provides excellent cosmetic outcomes as shown by a small retrospective report [143]. Resection, as opposed to ablative or topical treatments, provides the advantage of complete histopathological local staging and detection of areas of invasion; in one study in cases of glans resurfacing for presumed PeIN, up to 20% of patients were found to have invasive disease on histopathological examination [139]. Surgeons and pathologists are urged to discuss appropriate specimen handling (e.g., pinning down the skin as resected) and pathological reporting of these cases to aid further management and avoid over-reporting of positive margins [144].

6.1.2 **Treatment of invasive disease confined to the glans (cT1/T2)**

When feasible, small and localised invasive lesions should receive organ-sparing treatment. Resection of the primary lesion not only eradicates all disease in localised invasive tumours but also provides definitive pathological staging without the risk of understaging and of missing intra-tumour heterogeneity encountered with incisional or punch biopsy [10]. Foreskin tumours are treated by ‘radical’ circumcision. For glandular and coronal lesions, wide local excision, partial glansectomy or total glansectomy with reconstruction, are surgical options while additional circumcision is advised in glandular tumours. External beam radiotherapy and brachytherapy are radiotherapeutic options for these patients. Laser therapy of small lesions has been reported but the risk of invasive disease must be recognised, and the recurrence risk is high, possibly as a result of the limited tissue penetration depth of laser ablation. Further research is needed to better establish the comparative safety and effectiveness of surgical and nonsurgical therapies for penile cancer.

Treatment choice depends on tumour size, histology, stage and grade, localisation and patient preference. Over the recent decades, a shift towards organ-sparing surgery has been observed, based on the assumption that local recurrence has little influence on long-term survival. However, in a large series looking at higher-risk tumours treated with glansectomy [145] or partial penectomy [146], it was observed that patients experiencing local recurrence have poorer survival, also in multivariate analysis correcting for poor prognosticators. This, however, does not indicate that these patients may have fared better with more radical excision, as local recurrence in those cases may be a display of a more aggressive disease biology in general. On the other hand, large series are available showing lower local recurrence rates after amputative surgery despite more aggressive tumours, supporting a wider resection [147].

The SR by the Panel found a cumulative 5-year recurrence free rate (RFR) of 82% in case series and 76.7% in non-RCTs for organ-sparing surgery. Similarly, the cumulative 5-year RFR of amputative surgery is reported 83.9% in case series and 93.3% in controlled studies. These variations reflect the differences of study designs as well as the different cohorts analysed at each instance; a larger proportion of patients treated with amputative surgery typically present with advanced disease (\geq T3: 29.4% vs. $<$ T3: 7.8%). The higher RFRs observed after amputative surgery needs to be weighed against the impact on sexual function and QoL. Hence, the limits of organ-sparing surgery are not completely clear, and the higher risks of local recurrence should be discussed with the patient when making a treatment plan.

6.1.2.1 *Width of negative surgical margins*

The concept of organ-preserving surgery is based on observations of how the distance between tumour and resection margin affects local recurrence. A study found that most lesions do not spread $>$ 5 mm beyond the macroscopic margin and, in line with this finding, subsequent reports show that an excision margin of between 5 mm and 10 mm results in acceptably low recurrence rates [148–150]. Another study from a supra-regional referral centre found that local recurrence rates only increased considerably when the distance from tumour to margin was

< 1 mm [151]. However, comparative evidence is lacking for this topic and there is no clear evidence as to what constitutes an oncologically safe width of macroscopic negative surgical margins. Based on the observation that in lower-risk tumours (1) a local recurrence does not impact survival and (2) minimal section margins > 1 mm do not result in a higher risk for local recurrence, macroscopic margins can indeed be minimal, specifically in smaller and less aggressive lesions. Hence, to ensure complete removal with histologically negative margins, standard excision must include a margin of clinically normal-appearing skin around the tumour and surrounding erythema. However, for bulky or higher-grade lesions where local recurrence may have an impact on survival, adoption of a wider margin or partial penectomy may be prudent and should be discussed with the patient [145, 150].

6.1.2.2 *The use of intra-operative frozen section assessment*

The role of frozen section and its value in the interpretation of excision margins remains uncertain, potential benefits of adopting frozen section assessment include a decreased risk of local recurrence and a smaller safety margin, allowing maximum preservation of penile tissue. A study in 169 patients treated in a tertiary referral centre in the UK showed that frozen section use during organ-sparing surgery contributed to a very low definitive positive margin rate of 0.6% and a local recurrence rate of 5.3% [152, 153]. These data, however, are contradicted by a large contemporary series, also from a tertiary referral centre in the UK, showing similarly low local recurrence rates of 4% without routine intra-operative frozen section analysis [151]. A SR conducted in 2017 stated that routine frozen section analysis results in lower rates of local recurrence but failed to correct for patient selection, and hence a causal relationship between frozen section analysis and low local recurrence rates is lacking, as is comparative research. Data from one multi-centre study suggests that differentiated PeIN, squamous hyperplasia and lichen sclerosis present at the surgical margins are frequent findings and are not relevant for CSS [77]. As negative surgical margins are aimed for, in cases of doubt on the radicality of the resection, it is the Panel's opinion that frozen section analysis is a helpful tool to achieve definitive tumour-free margins, whereas it is not recommended to be used routinely.

6.1.2.3 *Laser ablation*

In line with results achieved in non-invasive and superficially-invasive penile lesions, laser ablation has been proposed as an option for smaller invasive lesions. Typically, a CO₂ laser can resect the tumour with ample millimetres of margin, while for coagulation of the tumour bed a Nd:YAG laser is the better option as it provides deeper uniform tissue coagulation. Healing time is fastest after CO₂ laser treatment, with re-epithelization almost complete by three to six weeks post-treatment. Because of the greater depth of tissue coagulation, the healing time for Nd:YAG laser treatment is longer, often up to six weeks [134]. Penetration depth depends on laser type and settings and most commonly used settings are 15–20 W for CO₂ and 15–25 W for Nd:YAG lasers but only very few publications provide technical details [134].

In the Panel's SR, seven studies reported outcomes of laser therapy for invasive penile cancer limited to T1 (81.2%) or T2 (18.5%) disease in a total of 389 patients [3]. Five-year RFR ranged from 34.2–94%. The cumulative mean 5-year RFR was 69.4% (270/389). Three studies reported a 5-year RFR per disease stage of 42.9–73.9% for T1 and 23.5%–84.2% for T2 disease. In nine studies (n = 512), the penile preservation rate following laser therapy was 50–100% (mean 89.2%), indicating that a large proportion of recurrences had to be managed with total amputation, which raises caution on the use of such technique and its use is likely best limited to T1 tumours. Tang *et al.*, demonstrated that nodal recurrence was high in a multi-institutional cohort of patients treated with laser ablation as monotherapy, illustrating the importance of pre-ablation biopsy for risk stratification and nodal staging. Clinicians should be aware of the risk of understaging as a result of incision biopsy followed by ablation vs. complete resection [10, 154], and it is advised that patients be informed that laser therapy may result in higher local recurrence rates when compared to surgical excision.

Three studies reported on laser-related complications, with preputial oedema and dysuria reported most frequently. Meatal stenosis was reported in 7.4% and post-operative bleeding in 1–7% of patients. Three studies assessed the sexual function after laser treatment and 46.0–56.5% of men report an impact on their sexual life. A single trial including 46 men found that 72% reported no change in erectile function, 22% reported decreased erectile function and 6% reported improvement [155].

6.1.2.4 *Moh's micrographic surgery*

Moh's micrographic surgery is a surgical technique by which tissue is excised and processed with en face histological margins in real time to give a complete circumferential and deep margin. It aims at maximal organ-preservation by adopting margin-guided excision. Three studies reported the 5-year RFR in 51 men, most with T1 disease. Recurrence-free rates ranged from 71.4 to 100% with a cumulative mean 5-year RFR of 88.2% (45/51) [3]. As data are very limited, it is not routinely recommended, and the Panel feels it is important to involve a clinician experienced in penile cancer management before referral for Moh's surgery.

6.1.2.5 *Wide local excision and circumcision*

In addition to treating preputial penile cancer, circumcision combined with topical treatment, laser therapy or brachytherapy, facilitates follow-up examinations [153]. For small, distal preputial penile cancer, circumcision alone usually presents adequate treatment. However, lesions located on the corona or glans, limited in size, may be treated with wide local excision which should include a margin of clinically normal-appearing skin around the tumour and surrounding erythema (see Section 6.1.2.1). Few data on wide local excision are available, the technique has, so far, only been described in retrospective series combining various types of organ-sparing treatments.

6.1.2.6 *Glans resurfacing*

Besides its established effects in the therapy of PeIN, total or partial glans resurfacing has been reported to be employed for superficially-invasive lesions combined with deeper resection at the site of invasion. The literature is heterogeneous with many studies reporting miscellaneous techniques of organ-sparing surgery including glans resurfacing without specification of tumour invasiveness in these patients specifically. Five studies have reported results of glans resurfacing specifically in invasive penile cancer in a total of 68 patients, with most being pT1 and a few instances of T2 lesions displaying RFR ranging from 75–96.6% [143, 151, 156-158]. Similar to glans resurfacing as applied to carcinoma *in situ*, graft-related complications are scarce and cosmesis, as assessed by patients, is generally good. Cakir and colleagues have described a small series using a technique for glans resurfacing with preservation of the coronal sulcus for distal tumours not invading the sulcus and show that this option can be considered when aiming for maximally preserved erogenous sensation [143].

6.1.2.7 *Glansectomy*

Patients with tumours confined to the glans and prepuce that are not eligible for wide local excision or glans resurfacing are good candidates for glansectomy. Patients with poor vascular function, diabetes, immunosuppression, or previous radiation to the groin area are less suitable for graft application due to higher failure rates which should be discussed with the patient when making the decision between graft application for primary closure. For cases in which the lesion is confined to the glans and is clearly away from the corporal tips according to imaging or clinical examination, an approach that uses dissection over Bucks' fascia can be used to excise the glans, while in cases of doubt, a plane under the Bucks fascia can be used. In the Panel's SR, glansectomy with or without resection of the outermost tips of the corpora cavernosa was assessed in six studies including 1,681 men, 86.4% of whom with T1–T2 disease. The 5-year RFR ranged from 78.0–95.8% [3]. A split-thickness skin graft is commonly used to reconstruct a neo-glans and the graft loss rate was 1.5–23.5%. The incidence of meatal stenosis in a recent SR was 2.8–14.3%. Good cosmetic outcomes and normal erections were reported in 95–100% and 50–100% of cases, respectively [159]. In a large retrospective study by Roussel and colleagues, describing a multicentre cohort including 230 pT1, 534 pT2 and 108 pT3 patients treated in high-volume centres, the authors found high-grade disease and pT3 to be independent risk factors predicting local recurrence. Three-year local RFS rates were 94.8%, 87.3% and 69.7% in patients with no, one, or both, risk factors, respectively. Moreover, in this population, local recurrence remained a significant predictor of decreased overall- and CSS, even when excluding margin-positive cases, patients with pT3 disease, and patients with clinical LN involvement. Hence, these issues should be discussed with the patient prior to surgical intervention when choosing between glansectomy and the more aggressive partial penectomy.

6.1.2.8 *Partial penectomy*

Amputative and partial amputative surgery is reserved for more advanced disease. Results of partial or total penectomy were reported in 5 heterogeneous studies with a total of 243 patients. 71.6% of men were staged as T1–T2 and the 5-year RFR was 75.8-95.4%. The cumulative mean 5-year RFR was 83.9% (204/243). Two cases series including T1 and T2 men, reported 92% and 95.4% 5-year RFRs after partial penectomy [3]. There is no comparative evidence between partial penectomy and glansectomy for T1–T2 lesions, however most case series report similar RFRs between penile-sparing surgery and amputative surgery. In a series of T1 and T2-only disease, 5-year RFR after amputative surgery were superior to penile-sparing surgery, indicating that a wider resection is protective against local recurrence and should always be discussed as an alternative option, although the higher RFRs observed after amputative surgery needs to be weighed against the impact on sexual function and QoL.

6.1.2.9 *Radiotherapy for T1 and T2 disease*

Radiotherapy is an organ-preserving approach with good results in selected patients with T1–2 lesions [3]. It can be given as external radiotherapy with a minimum dose of 60 Gy EQD2 combined with a brachytherapy boost or as brachytherapy alone [160, 161]. Brachytherapy has been studied only for lesions < 4 cm hence its use should be limited to tumours not exceeding this size. Reported results are best with brachytherapy with

local control rates ranging from 70–90% [160, 161]. The American Brachytherapy Society and the Groupe Européen de Curiethérapie-European Society of Therapeutic Radiation Oncology consensus statement for penile brachytherapy also reported good tumour control rates, acceptable morbidity, and functional organ preservation for penile brachytherapy for stages T1 and T2 disease [160]. Penile preservation rates of 70–88% have been reported [162], with overall penile conservation rates of 87% and 70% at 5 and 10 years. Pulsed-dose-rate brachytherapy can be used interchangeably with traditional low-dose rate and 15% local recurrences have been reported in one series [163]. High-dose rate brachytherapy has been introduced but experience is still limited [164-169].

The Panel's SR identified 21 studies evaluating the efficacy of radiotherapy for the management of primary tumour in men with penile cancer. A total of 1,222 men had low-, pulse-, or high-dose rate brachytherapy after circumcision [3]. The cumulative mean 5-year RFRs were 78.6% (861/1,096) after brachytherapy and 55.2% (37/67) after EBRT. Four studies (including some EBRT and some brachytherapy cohorts) reported RFRs per disease stage, with 5-year RFRs for T1 ranging from 59–94%, 50–67% in T2, and 17–77% in T3 disease [167, 170-172].

In the few studies comparing surgical treatment and radiotherapy, results of surgery were slightly better. In a meta-analysis comparing surgery and brachytherapy, 5-year OS and local control rates were 76–84% for surgery and 73–79% for brachytherapy, respectively [173]. The organ preservation rate for brachytherapy was 74% and there was no difference in survival. Local recurrence after radiotherapy can be salvaged by surgery [170].

Specific complications of radiotherapy for penile cancer are urethral stenosis (20–35%), glans necrosis (10–20%) and late fibrosis of the corpora cavernosa [174]. With brachytherapy, meatal stenosis has been reported to occur in up to 40% of cases but was much lower in a contemporary series of 73 patients with only 6.6%. In that series, 2.6% of patients reported pain with sexual intercourse and 5.3% dysuria over a follow-up of 5 years. Penile amputation for necrosis was necessary in 6.8% of patients [175].

Functional outcome after radiotherapy has not often been reported. In one report, 17/18 patients with normal erections before treatment maintained these after treatment [176]. After a minimum of 3 years (median 5.9) follow-up after brachytherapy treatment, 29/34 patients (median age 63 years) answered a self-reporting questionnaire. Urethral dilatation had been necessary in 30% of patients, self-catheterisation in 13%; erectile dysfunction was mild and 70% continued to maintain sexual activity, and QoL was good.

6.1.3 **Locally advanced disease (T3–T4)**

6.1.3.1 *Resectable disease*

In cT2 disease where there is doubt of corporeal or tunica albuginea invasion, rather than continuing the dissection over Buck's fascia to perform glansectomy combined with distal corporectomy, dissection superficial to the tunica albuginea can be adopted after dividing the neurovascular bundle. In these instances, frozen sections of the corporeal tips and urethra may be helpful in assessing the radicality of the procedure peri-operatively. Pre-operative MRI or US can assist in surgical planning as discussed in Chapter 5. For cT3 patients with obvious involvement of the corpora cavernosa, partial amputation is standard. Patients can be offered reconstructive options such as urethral centralisation and/or neo-glans formation with the use of a graft. Two studies in higher-risk patients treated with radical glansectomy or partial penectomy show that local recurrence in these instances is associated with poor survival. Patients should be informed that a wider resection (i.e., partial or radical penectomy) provides a lower risk of local recurrence at the cost of functionality of the penis [145, 177]. Radical amputation and diversion of urination with a perineal urethrostomy is reserved for those patients in whom a resection with a safe margin would result in the inability to void standing upright or without wetting the scrotum. Radiotherapy for locally-advanced penile lesions should be undertaken with concurrent chemotherapy. As with disease in the LNs, traditional radiotherapy dosing recommendations are being reconsidered [178]. Complex treatment planning will be necessary in most cases of T3–T4 primary lesions, with patient-unique immobilization to spare testes and scrotum. A total phallic reconstruction may be offered to patients undergoing total/subtotal amputation. Extensive partial amputation with wide margins or total penectomy with perineal urethrostomy is the standard advisable treatment. In case of locally-advanced and ulcerated cases which are resectable, composite myocutaneous flaps or advancement flaps may be needed to cover the surgical defect [179].

6.1.3.2 *Non-resectable disease*

In non-resectable disease, induction chemotherapy offers the ability to downstage disease and thereby enable surgical resection among responders, even among men with advanced penile cancer. Several retrospective- and prospective series have evaluated the effects of combination regimens using paclitaxel or docetaxel with cisplatin and ifosfamide or 5-FU. The combination of irinotecan and cisplatin, and vinflunine as monotherapy, have also been investigated. Although there is considerable heterogeneity in the regimens and cohorts combining advanced nodal disease and unresectable primary tumours, objective responses are observed in

29–60% of patients [177, 180-186]. In two recent SRs pooled ORR were 53–57% [187] with pooled objective response rates of 57% (95% CI: 46–67%) for taxane-platinum combinations and 54% (95% CI: 31–76%) for non-taxane platinum combinations [188], and pathological complete responses in 4–10% [188], at the cost of considerable toxicity. This approach is discussed in more detail in Section 6.4.1.1. In case of not obtaining a response sufficient for resection, **palliative** chemo-radiotherapy is an option.

Accumulated evidence in anal and vulvar cancer supports the notion that definitive chemo-radiotherapy is an effective treatment for anogenital SCC [189]. In a single study in six node-positive SCC penile cancer patients, 4 of the 6 patients were recurrence-free and two had developed recurrence, of which one patient died [189]. In a currently unpublished observational cohort study in 40 loco-regionally advanced penile cancer patients fit for chemo-radiotherapy and treated with curative intent, Ottenhof and colleagues observed that only half of the patients proceeded to surgery, and one- and 2-year PFS was 32% with a > grade 3 toxicity rate of 40% [190]. Their regimen consisted of integrated boost intensity modulated radiotherapy with a dose of 59.5 Gy to the primary tumour in fractions of 1.8 Gy with mitomycin C on day one and capecitabine on radiation days. In comparison to peri-operative chemotherapy studies, the omission of surgery is a potential advantage of chemo-radiotherapy. As this strategy has only been evaluated in a single observational study without a published full text at the moment of writing, no recommendation can be made supporting this approach in patients suitable for other options.

6.1.4 Local recurrence after organ-sparing surgery

A second organ-sparing procedure can be performed if there is no corpus cavernosum invasion [136, 149, 191-193]. For large or high-stage recurrence, partial or total amputation is required, unless unresectable or concurrent with nodal or distant metastatic recurrence (see respective sections).

6.1.5 Summary of evidence and guidelines for local treatment of penile carcinoma

Summary of evidence	LE
Penile intra-epithelial neoplasia progress to invasive lesions in 2.6–13% despite treatment.	3
Response and recurrence rates of topical therapies for PeIN are 40–100% and 20% for IQ and 48–74% and 11% for 5-FU. For laser therapy, response rates are 52–100% and recurrence rates 7–48%. For glans resurfacing, recurrence rates are as low as 4%.	3
A SR including retrospective studies on organ-sparing surgical treatment of the primary lesion shows that cumulative mean 5-year RFRs are 82% in case series and 76.7% in non-RCTs. For (partial) amputative surgery these are 83.9% in case series and 93.3% in non-controlled studies. The cumulative mean 5-year RFR was 69.4% for patients treated with laser therapy for invasive disease.	3
Current literature on frozen section analysis in organ-sparing surgery is heterogeneous and conflicting.	3
Tumour distance to the resection margin < 1 mm resulted in higher local recurrence rates in a recent large retrospective case series from a tertiary referral centre.	3
Several retrospective series from claims databases and high-volume centres studying non-specified organ-sparing surgical and ablative techniques show no impact of local recurrence on CSS where case mix is pitched towards lower grade, lower stage tumours. However, a recent large retrospective series of glanssectomies performed in high-volume centres showed local recurrence was a predictor of poor CSS in a cohort with a high number of T2, T3 and high-grade lesions.	3
The cumulative mean 5-year RFRs are 78.6% after brachytherapy and 55.2% after EBRT.	3
For neo-adjuvant chemotherapy, pooled ORR was 53% (95% CI: 42–64%), the pCR rate in prospective studies was 4–10% (95% CI: 5–30%) in a recent SR and meta-analysis.	2a

Recommendations	Strength rating
Offer a balanced and individualised discussion on benefits and harms of possible treatments options with the goal of shared decision making.	Strong
Inform patients of the higher risk of local recurrence when using organ-sparing treatments compared to amputative surgery.	Strong
Topical therapy	
Offer topical therapy with 5-fluorouracil or imiquimod to patients with biopsy-confirmed penile intra-epithelial neoplasia (PeIN).	Weak

Clinically assess treatment effects after a treatment-free interval and in cases of doubt perform a biopsy. If topical treatment fails, it should not be repeated.	Weak
Laser ablation	
Offer laser ablation using CO ₂ or Nd:YAG laser to patients with biopsy-confirmed PeIN, Ta or T1 lesions.	Weak
Organ-sparing treatment: surgery (circumcision, wide local excision, glansectomy and glans resurfacing)	
Offer organ-sparing surgery and reconstructive techniques to patients with lesions confined to the glans and prepuce (PeIN, Ta, T1–T2) and who are willing to comply with strict follow-up.	Strong
Perform intra-operative frozen section analysis of resection margins in cases of doubt on the completeness of resection.	Weak
Offer salvage organ-sparing surgery to patients with small recurrences not involving the corpora cavernosa.	Weak
Organ-sparing treatment: radiotherapy (EBRT and brachytherapy)	
Offer radiotherapy to selected patients with biopsy-confirmed T1 or T2 lesions.	Strong
Amputative surgery (partial- and total penectomy)	
Offer partial penectomy, with or without reconstruction, to patients with invasion of the corpora cavernosa (T3) and those not willing to undergo organ-sparing surgery or not willing to comply with strict follow-up.	Strong
Offer total penectomy with perineal urethrostomy to patients with large invasive tumours not amenable to partial amputation.	Strong
Offer amputative surgery to patients with large local recurrences or corpora cavernosa involvement.	Weak
Multimodal therapy	
Offer induction chemotherapy followed by surgery to responders, or chemo-radiotherapy to patients with non-resectable advanced primary lesions, or to patients with locally advanced-disease who refuse surgical management.	Weak

6.2 Regional lymph node management: clinically evident disease (cN1–cN3)

6.2.1 Introduction

The development of lymphatic metastases in penile cancer follows the route of anatomical drainage from the primary tumour to the superficial and then deep inguinal LNs (which can occur on both or either side), followed by the ipsilateral pelvic LNs. The superficial nodes are located under the subcutaneous fascia and above the fascia lata within Scarpa's triangle. The deep nodes lie within the region of the fossa ovalis where the superficial saphenous veins anastomose with the femoral vein at the saphenofemoral junction. The Cloquet's node (or Rosenmuller's node) is located medial to the femoral vein around the entrance to the femoral canal and marks the transition between inguinal and pelvic regions. Daseler et al., divided the superficial inguinal LNs into five regions centred around the saphenofemoral junction; central, lateral superior, lateral inferior, medial superior and medial inferior [194]. Studies of radical ILND (rILND) as well as single-photon emission computed tomography (SPECT) imaging suggest that sentinel inguinal nodes, i.e., those first affected by lymphatic spread, appear to be located in the medial superior zone followed by the central inguinal zones [194-196]. No solitary lymphatic spread has been observed from the penis to the two inferior groin regions and no direct drainage to the pelvic nodes, either [194-196].

Pelvic nodal disease does not occur without ipsilateral inguinal LN metastasis. Also, crossover metastatic spread, from one groin to the contralateral pelvis, is rare [197]. Further lymphatic spread from the pelvic nodes to retroperitoneal nodes (para-aortic, para-caval) is classified as systemic metastatic disease [198].

The management of regional LNs is decisive for patient survival. The presence and extent of nodal involvement is singularly the most important prognostic factor in patients with penile cancer. Cure can be achieved in limited LN-disease confined to the regional LNs. Radical LND is the treatment of choice. Multimodal treatment combining surgery, chemotherapy, or radiotherapy is often indicated for more advanced disease.

In clinically positive LNs (cN1/cN2), more extensive LN metastasis is highly likely and LN surgery with histology is required. Given the very high chance of recurrence, enlarged fixed inguinal LNs (cN3) or clinically evident pelvic metastases require multimodal treatment by induction chemotherapy and consolidative surgery in responding patients. Even if present in only one node, extra-capsular extension/ENE, or pelvic LN metastasis found at surgery carries a high risk of progression and is classified as pN3 and requires multimodal treatment.

Given the complexities of regional node management, the intent of the Panel in the following sections (i.e., Sections 6.2–6.4) is to describe the available evidence-based strategies in the management of clinically evident LN metastases (i.e., cN1–cN3). These include inguinal/pelvic LND, chemotherapy, radiotherapy ± chemotherapy and integrated strategies such as neoadjuvant and adjuvant therapies combined with surgery. The reader is encouraged to review the text sections, summaries of evidence, and recommendation tables collectively in order to better understand recommendations for single vs. multimodal treatment and currently available data utilising various strategies.

6.2.2 cN1–N2 disease: radical inguinal lymph node dissection

6.2.2.1 Indication for radical inguinal lymph node dissection

Radical ILND remains the standard of care for patients with cN1–2 (or cN0 patients with a tumour positive SN at DSNB). In low-volume disease (pN1) rILND is curative with a suggestion of equivalent outcomes in those patients without nodal disease [199-201].

Despite this, several studies have demonstrated continuing non-adherence to accepted international guidance [202-205]. Cindolo *et al.*, evaluated adherence of twelve European and American centres to the EAU recommendations [205]. They reported a 26.3% rate of non-adherence in terms of LN management. For those patients managed as per guidance with LND there was a statistically significant association with OS (adjusted HR: 0.48; 95% CI: 0.24–0.96, $p = 0.038$) [205].

6.2.2.2 What is an acceptable definition?

Daseler's original description of a rILND in 1948 is considered the classical description of a radical inguinal LN dissection (rILND) (see Table 6.1) [194]. Despite this, considerable variation exists across high-volume centres. In an international survey of surgeons' practice in European high-volume centres, consensus was not found in the definition of the superior and lateral borders of the dissection, and whether the fascia lata and saphenous should be preserved [206]. This variation in practice is likely a reflection of clinicians and patients desire to reduce the significant burden of morbidity acknowledged in the literature associated with rILND (see later section on complications). A SR of the literature by the Panel identified only one other description of a modified template used in clinical N1–2 disease by Yao *et al.* [207] (see Table 6.1). This retrospective cohort study of 201 fascial-sparing inguinal dissections (fsILND) with < N2 disease, demonstrated comparable oncological outcomes to rILND with 3-year DFS of 92.1% (100% for pN0, 91.3% for pN1, 80% for pN2, and 33.3% for pN3 disease, respectively) and a complication rate of 29.3%. To date, however, no direct comparison exists between rILND and fsILND in this group of patients (Table 6.1).

Table 6.1: Variations in radical inguinal lymphadenectomy

	Superior	Lateral	Medial	Inferior	base	Fascia preserved	Saphenous spared	Sartorius transposition
rILND [194]	Superior margin of external ring to the anterior superior iliac spine	Anterior superior iliac spine inferiorly 20 cm	15 cm downwards from the pubic tubercle	Apex of femoral triangle	Sartorius, femoral vessels, adductor longus	No	No	Yes
fsILND [207]	Superior margin of external ring to the anterior superior iliac spine	Anterior superior iliac spine inferiorly 20 cm	15 cm downwards from the pubic tubercle	Apex of femoral triangle	Fascia	Yes. Deep inguinal LNs, medial to the femoral vein, dissected just distal to the fossa ovalis	Yes	No

fsILND = fascia-sparing inguinal lymph node dissection; rILND = radical inguinal lymph node dissection.

6.2.2.3 Quality metrics

To standardise the quality of resections, several studies have attempted to look for surrogate markers to infer complete oncological resection including LN yield (LNY), LN density (LNDen), and time to completion of surgery.

6.2.2.3.1 Lymph node yield and density

In a SR commissioned by the Panel, several studies were identified examining the association between LNY/ LNDen and survival as a surrogate marker of adequate dissection in penile cancer [203, 208-212]. However, LNY varied from ≥ 8 to $\geq 15-16$ and LND ≤ 6.7 to $\leq 22\%$. The variance in accepted values is likely because of different surgical templates, variable pathological assessment, and stage migration. Consequently, widespread adoption of LNY and LNDen as a predictor of survival and as quality markers cannot be recommended.

6.2.2.3.2 Timing of surgery

Several studies have highlighted the importance of expedient LN management in patients with cN0 disease vs. surveillance with LND on presentation of clinical disease. Two non-RCTs have demonstrated a survival benefit in patients who underwent early ILND compared with delayed ILND (within six weeks of primary surgical treatment vs. surgery following identification of positive nodes during surveillance), showing 3-year CSS 84% vs. 35% ($p = 0.0017$) and 3-year CSS 71% vs. 50%, respectively [98, 213].

The evidence in pN1–2 regarding optimal timing of LN management is limited. Chipollini *et al.*, examined the effects of early vs. late inguinal LN dissection (> three months following primary surgery) in 84 patients with cN0 and cN+ disease. Overall, those patients undergoing early ILND demonstrated a 5-year DSS of 64.1% vs. 39.5% for late dissection with an unadjusted HR of 0.66 (0.32–1.37). However, when sub-analysis was performed in cN+ patients, the 5-year DSS for early vs. late dissections failed to delineate a statistically significant benefit (31.8% vs. 35.3%, respectively) [214].

Gulia *et al.*, examined 28 patients undergoing rILND stratified by < 6 months (group 1) and more than 6 months (group 2) from treatment of the primary tumour (70% and 50% palpable at presentation, respectively). The 5-year CSS was 91 and 13%, respectively ($p = 0.007$) [215].

6.2.2.4 Complications

Radical ILND carries a significant morbidity due to impaired lymph drainage from the legs and scrotum, however it can be lifesaving and therefore should not be avoided [216].

Historical morbidity of the procedure has been as high as 61% [217]. Contemporary large series of rILND suggest between 21–55% of men will suffer a complication [115, 218, 219]. The reduction in morbidity is likely due to a better understanding of pre-, intra-, and post-operative management (see Table 6.2). In a SR commissioned by the Panel the most reported complications in recent series were wound infections (2–43%), skin necrosis (3–50%), lymphoedema (3.1–30%), lymphocele formation (1.8–26%), and seroma (2.4–60%) [115, 199, 215, 218-225]. Table 6.2 lists several strategies and conditions associated with increase, decreased or uncertain effects on morbidity outcomes reported in penile cancer, urologic or in other cancers. Future studies specific to ILND and strategies to decrease morbidity are needed.

Table 6.2: Impact of pre-intra- and post-operative factors on morbidity following radical inguinal lymph node dissection

Positive impact	Negative impact	Uncertain benefit
Linear transverse incision [226, 227]	S-shaped incision, vertical incision [217, 226, 228]	Vacuum dressings [229]
Saphenous sparing [227, 230, 231]	Time-controlled drainage [232]	Fibrin glue [233]
Volume-controlled drainage [232]	Ultrasonic device [234]	Advanced bipolar device [235]
Fascial sparing [207]	Sartorius transposition [219]	
Minimally-invasive techniques [236-238]	Raised BMI [219]	
Lymphoedema prevention, e.g., massage, skin care, saphenous vein-sparing surgery [227, 239]	Increased disease burden [115]	
Deep venous thrombosis prophylaxis [240]	Sarcopenia [220]	
Prevention of surgical site infections, e.g., prophylactic antibiotics, shaving, skin prep [241]		

6.2.2.5 Open versus minimally-invasive approach

In recognition of the significant morbidity associated with rILND, clinicians have sought to reduce these through technical modifications. Expanding interest and experience in minimally-invasive techniques have led to the introduction of video-endoscopic inguinal LND (VEIL) and subsequently robot-assisted video-endoscopic inguinal LND (RAVEIL), using rILND or fsILND templates.

Ports are generally placed at the apex of the femoral triangle, although variations include lateral and hypogastric approaches allowing pelvic lymph node dissection (PLND) through the same incisions [242-244].

A review of the literature commissioned by the Panel identified a single incomplete RCT in 2012 which closed prematurely due to poor accrual, with patients preferentially choosing minimally-invasive approaches over open [245]. The remaining studies identified were either retrospective cohort- or comparative series. Narrative review would suggest that although operative time is longer, LN yields can be similar to open ILND, length of hospital stay shorter in VEIL/RAVEIL and wound complications lower, though lymphocele and readmission rates were equivalent [113, 236, 238, 246-248].

Follow-up for the minimally-invasive approaches were short, and there was a high proportion of patients receiving VEILND or RAVEIL as prophylaxis as opposed to clinically node-positive disease, precluding incorporation in the current guidance. In addition, some studies where open rILND was used as a comparator, involved more morbid manoeuvres when using an open approach, such as Sartorius transposition and saphenous vein sacrifice, which were not replicated in minimally-invasive procedures.

6.2.2.6 Summary of evidence and guidelines for radical inguinal lymph node dissection in cN1-2 disease

Summary of evidence	LE
Open radical ILND is the standard for cN1–2 disease.	2a
Radical inguinal lymph node dissection carries a significant risk of complications (21–55%).	2a
A single study reported on fsILND, fascial-sparing ILND has been reported (single study) and in cN1–2 disease which appears to offer similar oncological outcomes, and reduced complications.	2b
Lymph node yield and LND appear related to survival, however, variance in accepted values, pathological assessment, and stage migration prevent recommendation of a specific LN count.	2a
Delay in nodal management of more than three to six months may affect DFS.	3
Minimally-invasive approaches for ILND (VEIL/RAVEIL) generally have longer operative times, equivalent LN yields, shorter length of hospital stay and lower wound complications when compared with open ILND. However, since current evidence is very limited in cN1–2 patients, no recommendation for minimally-invasive approaches can be provided.	2b

Recommendations	Strength rating
In patients with cN1 disease offer either ipsilateral: <ul style="list-style-type: none"> fascial-sparing inguinal lymph node dissection (ILND) open radical ILND; sparing the saphenous vein, if possible 	Strong
In patients with cN2 disease offer ipsilateral open radical ILND; sparing the saphenous vein, if possible.	Strong
Offer minimally-invasive ILND to patients with cN1–2 disease only as part of a clinical trial.	Strong
Offer neoadjuvant chemotherapy as an alternative approach to upfront surgery to selected patients with bulky mobile inguinal nodes or bilateral disease (cN2) who are candidates for cisplatin and taxane-based chemotherapy (see Section 6.4.1).	Weak
Complete surgical inguinal and pelvic nodal management within three months of diagnosis (unless the patient has undergone prior neoadjuvant chemotherapy).	Weak

6.2.3 Prophylactic pelvic lymph node dissection

Prophylactic PLND (pPLND) in most cases represents a staging procedure that can thus identify candidates for early adjuvant therapy, although in select patients may also provide a therapeutic benefit.

6.2.3.1 Indications for prophylactic pelvic lymph node dissection

6.2.3.1.1 Risk factors for pelvic nodal metastasis

To identify patients with pelvic LN metastasis in the absence of radiological evidence for LN involvement, several studies have tried to develop generalized estimating models based on inguinal characteristics using logistic regression and multivariate analysis. Among various predictors, the number of positive inguinal LNs (1–2 vs. 3, or more, with no extra-capsular extension) was associated with positive pelvic LNs in 0–6.5% of patients vs. 33–67% of patients [249, 250]. The presence of extracapsular spread was also consistently significantly associated with positive ipsilateral pelvic LN metastasis in 4 studies [249-252]. Strong immunoreactivity of p53, LN density > 30% and primary tumour grade are also reported as predictors of pelvic LN involvement [250].

6.2.3.2 What is an acceptable dissection?

In a study by Yao *et al.*, the authors prospectively mapped the distribution of positive pelvic LNs at the time of PLND in 128 patients [197]. Most patients underwent bilateral PLND (86.7%). The median number of nodes retrieved per groin was 18 (interquartile range [IQR] 10–30), with the distribution of positive nodes in the external iliac, obturator, common iliac, internal iliac and presacral packages 50%, 36.6%, 7%, 6.4% and 0%, respectively. Notably two patients were observed to have crossover metastasis from one inguinal region to the contralateral pelvic region, defying the accepted understanding of the historical literature. When the extent of dissection was considered in context of overall- and RFS there was no statistically significant difference [197]. Similar data was seen in a study by Zhu *et al.*, with the external iliac package being more commonly involved than the obturator and common iliac packages [253].

To evaluate the prognostic impact of LN yield on survival outcomes for penile SCC, Chipollini *et al.*, examined 198 patients undergoing PLND [208]. In their cohort they found a LN yield of ≥ 9 was a predictor of RFS (HR: 0.53, $p = 0.032$).

6.2.3.3 Survival and recurrence

The evidence that pPLND has an additional therapeutic effect over surveillance or adjuvant radiotherapy (see Section 6.4.2.2) is limited and significant controversy remains. Djajadiningrat *et al.*, estimated the 5-year DSS in all patients treated with pPLND was 51%. Patients with positive pelvic nodes had a significantly worse 5-year DSS than those without pelvic involvement (17%, 95% CI: 6–47 vs. 62%, 95% CI: 50–76, $p < 0.001$) [251]. A retrospective multicentre study compared the outcomes of bilateral pPLND for N2 or N3 disease vs. no surgery and reported better 5-year OS in the pPLND group (35% vs. 25%) without reaching statistical significance [254]. In N2 patients, 3-year OS was significantly better in the PLND group as compared to the no-surgery group (83.3% vs. 50.2%, $p = 0.03$) [254]. This difference was not evident in N3 patients.

6.2.3.4 Complications

There is limited data available regarding the reporting of complications from PLND. This is complicated by the fact that most patients will have already undergone a rPLND which carries a significant morbidity as discussed above. A single-centre experience of 89 patients, undergoing open PLND for penile cancer reported an overall complication rate of 18%. Nine patients had wound complications including infection, seroma, and dehiscence. The remaining 5 patients had non-wound-related complications such as pneumonia, delirium, and ileus [251].

6.2.3.5 Minimally-invasive versus open pelvic lymph node dissection

In a SR commissioned by the Panel there were no reported studies that examined the role of minimally-invasive pPLND in the setting of penile cancer and PLND. There is, however, a significant body of evidence that exists in other common urological malignancies that demonstrates equivalent oncological outcome as well as improved morbidity profile and recovery profile.

6.2.3.6 Summary of evidence and guidelines for prophylactic pelvic lymph node dissection

Summary of evidence	LE
Prophylactic PLND in most cases represents a staging procedure that can thus identify candidates for early adjuvant therapy, although in select patients it may also provide a therapeutic benefit.	3
Three or more positive inguinal nodes or extranodal extension of cancer in inguinal nodes are associated with a significantly higher incidence of pelvic LN metastases.	3

Recommendations	Strength rating
Offer open or minimally-invasive prophylactic ipsilateral pelvic lymphadenectomy to patients if: <ul style="list-style-type: none"> • three or more inguinal nodes are involved on one side on pathological examination • extranodal extension is reported on pathological examination 	Weak
Complete surgical inguinal and pelvic nodal management within three months of diagnosis (unless the patient has undergone neoadjuvant chemotherapy).	Weak

6.3 Clinical N3 disease (cN3)

6.3.1 Diagnostic evaluation

Patients with clinical N3 disease as defined by the presence of a fixed inguinal mass (i.e., to skin or underlying structures) or pelvic lymphadenopathy based upon imaging should undergo a complete staging evaluation including cross sectional imaging (i.e., PET/CT or CT, see Section 5.2.3), if not already performed [255]. Biopsy of the inguinal mass in the setting of a patient with a known diagnosis of penile cancer is not required but should be performed in a previously undiagnosed patient, as needed, to establish the diagnosis and facilitate accurate staging.

6.3.2 Management strategy

Neoadjuvant chemotherapy (NAC) is a reasonable strategy among cN3 patients based on the results of a recent SR which reported radiological response rates of approximately 53% and pathological complete response in approximately 12.8% of patients [187, 256]. This review consisted mostly of retrospective series; complete response rates in the intention to treat population were 10% (paclitaxel, ifosfamide, and cisplatin [TIP]) and 4% (docetaxel, cisplatin and fluorouracil [TPF]) in prospective trials [177, 180]. In responding patients, and those with no evidence of disease progression, surgical resection to remove all residual disease utilizing radical inguinal and PLND techniques is the preferred strategy. For a detailed examination of peri-operative chemotherapy please see Section 6.4.1.

Pre-operative radiotherapy was used in a single study among a cN3 cohort of 12 patients and reported an objective response in only 2 patients with 7 of 12 patients subsequently undergoing ILND. Only 2 patients (17%) survived 5 years [257]. It is worth recognising that this data, however, utilises historical radiotherapy techniques precluding meaningful extrapolation to modern practice (see Section 6.4.2 for further details).

Surgery as the initial treatment in patients with a fixed inguinal mass or clinically evident pelvic adenopathy (cN3) at presentation or recurrence is discouraged in routine management. While often technically feasible a “surgery first approach” often results in large skin/soft tissue defects, the need for myocutaneous flap reconstruction, prolonged hospital stays (mean or median 8.5–23 days) and is associated with high overall complication rates (65–77%) [258, 259]. In a single-centre study among 24 patients treated with surgical debulking alone in the advanced disease setting, the median CSS and DFS were only six and three months, respectively [259]. In the same study 17.5% of patients exhibited rapid progression of disease post-surgery and never received adjuvant therapy [259].

6.3.3 Patient selection for consolidative radical inguinal/pelvic lymphadenectomy

Patients whose tumours respond to NAC and subsequently undergo surgical consolidation represent a favourable subgroup of patients with a mean 5-year survival of 56.9% according to a SR [256]. Among cN3 patients who are not candidates for conventional multi-agent chemotherapy, pre-operative chemo-radiation/radiation can be offered in an attempt to downsize tumours to improve resectability. The evidence for this, however, is recognised to be weak but is being prospectively investigated in the InPACT study [260].

6.3.4 Surgical technique

6.3.4.1 Inguinal lymph node dissection

Surgical resection should proceed 5–8 weeks after completion of chemotherapy to provide time for haematologic recovery and other therapy related symptoms to improve.

Pre-operative planning to remove all residual disease taking into consideration the size of the mass, involvement of surrounding structures, and the anticipated skin and soft tissue defects as well as plastic surgical consultation (as appropriate) is required for successful outcomes.

6.3.4.2 Lymphadenectomy boundaries

Surgical boundaries should follow that of a ‘radical inguinal lymph node’ dissection” (described in Table 6.1). Wide resection of involved skin is often required with *en bloc* ILND. Considering the extent of inguinal

metastases along with fixation to adjacent structures, minimally-invasive techniques (i.e., robotic-, laparoscopic ILND) are considered inappropriate in cN3 inguinal metastases.

6.3.4.3 Pelvic lymph node dissection

Simultaneous PLND should be performed at the time of ILND if pelvic LN metastases were clinically evident at diagnosis. Ipsilateral PLND should also be performed in a simultaneous (preferred) or delayed fashion in the setting of advanced bulky inguinal metastases without clinically evident pelvic metastases as well (i.e., prophylactic). In the latter setting, microscopic pelvic metastases were noted quite frequently (44–100%) in the setting of extracapsular disease and especially when an inguinal mass was present in one series [249].

6.3.4.4 Surgical complications in cN3 disease

Resection of bulky/fixed inguinal masses with or without prior chemotherapy is associated with a variety of complications. Minor complications not requiring hospitalization or surgical intervention are common and tolerable when cure or significant palliation can be achieved. Major post-surgical complications requiring medical or surgical intervention or associated with disability, or death, in several series included infection/sepsis (1.5–4.5%), lymphocele requiring drainage (0–3.8%), wound dehiscence or necrosis requiring debridement (1.5–5.6%), pneumonia (0–2.9%), deep venous thrombosis/pulmonary embolus (0–8.7% and death (0–5.6%) [180, 258, 259]. Overall, in the three selected series of patients treated at experienced centres the incidence of major complications as described above was less than one in ten patients with 3/82 (3.9%) patients succumbing to sepsis or other early peri-operative complications.

6.3.5 Summary of evidence and guidelines for the surgical management of cN3 disease

Summary of evidence	LE
Surgery alone will rarely cure patients with cN3 disease.	3
Even when technically feasible, upfront surgery is associated with significant complications which may delay or prevent delivery of adjuvant therapy.	3
About half of the patients with advanced (cN2–cN3) penile cancer respond to combination chemotherapy. Responders that subsequently undergo consolidative inguinal/PLND have an OS chance of about 50% at 5 years.	2a
Inguinal LND in cN3 patients often requires resection of overlying skin to effectively remove a fixed bulky nodal mass.	4
The available literature includes virtually no cN3 patients to assess the efficacy or safety of minimally-invasive ILND.	4

Recommendations	Strength rating
Offer neoadjuvant chemotherapy (NAC) using a cisplatin- and taxane-based combination to chemotherapy-fit patients with pelvic lymph node involvement or those with extensive inguinal involvement (cN3), in preference to up front surgery. (see Section 6.4.1).	Weak
Offer surgery to patients responding to NAC in whom resection is feasible.	Strong
Offer surgery to patients who have not progressed during NAC, but resection is feasible. See also (chemo)radiation.	Weak
Do not offer Video Endoscopic Inguinal lymphadenectomy.	Strong

6.4 Role of multimodal chemotherapy/radiotherapy in the management of (regional) lymph nodes

6.4.1 Systemic therapy

6.4.1.1 Neoadjuvant chemotherapy

Bulky inguinal LN enlargement indicates extensive lymphatic metastatic disease for which few patients will benefit from surgery alone. Neoadjuvant chemotherapy before inguinal LN surgery allows for early treatment of systemic disease and down-sizing of the inguinal LN metastases. In responders, complete surgical treatment is possible with reasonable clinical outcome.

Cisplatin/5-FU (PF) chemotherapy achieved a response rates of 25–50% with acceptable toxicity [261, 262]. Over a period of 30 years, five different NAC regimens including PF were used in twenty patients, with long-term survival in 37% of responders who underwent radical LN surgery after NAC [263]. In the EORTC cancer study

30992, 26 patients with locally-advanced or metastatic disease received irinotecan and cisplatin chemotherapy. Although the study did not meet its primary endpoint (response rate), there were three cases of pathologically complete remissions (pCRs) [186].

Hypothetical similarities between penile SCC and head and neck SCC led to the evaluation in penile cancer of chemotherapy regimens with an efficacy in head and neck SCC, including taxanes. A phase II trial evaluated treatment with 4 cycles of neoadjuvant paclitaxel, cisplatin, and ifosfamide (TIP) in patients with clinical N2 or N3 LN metastases [180]. An objective response rate (ORR) of 50% was reported in 30 patients, including three pCRs. The estimated median time to progression (TTP) was 8.1 months and the median OS was 17.1 months. Long-term DFS was observed in 67% of responding patients and 7% of non-responding patients.

The combination of PF plus a taxane has been used in neoadjuvant and adjuvant settings [183, 184, 264, 265]. A phase II trial with docetaxel, cisplatin, and 5-FU (TPF) reported an objective response of 38.5% in 29 locally-advanced or metastatic patients, although the study did not meet its primary endpoint, and there was significant toxicity [184]. A prospective study testing neoadjuvant TPF in 26 patients with loco-regionally advanced penile cancer showed a pathologic complete response in one patient, with a 2-year PFS and DSS probability of 12% and 28%, respectively [177]. Treatment was discontinued in 23% of patients because of toxicity. In a recent meta-analysis analysing 10 studies (n = 182 patients, mostly retrospective), the pooled ORR was 53% (95% CI: 42–64), and the overall mortality was 55% (95% CI: 40–70) [187]. The available evidence favours a cisplatin- and taxane-based combination (doublet or triplet) as the preferred approach.

Overall, these results support the activity of pre-operative chemotherapy in patients with clinically-involved regional LNs from penile SCC. However, randomised studies are lacking and substantial concerns remain regarding the selection of patients who are best suited for a systemic therapy approach upfront. A large retrospective study including 743 patients who received a LND from several international institutions suggested patients with a clinical N3 stage constituted the cohort with the most appreciable benefit from NAC use, compared to LND alone [266]. Bilateral inguinal LN involvement emerged as a strong negative predictor of clinical outcome in patients with penile SCC, together with pelvic nodal involvement.

In summary, given the poor outcome of upfront surgery, NAC is a potentially-suitable approach for patients having pelvic LN (cN3) metastases or fixed inguinal LN involvement (cN3), or bulky or bilateral involvement (cN2). In nonresponding patients, the potential benefits of surgery should be re-evaluated as prognosis is poor in these patients. See also section on chemo-radiotherapy.

6.4.1.2 Adjuvant chemotherapy

There are known poor prognostic characteristics for a subset of patients with resected high-risk disease (such as involved pelvic LNs), indicating the likely presence of micrometastatic disease. Data exists on response rates for those with metastatic disease and there is possible benefit for pre-operative chemotherapy for those with unresectable locally advanced disease as described above. With extrapolation from other diseases, it stands to reason that systemic therapy following resection (i.e., adjuvant therapy) may improve outcomes.

A retrospective multicentre analysis of patients with resected pathologically involved pelvic LNs suggested a potential benefit of adjuvant chemotherapy [264]. In this series, 84 patients were analyzed. Patients who received chemotherapy for relapsed disease were excluded. Compared to those not receiving adjuvant chemotherapy, patients who received adjuvant chemotherapy were younger, had lower T stage, more likely to have unilateral (rather than bilateral) LN involvement, and were less likely to receive adjuvant radiation. On multivariable analysis, receipt of adjuvant chemotherapy was associated with improved OS (HR: 0.40, 95% CI: 0.19–0.87, p = 0.021). Additional series have also been reported, including a series of 611 patients from the National Cancer Database reported in abstract form [267]. After adjusting for co-variates, there was no difference in survival for those receiving adjuvant chemotherapy.

A recent meta-analysis examined this issue. After a systematic search, 7 studies were identified examining the use of peri-operative chemotherapy, 4 of which examined adjuvant chemotherapy (n = 771) [268]. There was no difference in survival for those receiving adjuvant chemotherapy vs. observation (HR: 0.95, 95% CI: 0.48–1.80).

Upon examination of the overall data, there is no strong data supporting the use of adjuvant chemotherapy to improve OS following surgical resection of the primary tumour and involved LNs. However, given the fact that RFS is a relevant endpoint that has been suboptimally studied and there is a subset of patients at very high risk of recurrence, the Panel recommends a balanced discussion of risks and benefits of adjuvant chemotherapy

in those thought to be healthy candidates. As previously stated for the neoadjuvant setting, the benefit from adjuvant chemotherapy is expected to be highest in the population of patients with pathological N3 stage, in particular for those patients with pelvic nodal involvement [266]. See also Section 6.4.1.2 on adjuvant radiation and chemo-radiotherapy.

6.4.1.3 Summary of evidence and guidelines for neoadjuvant and adjuvant chemotherapy

Summary of evidence	LE
Results support the activity of NAC in patients with clinically involved regional LNs from penile SCC. However, randomised studies are lacking, and substantial concerns remain regarding the selection of patients who are best suited for a systemic therapy approach upfront.	2b
The available evidence favours a cisplatin- and taxane-based combination (doublet or triplet) as the preferred approach.	2b
Limited data support the use of adjuvant chemotherapy to improve OS following surgical resection. However, it could be offered to patients with pN3 disease post-LND if NAC has not been received, upon careful consideration of risks and benefits with the patient.	4

Recommendations	Strength rating
Offer neoadjuvant chemotherapy using a cisplatin- and taxane-based combination to chemotherapy-fit patients with pelvic lymph node involvement or those with extensive inguinal involvement (cN3), in preference to up front surgery.	Weak
Offer chemotherapy as an alternative approach to upfront surgery to selected patients with bulky mobile inguinal nodes or bilateral disease (cN2) who are candidates for cisplatin and taxane-based chemotherapy.	Weak
Have a balanced discussion of risks and benefits of adjuvant chemotherapy with high-risk patients with surgically resected disease, in particular with those with pathological pelvic LN involvement (pN3). See also section on post-operative radiotherapy.	Weak

6.4.2 Radiotherapy

6.4.2.1 Pre-operative radiation therapy

The role of pre-operative chemo-radiotherapy is being investigated in the ongoing InPACT trial [260]. Since surgical therapy of enlarged LNs is of paramount importance, it is unlikely that pre-operative radiotherapy alone would provide sufficient benefit. Should a patient who is otherwise unfit for chemotherapy require treatment to LNs while awaiting surgery, radiotherapy alone may be considered using conventional daily fractionation to 45–50Gy. Radiotherapy to the groins in penile cancer conceptually requires inclusion of the pre-pubic fat in order to cover in transit lymphatics [269].

6.4.2.2 Post-operative radiation therapy

Adjuvant radiation therapy for node-positive penile cancer remains controversial. Since there is no level 1 evidence to support the benefit of radiation therapy in terms of disease recurrence and survival, it is not recommended in prior guidelines [270, 271]. Radiotherapy is being used in some institutions in the management of regional LNs for penile SCC, based on evidence and experience with other SCC sites (such as head/neck and vulvar carcinomas) [174, 272, 273].

Jaipuria *et al.*, reported that following inguinal- and pelvic LND, patients with > 2 positive LNs but negative pelvic nodes (n = 32) had increased OS with adjuvant radiation therapy compared to adjuvant chemotherapy (48 months vs. 14 months p < 0.0001) [274]. Although 68% of patients had ENE, there were no in-field failures. The radiation dose was higher than that commonly used under these circumstances, 54 Gy for ENE and up to 57–60 Gy for gross residual disease. With a lower radiation dose of 50 Gy, Johnstone *et al.*, reported a high rate of in-field failures (32/39) [275]. At this dose, adjuvant radiation therapy (either groin: p = 0.016 or inguinal-pelvic: p = 0.006) improved RFS only for patients *without* ENE. Ager *et al.*, reporting on the experience with pN3 disease (either ENE or pelvic LN+) in two tertiary referral centres in the UK also found dose to be critically important [276]. A 121 of 146 patients received adjuvant radiotherapy. The 5-year RFS was 51%. Twenty-six of 55 recurrences were in-field, but the risk of in-field failure was twice as high for lower doses < 50 Gy.

For 92 patients with positive pelvic LN from 4 international centres, adjuvant radiation was found to prolong DSS by 6 months and delay the time to recurrence [277].

The data collated in Table 6.3 reveal variable results with conventional radiotherapy delivered in the adjuvant setting, potentially impacted by HPV status and presence/absence of ENE. Also notable in the data is the fact that traditional radiotherapy doses delivered to microscopic disease may be insufficient. Recent genomic data analyses have modelled that a higher radiation dose may be necessary for management of penile cancer primary lesions and nodal basins [278, 279].

Table 6.3: Adjuvant conventional radiotherapy for node-positive penile cancer

Author	n	stage	aRT	Adj CT	RT	LR	OS	Study type
Jaipuria 2020 [274]	45	anyT pN2-3 pelvis pN-	25	7	VMAT/IMRT, 45 Gy basic, 54 Gy ENE, 57-60 macro	No InF	47 mo. RT vs. 14 mo. CT	Prosp registry
Johnstone 2019 [275]	93	anyTpN3 ENE- ENE+			50/25 no details		↑ OS aRT p = 0.037 or aCT p = 0.038 ↑ DSS aRT p = 0.04	4 centres
Winters 2018 [280]	136	pT1-3 pN1-2			45 Gy + boost 45%		↑ OS aRT 5 yr. 64% vs. 53%	NCDB
Tang 2017 [277]	92	N3 +pelvis	40		63% 50/25, 13% > 50 Gy		↑ OS aRT 12.2 vs.8 P=0.04 ↑ DSS 14.4 vs.8 p = 0.02	4 centres
Ager 2021 [276]	146	pN3 (ENE or pelvis+)	121		45/20 to 54/25 2X↑LR if < 50	26 inF	OS 44% RFS 5y 51%	2 centres UK
Bandini 2021 [34]	507	ILND	86 HPV+ 40 aRT				↑ OS aRT p = 0.015 Also propensity matched analysis	11 centres

Adj = adjuvant; aRT = adjuvant radiotherapy; CT = chemotherapy; ENE = extra-nodal extension; HPV = human papillomavirus; ILND = inguinal lymph node dissection; mo = month; n = number of patients; NCDB = National Cancer Database; OS = overall survival; RFS = recurrence free survival; yr = year.

HPV status could be a suitable selection factor for patients who will benefit from adjuvant radiotherapy after ILND (in analogy to other HPV-related cancers). Bandini *et al.*, reported on 507 patients from 11 centres, 86 of whom were HPV+. Among patients receiving adjuvant radiotherapy, those harbouring HPV-positive tumours appeared to have an increased OS relative to HPV-negative patients. However, more (prospective) studies are needed to validate these findings [34].

As in other SCC sites such as head and neck cancer, HPV status may also predict for increased responsiveness to combined chemo-radiotherapy. Yuan *et al.*, reported improved loco-regional control (LRC) of 83% over 38% (p = 0.038) for node-positive p16+ patients receiving chemo-radiotherapy following LND [273]. Twenty-eight of 51 patients were LN+, of whom 14 received chemo-radiotherapy, 7 of whom were HPV-positive. Overall, regardless of HPV status, 2-year LRC was 54% for those receiving adjuvant chemo-radiotherapy vs. 13% (p = 0.006). Choo *et al.*, found similar efficacy of adjuvant chemo-radiotherapy with improved CSS at one and 2 years, even though the patients selected for adjuvant chemo-radiotherapy had a higher number of positive LNs (64% > 5 vs. 8%),

more pN3 disease (72% vs. 17%) and more ENE (45% vs. 17%) [281]. The OS was the same for the unfavourable group receiving adjuvant chemo-radiotherapy as it was for the more favourable earlier-stage patients not receiving chemo-radiotherapy.

Although PLND is recommended for patients with high-risk groin pathology (N2–N3), this is not the practice in all jurisdictions. Maibom *et al.*, reported from Denmark on the use of inguinal-pelvic chemo-radiotherapy for 21 patients with a median follow-up of 74 months [282]. All patients had ENE and two-thirds had bilateral groin disease, with a median OS of 84 months and 57% 5-year survival. This concept is being tested in the currently accruing InPACT trial where men with high-risk groin pathology can be randomised to chemo-radiotherapy or PLND followed by chemo-radiotherapy [260].

6.4.2.3 Summary of evidence and guidelines for pre- and post-operative radiotherapy

Summary of evidence	LE
Adjuvant radiotherapy results in increased OS if greater than two inguinal LN-positive and PLND-dissection negative.	2b
Adjuvant conventional radiotherapy doses are often insufficient for durable control. Increased DSS and RFS in penile cancer requires 54 Gy for ENE and 57–60 Gy for positive margins.	3
Peri-operative chemo-radiotherapy	
chemo-radiotherapy significantly improves loco-regional control over radiotherapy alone for other SCC originating in anal canal or head and neck, whilst in vulvar cancers it improves OS. The evidence is, however, sparse in penile cancer.	1b

Recommendations	Strength rating
Offer adjuvant radiotherapy (with or without chemo sensitisation) to patients with pN2/N3 disease, including those who received prior neoadjuvant chemotherapy.	Weak
Offer definitive radiotherapy (with or without chemo sensitisation) to patients unwilling or unable to undergo surgery.	Weak
Offer radiotherapy (with or without chemo sensitisation) to cN3 patients who are not candidates for multi-agent chemotherapy.	Weak

6.5 Systemic and palliative therapies for advanced disease

6.5.1 Introduction

Much of our current standard of care for this rare disease has evolved based upon extrapolated experience with similar cancers. The most common regimens utilized today for advanced disease are similar to those routinely used in the peri-operative setting, consisting of platinum-based regimens. Most data come from institutional or retrospective studies, but cooperative groups have occasionally studied this disease via prospective phase II studies.

6.5.2 Chemotherapy

Phase II cooperative group studies with bleomycin, methotrexate, and cisplatin (BMP) and irinotecan cisplatin yielded response rates of 31–33% [186, 283]. The median OS for BMP was 28 weeks. Toxicity was a concern with both regimens, especially pulmonary toxicity from bleomycin.

A retrospective study of cisplatin and 5-FU (PF) presented a response rate of 32% and median OS of 8 months. Toxicity was manageable for this patient population [284].

Addition of taxanes to cisplatin-based regimens was associated with promising activity including CRs. Docetaxel, cisplatin, and fluorouracil (TPF) was prospectively studied in a cohort with distant metastasis (28%) or locally-advanced disease (72%). The response rate was 38.5% and median OS of 14 months; there were 2/26 patients with CR [184]. The study did not meet its efficacy endpoint and toxicity of TPF was a concern. Another prospective study of TPF in exclusively metastatic (M1) disease showed an objective response rate of 38.5% and median OS of 7 months [285]. The latter study did meet its efficacy endpoint and toxicity was interpreted as acceptable.

Paclitaxel, ifosfamide and cisplatin (TIP) was prospectively studied in patients with metastases confined to LNs (N2–3, M0), having a response rate of 50% in this select population and 3/30 with surgically verified CRs [180]. Toxicity was manageable in this setting, but there are limited data available for TIP in distant metastatic disease.

A SR of cisplatin-based chemotherapy outcomes with and without taxanes suggested a higher toxicity rate with taxanes, 49% vs. 26% [187].

Vinflunine single-agent chemotherapy was prospectively studied in patients with advanced disease who were not eligible for curative surgery or NAC. Patients were required to have ECOG performance status ≤ 2 and estimated glomerular filtration rate (GFR) ≥ 60 mL/min. Median age was 70 years with a 27% response rate and median OS of 8.4 months. Toxicity was manageable.

A retrospective study of paclitaxel single-agent chemotherapy as second line reported a response rate of 20% and median OS 23 weeks [286]. Two studies of various second-line systemic therapy regimens found median OS of 4.5 – 5.6 months [287, 288].

A retrospective study of 101 patients looked at the efficacy of chemotherapy as first-, second- and third-line treatment [287]. The median OS for first-line chemotherapy was 7.2 months and with best supportive care, two months. The second-line regimens in seventeen patients included paclitaxel/carboplatin (41%), cisplatin/capecitabine (12%), paclitaxel (12%), or other (36%). There were two objective responses (12%), three stable disease (18%) and seventeen with progressive disease (71%) as best response. Paclitaxel/carboplatin was also reported in adjuvant and neoadjuvant case series and was well tolerated [289, 290].

These data support the recommendation of platinum-based chemotherapy as the preferred approach to first-line palliative systemic therapy. Choices include triplet regimens (TPF, TIP) and doublets (PF, paclitaxel/carboplatin), where doublets appear to have less toxicity. Both TPF and TIP combine two neurotoxic drugs and are not appropriate for patients with pre-existing neuropathy or low GFR. Other comorbidities and functional status should be carefully considered when selecting a regimen. While data for paclitaxel/carboplatin in advanced penile cancer are limited, it is reasonable to extrapolate from its use as palliative treatment of squamous-cell cancers from other sites. An alternative approach is single-agent chemotherapy with vinflunine or a taxane.

Effective second-line palliative chemotherapy regimens are lacking. Second-line chemotherapy in multiple studies was associated with median OS of 6 months or less. This is an unmet need that also applies to patients with tumour recurrence after adjuvant or neoadjuvant chemotherapy.

6.5.2.1 *Immunotherapy*

Immune-based therapies such as immune-checkpoint blockade, HPV-directed vaccines and adoptive T-cell therapies have emerged as potential treatment options for advanced penile cancer [291]. Given the relatively high expression of PD-L1 in penile SCC, several trials in progress assess checkpoint inhibition in advanced disease. None of these anti-PD(L)1 monotherapy trials has been published thus far. Trials presented at conferences reported response rates of 14–17% [292, 293].

Basket studies testing combination therapies have included penile SCC patients. In a phase I-II study of nivolumab combined with cabozantinib, with or without ipilimumab, 3 penile SCC patients were included: one partial response (PR) and 2 stable diseases (SD) were reported [294]. In another study testing the combination of ipilimumab and nivolumab, 5 penile SCC were included reporting 2 patients having SD [295]. In general, inclusion of patients with advanced penile SCC after chemotherapy exposure into early-phase basket trials is highly recommended.

6.5.2.2 *Targeted therapies*

Beyond chemotherapy, currently limited additional systemic options exist. Specific actionable genetic alterations appear rare in this disease. Targeted therapy against epidermal growth factor receptor (EGFR) has been tested, similar to SCCs originating from other anatomical regions.

Evidence of sporadic activity of several EGFR inhibitors have been reported from a few small clinical studies or case-series [296–298]. Dacomitinib, an orally-available pan-HER inhibitor, was tested as monotherapy in a phase II study including patients with locally-advanced and distant metastatic penile SCC. Twenty-eight patients were included in this study, and the ORR was 32.1% with one patient benefiting with a complete response [299].

Despite PIK3CA gene alterations have been reported as the most frequently identified potentially 'actionable' genomic alterations in SCC of the pelvic region, no data currently support the use of selected targeted agents in this disease [300].

6.5.3 **Role of radiotherapy in palliation**

Radiotherapy is frequently necessary for palliation of penile cancer and should be customized for unique presentations as necessary: e.g., ulcerative fixed LNs or dermal lymphatic spread. While standard palliative regimens should be readily employed, providers should be aware that re-treatment may be necessary for durable disease control [301]. This radio-resistance in some cases has been noted [178].

With respect to chemoradiotherapy for large/inoperable primary tumors, large palpable nodes, or pelvic nodal involvement, a Dutch prospective trial of 33 patients (median age 64: IQR 54-73) was recently released [351]. A response rate of 73% and a complete response rate of 39% (evaluated by FDG-PET/CT) was noted after mitomycin C + capecitabine chemotherapy and 49.5-59.4Gy radiation. The 2-year overall survival was 46% and salvage surgery was feasible if required. Importantly, treatment toxicity was low compared to neoadjuvant chemotherapy (followed by surgery) [351].

6.5.4 **Summary of evidence and guidelines for systemic and palliative therapies for advanced penile cancer**

Summary of evidence	LE
Low-level data support the use of platinum-based chemotherapy as first-line systemic therapy in advanced disease.	3
Effective second-line palliative chemotherapy regimens are lacking. Second-line chemotherapy in multiple studies was associated with median OS of six months or less.	3
Initial phase II or basket studies assessed anti-EGFR therapy or checkpoint inhibition, as monotherapy or combination therapy, in advanced disease. Early evidence of promising clinical activity has been reported in patients with penile cancer.	2b

Recommendations	Strength rating
Systemic therapies	
Offer patients with distant metastatic disease, platinum-based chemotherapy as the preferred approach to first-line palliative systemic therapy.	Weak
Do not offer bleomycin because of the pulmonary toxicity risk.	Strong
Offer patients with progressive disease under platinum chemotherapy the opportunity to enroll in clinical trials, including experimental therapies within phase I or basket trials.	Strong
Radiotherapy	
Offer radiotherapy for symptom control (palliation) in advanced disease.	Strong

7. FOLLOW-UP AND QUALITY OF LIFE

7.1 **Unmet needs**

Penile cancer has a significant impact on QoL and unfortunately there remain many unmet needs to address (see Table 1.1 in Chapter 1) [2]. The physical changes, along with the psychological and emotional stress that men with penile cancer suffer requires recognition and professional support before, during and after treatment. Holistic patient support services delivered by a multi-disciplinary team as a routine part of surveillance and follow-up should be standard of care. Patients with cancer endorse of the need for 'adjustment' and dealing with the 'new normal' as part of survivorship [302]. The extent of this and the time it takes varies from person to person and it is important to realise that some unmet needs may not become an issue until much later on.

7.2 **Rationale for follow-up**

From an oncological perspective, surveillance is important as early detection of recurrence may increase the likelihood of curative treatment. Some studies suggest local recurrence does not significantly reduce long-term survival if successfully treated [147, 303]. However, a recent multi-centre study reported an increased risk of recurrence following glanssectomy in men with more aggressive disease (T3 and/or high grade), which in turn resulted in poorer OS and CSS [145]. Disease that has spread to the inguinal LNs greatly reduces the rate of long-term CSS. Follow-up is also important for survivorship, allowing for the detection and management of the physical and psychological impact of treatments. The use of Patient Reported Outcome Measures (PROMS)

related to body image (Male Genital Self-Image Scale MGSIS-5) and lymphoedema (Groin and Lower Limb lymphoedema questionnaire G3L-20) have been proposed as tools to help patients and their healthcare team raise and discuss embarrassing topics during consultations [304].

Local or regional nodal recurrences usually occur within two to three years of primary treatment [147, 305, 306]. A recent study of 509 patients reported 52.3% of local recurrences occurred within two years and 79.5% within three years [306]. Fewer than 5% of regional or distant recurrences occur after two years, with the majority occurring within the first year after treatment [305, 306]. After five years, all recurrences were either local or new primary lesions [147]. This supports an intensive follow-up regimen during the first two years, with a less intensive follow-up later for a total of at least five years. Follow-up after five years may be omitted in motivated patients who will undertake regular self-examination reliably [147].

7.2.1 **When and how to follow-up**

After local treatment with negative inguinal nodes, follow-up should include physical examination of the penis and groins for local and/or regional recurrence. Additional imaging has no proven benefit. Follow-up also depends on the primary treatment modality. Histology from the glans should be obtained to confirm disease-free status following laser ablation or topical chemotherapy. After potentially curative treatment for inguinal nodal metastases, CT or MRI imaging for the detection of systemic disease (imaging of thorax, abdomen and pelvis) should be performed at 3-monthly intervals for the first two years. Following this, the frequency is usually reduced to 6-monthly for a total of 5 years of follow-up. However, one study of 224 node-positive patients reported only two recurrences in years 3–5 of follow-up, and both of these were pN3 patients [305]. Although rare, late local recurrence may occur. Therefore, regular follow-up can be stopped after 5 years, provided the patient understands the need to report any local changes immediately [98]. In patients unlikely to self-examine, long-term follow-up may be necessary (Table 7.1).

7.2.2 **Recurrence of the primary tumour**

Local recurrence is more likely with all types of local organ-sparing treatment. Until recently it was not believed to influence the CSS rate, although one study recently challenged this showing a reduction in OS and CSS following local recurrence after glansectomy [145]. Large series of glansectomies have reported local recurrence rates around 10% [145, 307], although others have reported recurrence in up to 27% of patients treated with penis-preserving modalities, usually occurring within the first two years [146]. After partial penectomy, the risk of local recurrence is about 4–5% [146, 147, 303]. Local recurrence is easily detected by physical examination, by the patient himself or his physician. Patient education is an essential part of follow-up, and the patient should be urged to visit a specialist if any changes are seen.

7.2.3 **Regional recurrence**

Most regional recurrences occur during the first two years after treatment, irrespective of whether surveillance or invasive nodal staging were used. Although unlikely, regional recurrence can occur later than two years after treatment. It is therefore advisable to continue follow up in these patients [98]. The highest rate of regional recurrence (9%) occurs in patients managed by surveillance, while the lowest is in patients who have undergone invasive nodal staging by modified ILND or DSNB and whose LNs were negative (2.3%). The use of US and FNAC in suspicious cases has improved the early detection rate of regional recurrence [106, 107, 308]. Patients who have had surgery for LN metastases without adjuvant treatment have an increased risk of regional recurrence of 19% [147]. Regional recurrence requires timely treatment by rILND with (neo)adjuvant chemotherapy/chemoradiotherapy.

Table 7.1: Follow-up regime for penile cancer

	Interval of surveillance		Examinations and investigations	Minimum duration of follow-up
	Years 1–2	Years 3–5		
Recommendations for follow-up of the primary tumour				
Penile-preserving treatment	3-monthly	6-monthly	Regular physician or self-examination. Repeat biopsy after topical or laser treatment for PeIN (optional).	5 years
Amputation	3-monthly	Annually	Regular physician or self-examination.	5 years
Recommendations for follow-up of the inguinal lymph nodes				
Surveillance	3-monthly	6-monthly	Regular physician or self-examination. US ± FNAC optional.	5 years
pN0	3-monthly	Annually	Regular physician or self-examination. US ± FNAC optional.	5 years

pN+	3-monthly	6-monthly	Regular physician or self-examination. US ± FNAC, CT chest/abdomen/pelvis or ¹⁸ F-DG-PET/CT optional.	5 years
-----	-----------	-----------	--	---------

CT = computed tomography; ¹⁸F-DG = ¹⁸F-fluoro-2-deoxy-D-glucose; FNAC = fine needle aspiration cytology; PET = positron emission tomography; US = ultrasound.

7.3 Patient support services

Surveillance is not just about assessing for recurrent disease and men may require more frequent appointments than suggested above, with different members of the multi-disciplinary team to deliver patient support services and address QoL challenges. In fact, the latter starts at the first pre-operative consultation, where a needs assessment can identify areas that will be individually more challenging for that patient, be it physical, psychological, emotional, social or financial. Many men with penile cancer reflect that whilst the knowledge of potential functional and psychological impacts of treatment would not have stopped them proceeding with it, they wish they had a better understanding before embarking on the surgery. Pre-habilitation programmes can also help with this. Recently a qualitative study highlighted that men with penile cancer would appreciate more focus on the following themes: “early signs and seeking help”, “disclosure of a personal cancer” and “urological (dys)function” [309].

Unfortunately, not all men survive penile cancer and some present with, or recur with, advanced disease, some with extremely challenging symptoms to manage, including pain, odour and discharge. In addition to medical treatments outlined in other parts of these guidelines, early involvement of palliative care services for symptom control can make a huge difference to these patients.

7.3.1 Psychological support

Access to psychological support, counselling and psychosexual therapy are critical components of a holistic and multi-disciplinary survivorship service. Men will often think “why me?” and need help to process their thoughts and try to adjust to their changing situation. Areas for discussion might include identity and self-esteem (lifestyle and role adjustments), being a perceived burden, illness beliefs and perceptions, levels of social support, relationship quality and intimacy, body and self-image and concerns around mortality. Despite these significant psychological challenges, the rate of suicide, based on the SEER database (1973–2013) is amongst the lowest of all urological malignancies; 13 out of 6,155 men [310].

7.3.2 Quality of life

There is very little data on QoL after treatment for penile cancer. In particular, there is heterogeneity of the psychometric tools used to assess QoL outcomes and further research is needed to develop disease-specific PROMS for penile cancer. Some validated questionnaires have been used but none of them were validated in men with penile cancer. Tools used include LYMQOL (lymphoedema) [311], IIEF (erectile dysfunction) [312], SF-36 [313], European Organization for Research and Treatment of Cancer [EORTC] QLQ-C30 [314], Quality of Life Questionnaire-Penile Cancer-Rostock (HRO-PE29) [315], Hospital Anxiety and Depression Scale [316], EQ-5D (Euro QoL tool), Bigelow’s questionnaire [317], Male Genital Self-Image Scale MGSIS-5 and Groin and Lower Limb lymphoedema questionnaire G3L-20 [318].

Not surprisingly, published studies and discussions with patient groups demonstrate that penile cancer and its treatments have a significant impact on overall QoL, both physical and psychological. However, there is discrepancy in the literature as to whether partial penectomy impacts QoL more than penile-preserving surgical techniques, as discussed below. Erectile dysfunction, reduced frequency of sexual intercourse and reduced satisfaction with intercourse are reported in some studies [319, 320]. Urinary spraying [321] is another potential significant consequence of penile cancer surgery. Significant anxiety (31%) and depression (6%) has also been reported [322].

A German study reported on 76 patients following primary penile surgery. They reported a global QoL score well below the national average for age-standardised German patients, with voiding, sexuality, body image, lymphoedema all reported as areas of concern [315].

A Dutch study, where 90 patients returned their questionnaires (a return rate of 62%) orgasm, appearance concerns, life interference and urinary function were all significantly poorer following partial penectomy compared with a penile-preserving approach. In the same study, LND had a significant impact on life interference. Interestingly, when compared to an age and gender matched normative sample from the general population the patients reported better outcomes for the SF-36 physical domain and bodily pain sub scale [321].

A recent SR [3] reported on post-treatment QoL from 10 studies involving 346 men [157, 176, 315, 321, 323-328]. Two studies evaluated QoL as the primary endpoint and compared the outcomes among various treatment modalities [323, 327]. One of these studies used EORTC QLQ C-30 and reported on the QoL of men after penile cancer management with different treatment modalities. They observed that the treatment itself was not related to overall wellbeing or to social contact and activity. However, half of the individuals had psychological symptoms at follow-up [327]. In contrast, a retrospective study of men who underwent penile-preserving surgery reported a significant impact of surgery in every domain of EORTC QLQ-C30 questionnaire [315].

Another study used Bigelow's questionnaire and compared the post-operative QoL score to that at two weeks before surgery [328]. It reported that the scores relating to unpleasant feeling, sexual pleasure and familial/partner relations improved significantly ($p < 0.01$) whereas the domains relating to friend relationships and professional quality were unchanged.

Two non-randomised comparative studies used EORTC QLQ-C30 to assess QoL after penile preserving surgery or amputative surgery [323, 324]. The first trial on 51 men reported a statistically significant negative correlation between aggressiveness of surgery and global health status and physical functioning [323]. Whereas the other reported no significant differences between penile-preserving surgery or partial penectomy in functional scale, symptom scale and in the global health status [324]. A comparison between glans resurfacing, glansctomy and partial penectomy using the EQ-5D tool showed no difference between groups with comparable health status scores of 82.5, 85.0 and 87.5 respectively [157].

Another non-randomised comparative study also compared penile-preserving surgery to partial penectomy and reported no difference in QoL using the SF-36 scores [321]. Those who underwent amputative surgery had significantly more appearance concerns ($p = 0.008$) and they reported more life interference ($p = 0.032$) depending on the degree of disfigurement caused by the procedure.

7.3.3 **Urinary function**

Urinary function is an important topic to discuss with men before penile cancer treatment. Some will already be experiencing difficulty voiding due to their tumour causing urethral obstruction and many report they sit down to pass urine due to the spraying caused by the tumour. As a result, some report improved function following surgery, often in terms of flow but spraying and needing to sit down to void or use a funnel/bottle can be debilitating for many men.

Urinary function has been objectively assessed in only a few studies. Two case series reported improvement in post-operative urinary function and high satisfaction after penile surgery [326, 329]. Two non-randomised comparative studies reported no difference in urination between penile-preserving surgery or amputation. One demonstrated similar maximum flow rates following surgery (19.5 mL/s vs. 20.8 mL/s) [324] the other reported that urinary function was comparable across the study groups (glans resurfacing, glansctomy and partial penectomy) using the ICIQ-MLUTS score [157]. However, a different study found that urine spraying is more common after partial penectomy as compared to penile-preserving surgery (83% vs. 43%) [321]. Two case series reported no significant changes in urinary function following brachytherapy [166, 176]. A single trial on Moh's micrographic surgery, reported no post-treatment change (66% response rate) [330].

7.3.4 **Sexual function**

Sexual and erectile function after penile cancer varies between studies and between treatments. Generally, penile-preserving surgery preserves erectile function, although glans sensation and orgasm can be affected. Overall, partial penectomy is associated with poorer sexual outcomes.

A recent SR [3] reported on the sexual and erectile function from 27 studies that involve 991 men. The 5- or 15-question International Index of Erectile Function (IIEF) scores were used by most studies. Other tools used were the Erectile Dysfunction Inventory of treatment satisfaction score (EDITS), the index of male genitalia image (IM-GI), the Life Satisfaction of sexual life, the SELF-Esteem and Relationship (SEAR) or a combination of tools to assess overall sexual function [176, 324, 325, 327, 331]. It is important to acknowledge that only a few studies assessed baseline function and are therefore able to report the difference between pre- and post-treatment. Most studies reported only the post-treatment scores or the mean difference for retrospectively completed pre-treatment scores.

Three non-randomised comparative studies and one case series assessed the impact of penile-preserving surgery vs. amputation on sexual function of 202 men [321, 324, 327, 332]. Two studies that used the 15-question IIEF questionnaire reported significant post-treatment changes in the orgasmic function domain in favour of penile-preserving surgery ($p = 0.033$ and $p = 0.033$) while the other domains remain comparable between the treatment arms [321, 324]. However, in other studies using the 5-question IIEF score, no difference was identified between treatments [157, 332]. An older study that compared the impact of penile-preserving surgery, amputative surgery and radiotherapy on sexual function reported that those treated with amputation had worst sexual outcome [327]. Three trials retrospectively compared penile-preserving surgery techniques using IIEF questionnaire [326, 333, 334]. Wide local excision was superior to glanssectomy in all IIEF domains [333]. The impact of primary closure versus preputial flap reconstruction after glans-preserving surgery was similar as seen by IIEF results at 6 months or by rigid-scan parameters [334]. Partial glanssectomy was not superior to total glanssectomy [326].

Cohort studies have reported similar findings on sexual function. Five studies on patients who underwent penile-preserving surgery and reconstruction reported that 85–100% of men were able to achieve erection and maintain their sexual function [158, 335-338]. However, all patients reported reduced glans sensitivity. Following glans resurfacing for penile cancer ($n = 21$) or lichen sclerosis ($n = 16$) one study reported no significant change in urinary or sexual function (using IPPS and IIEF questionnaires) with glans sensitivity preserved in 89.2% of men [339].

Four studies on 167 men who have had partial penectomy reported significant changes in 15-question IIEF score with negative impact in every domain [319, 329, 331, 340]. A single trial reported that 61.7% of men after partial penectomy report erectile dysfunction [340]. However, a study from Brazil, assessing 14 patients following partial penectomy, found that for 64% overall sexual function was normal or slightly decreased and frequency of sexual intercourse was unchanged or slightly decreased [320].

The sexual function after brachytherapy has been assessed in five cohort studies [162, 166, 176, 341, 342]. Among men who were sexually active before treatment, 58.8–70.0% remain sexually active after treatment [162, 176]. Potency was maintained in 81.5–100% of men [162, 166, 176, 341, 342]. Altered glans sensitivity is reported in 52.6% [162].

Three studies assessed sexual function after laser treatment [155, 325, 343] and 46–56.5% of men report an impact of treatment on their sexual life [325, 343]. A single trial on 46 men found that 72% reported no change in erectile function, 22% reported decreased erectile function and 6% reported improvement [155].

One trial on patients who underwent Moh's micrographic surgery reported no change in sexual function after treatment (57.5% response rate) [330].

7.3.5 **Lymphoedema**

Lymphoedema significantly impacted functional domains in one study of patients 25 months following penile cancer nodal surgical treatment with inguinal and PLND having a much higher impact than ILND alone. Patients who had inguinal and PLND also had a much poorer mood score (38% vs. 0%) [344]. Due to the significant morbidity associated with ILND, many patients are not offered the operation or choose not to have it. An analysis of the US SEER database reported that only 233 out of 943 nonmetastatic penile cancer patients (24.7%) had ILND between 1998 and 2015 [223]. This did not change over time. A similar proportion of men, 606 out of 2224 (27.2%) underwent the surgery between 2004 and 2014 as recorded by the National Cancer Database [345].

Men should be assessed for genital and lower limb lymphoedema at each outpatient clinic appointment, advised about good skin care, compression, exercise, massage, and elevation when resting as the mainstay of treatment. Following nodal surgery, ideally, they would be referred to specialist lymphoedema services for assessment and management before any significant lymphoedema occurs.

Specialist lymphoedema services offer a range of made-to-measure compression garments or multi-layer lymphoedema bandaging for lower limb and genital lymphoedema. The latter not only compress the scrotal lymphoedema but also aim to lift it to aid drainage. For lower limb compression adjustable Velcro garments also exist. Good skin care is critical to prevent infection that can damage remaining lymphatic channels. Prophylactic antibiotics should be used following any episode of cellulitis, with penicillin V, erythromycin or clindamycin recommended, except in genital lymphoedema where prophylactic trimethoprim can be used [346].

Manual lymphatic drainage in the form of specialised massage techniques also helps to alleviate lymphoedema and encourages drainage. Following penile cancer treatments this is commonly used for stubborn moles and lower abdominal swelling and thickening of the scrotum and penile shaft.

Whilst regular exercise may temporarily increase lymphoedema due to the effect of gravity, it has an overall beneficial effect on lymphoedema by reducing abdominal fat (fat drains via lymphatic channels too) and using natural muscle pumps and changes in thoracic pressure to help lymphatic drainage. Strength training and stretching exercises to promote flexibility are also important.

Debulking surgery with scrotal reduction and penile shaft skin grafting can significantly improve issues related to significant genital lymphoedema. There is limited evidence for the benefit of other surgical interventions such as limb liposuction followed by compression and lymphatico-venous anastomosis in penile cancer although some evidence does exist for extremity lymphoedema due to various causes [347].

7.4 Centralisation of penile cancer services

Current large volume centres offer specialist nursing support, psychological support and specialised lymphoedema services to their patients. However, even in centralised healthcare systems, such as the UK, services vary and are not always available.

Centralisation of penile cancer services has a number of advantages in addition to delivering these important supportive services to patients (Table 7.2) [348]. These include provision of an environment where multi-disciplinary discussion of cases can occur along with specialist pathological review, and delivery of high volume penile-preserving and nodal surgery which can lead to innovation, such as closer surgical margins [151], more accurate DSNB and minimally-invasive surgery. In the UK, around 80% of penile cancers are treated with penile-preserving surgery. Centralisation can also reduce system delays [349] and result in better adherence to guidelines. In addition, patients should be able to access a larger team of specialists, including psychological and lymphoedema survivorship services. Centralisation of penile cancer services also creates opportunities for research and running clinical trials with a larger number of patients in a rare disease.

Disadvantages of centralisation include de-skilling of medical teams not involved with regularly looking after penile cancer and making patients travel long distances for treatment. This can be a significant financial burden, especially as many are in a lower socio-economic group. However, the recent increase in virtual healthcare and video consultation may reduce this burden, as does the provision of outreach clinics and services. In addition, educational sessions within cancer networks, can help keep local teams up-to-date, enabling them to help support the patient when back at home (Table 7.2).

In one hospital in the UK, 5-year CSS rates were observed to improve by up to 12% to 85% following centralisation, which is likely to be due to several factors, including the impact of early and complete pathological LN staging, regular multi-disciplinary patient reviews and use of adjuvant chemotherapy and chemo-radiotherapy in most patients where indicated [350].

Table 7.2: Advantages and disadvantages of centralisation

Advantages	Disadvantages
Multi-disciplinary team and holistic approach to penile cancer care	De-skilling of urologists and their teams
Opportunities for research, clinical trials and innovation	Distance patients need to travel
Improved survival	Financial burden of travel
High rates of penile-preserving surgery	Lack of local support for patients
High rates of surgical nodal staging	
Specialist lymphoedema services	
Specialist uro-radiology/nuclear medicine	
Specialist pathology reporting/review	
Psychological support	
Adherence to guidelines	
Clear referral pathway/reduced system delays	

7.5 Summary of evidence and guidelines for follow-up and quality of life

Summary of evidence	LE
Follow-up surveillance is important as early detection of recurrence may increase the likelihood of curative treatment.	3
Local or regional nodal recurrences usually occur within two years of primary treatment.	3
Penile cancer has a significant impact on QoL in many ways and there remain many unmet needs to address.	4
There is very little data on QoL after treatment for penile cancer. In particular, there is heterogeneity of the psychometric tools used to assess QoL outcomes and further research is needed to develop disease-specific PROMS for penile cancer.	3
Generally, penile-preserving surgery preserves erectile function, although glans sensation and orgasm can be affected. Overall, partial penectomy is associated with poorer sexual outcomes.	2b
Access to psychological support, counselling and psychosexual therapy are critical components of a holistic and multi-disciplinary patient support service.	4
Ideally, following nodal surgery, patients would be referred to specialist lymphoedema services for assessment and management before any significant lymphoedema occurs.	4
In one UK specialist penile cancer centre (referral population approximately 11 million), 5-year CSS rates were observed to improve by up to 12-85% following centralisation.	3

Recommendations	Strength rating
Deliver penile cancer care as part of an extended multi-disciplinary team comprising of urologists specialising in penile cancer, specialist nurses, pathologists, uro-radiologists, nuclear medicine specialists, medical and radiation oncologists, lymphoedema therapists, psychologists, counsellors, palliative care teams for early symptom control, reconstructive surgeons, vascular surgeons, sex therapists.	Strong
Follow-up men after penile cancer treatment, initially 3-monthly for two years then less frequently to assess for recurrent disease and to offer patient support services through the extended multi-disciplinary team. At discharge, recommend self-examination with easy access back to the clinic as local recurrence can occur late.	Strong
Discuss the psychological impact of penile cancer and its treatments with the patient and offer psychological support and counselling services.	Strong
Discuss the negative impact of treatments for the primary tumour on penile appearance, sensation, urinary and sexual function so that the patient is better prepared for the challenges he may face.	Strong
Discuss the potential impact of lymphoedema as a consequence of inguinal and pelvic lymph node treatment with the patient and assess patients for it at follow-up and refer to lymphoedema therapists early.	Strong

8. REFERENCES

1. World Health Organization. Website. Access date January 2023.
<https://www.who.int/health-topics/palliative-care>
2. Paterson, C., *et al.* What are the unmet supportive care needs of men affected by penile cancer? A systematic review of the empirical evidence. *Eur J Oncol Nurs*, 2020. 48: 101805.
<https://pubmed.ncbi.nlm.nih.gov/32947156/>
3. Sakalis, V.I., *et al.* What Is the Most Effective Management of the Primary Tumor in Men with Invasive Penile Cancer: A Systematic Review of the Available Treatment Options and Their Outcomes. *Eur Urol Open Sci*, 2022. 40: 58.
<https://pubmed.ncbi.nlm.nih.gov/35540709/>
4. Guyatt, G.H., *et al.* GRADE: an emerging consensus on rating quality of evidence and strength of recommendations. *BMJ*, 2008. 336: 924.
<https://pubmed.ncbi.nlm.nih.gov/18436948/>
5. Guyatt, G.H., *et al.* What is "quality of evidence" and why is it important to clinicians? *BMJ*, 2008. 336: 995.
<https://pubmed.ncbi.nlm.nih.gov/18456631/>
6. Phillips, B., *et al.* Oxford Centre for Evidence-based Medicine Levels of Evidence. Updated by Jeremy Howick March 2009, updated 1998. Access date January 2023.
<https://www.cebm.ox.ac.uk/resources/levels-of-evidence/oxford-centre-for-evidence-based-medicine-levels-of-evidence-march-2009>
7. Guyatt, G.H., *et al.* Going from evidence to recommendations. *BMJ*, 2008. 336: 1049.
<https://pubmed.ncbi.nlm.nih.gov/18467413/>
8. IARC, Urinary and Male Genital Tumours. WHO Classification of Tumours, 5th Edn. Vol. 8. 2022.
<https://publications.iarc.fr/Book-And-Report-Series/Who-Classification-Of-Tumours/Urinary-And-Male-Genital-Tumours-2022>
9. Sanchez, D.F., *et al.* Pathological factors, behavior, and histological prognostic risk groups in subtypes of penile squamous cell carcinomas (SCC). *Semin Diagn Pathol*, 2015. 32: 222.
<https://pubmed.ncbi.nlm.nih.gov/25677263/>
10. Thomas, A., *et al.* Penile cancer. *Nat Rev Dis Primers*, 2021. 7: 11.
<https://pubmed.ncbi.nlm.nih.gov/33574340/>
11. Fu, L., *et al.* Global Pattern and Trends in Penile Cancer Incidence: Population-Based Study. *JMIR Public Health Surveill*, 2022. 8: e34874.
<https://pubmed.ncbi.nlm.nih.gov/35793140/>
12. IARC, Cancer Today. 2020. Access date January 2023.
<https://gco.iarc.fr/today/home>
13. Parkin, D.M., *et al.* Chapter 2: The burden of HPV-related cancers. *Vaccine*, 2006. 24 Suppl 3: S3/11.
<https://pubmed.ncbi.nlm.nih.gov/16949997/>
14. Hansen, B.T., *et al.* Trends in incidence, mortality and survival of penile squamous cell carcinoma in Norway 1956-2015. *Int J Cancer*, 2018. 142: 1586.
<https://pubmed.ncbi.nlm.nih.gov/29205336/>
15. Cancer Research UK. Penile Cancer incidence trends over time. 2021. Access date January 2023.
<https://www.cancerresearchuk.org/health-professional/cancer-statistics/statistics-by-cancer-type/penile-cancer/incidence>
16. Daubisse-Marliac, L., *et al.* Long-term trends in incidence and survival of penile cancer in France. *Cancer Epidemiol*, 2017. 50: 125.
<https://pubmed.ncbi.nlm.nih.gov/28898817/>
17. Backes, D.M., *et al.* Systematic review of human papillomavirus prevalence in invasive penile cancer. *Cancer Causes Control*, 2009. 20: 449.
<https://pubmed.ncbi.nlm.nih.gov/19082746/>
18. Qi, F., *et al.* Incidence trends and survival outcomes of penile squamous cell carcinoma: evidence from the Surveillance, Epidemiology and End Results population-based data. *Ann Transl Med*, 2020. 8: 1428.
<https://pubmed.ncbi.nlm.nih.gov/33313173/>
19. Wenzel, M., *et al.* Temporal trends, tumor characteristics and stage-specific survival in penile non-squamous cell carcinoma vs. squamous cell carcinoma. *Cancer Causes Control*, 2022. 33: 25.
<https://pubmed.ncbi.nlm.nih.gov/34476653/>
20. Chau, A., *et al.* Epidemiologic profile, sexual history, pathologic features, and human papillomavirus status of 103 patients with penile carcinoma. *World J Urol*, 2013. 31: 861.
<https://pubmed.ncbi.nlm.nih.gov/22116602/>

21. Barnholtz-Sloan, J.S., *et al.* Incidence trends in primary malignant penile cancer. *Urol Oncol*, 2007. 25: 361.
<https://pubmed.ncbi.nlm.nih.gov/17826651/>
22. Hartwig, S., *et al.* Estimation of the epidemiological burden of human papillomavirus-related cancers and non-malignant diseases in men in Europe: a review. *BMC Cancer*, 2012. 12: 30.
<https://pubmed.ncbi.nlm.nih.gov/22260541/>
23. Olesen, T.B., *et al.* Prevalence of human papillomavirus DNA and p16(INK4a) in penile cancer and penile intraepithelial neoplasia: a systematic review and meta-analysis. *Lancet Oncol*, 2019. 20: 145.
<https://pubmed.ncbi.nlm.nih.gov/30573285/>
24. Xu, L., *et al.* Projected oropharyngeal carcinoma incidence among middle-aged US men. *Head Neck*, 2019. 41: 3226.
<https://pubmed.ncbi.nlm.nih.gov/31125167/>
25. IARC, 26-Penis Fact Sheet. 2020. Access date January 2023.
<https://gco.iarc.fr/today/data/factsheets/cancers/26-Penis-fact-sheet.pdf>
26. Douglawi, A., *et al.* Updates on the epidemiology and risk factors for penile cancer. *Transl Androl Urol*, 2017. 6: 785.
<https://pubmed.ncbi.nlm.nih.gov/29184774/>
27. Deng, X., *et al.* Trends in Incidence, Mortality, and Survival of Penile Cancer in the United States: A Population-Based Study. *Front Oncol*, 2022. 12: 891623.
<https://pubmed.ncbi.nlm.nih.gov/35785206/>
28. Lebelo, R.L., *et al.* Diversity of HPV types in cancerous and pre-cancerous penile lesions of South African men: implications for future HPV vaccination strategies. *J Med Virol*, 2014. 86: 257.
<https://pubmed.ncbi.nlm.nih.gov/24155172/>
29. Stankiewicz, E., *et al.* HPV infection and immunochemical detection of cell-cycle markers in verrucous carcinoma of the penis. *Mod Pathol*, 2009. 22: 1160.
<https://pubmed.ncbi.nlm.nih.gov/19465901/>
30. Kayes, O., *et al.* Molecular and genetic pathways in penile cancer. *Lancet Oncol*, 2007. 8: 420.
<https://pubmed.ncbi.nlm.nih.gov/17466899/>
31. Nordenvall, C., *et al.* Cancer risk among patients with condylomata acuminata. *Int J Cancer*, 2006. 119: 888.
<https://pubmed.ncbi.nlm.nih.gov/16557590/>
32. Lont, A.P., *et al.* Presence of high-risk human papillomavirus DNA in penile carcinoma predicts favorable outcome in survival. *Int J Cancer*, 2006. 119: 1078.
<https://pubmed.ncbi.nlm.nih.gov/16570278/>
33. Bezerra, A.L., *et al.* Human papillomavirus as a prognostic factor in carcinoma of the penis: analysis of 82 patients treated with amputation and bilateral lymphadenectomy. *Cancer*, 2001. 91: 2315.
<https://pubmed.ncbi.nlm.nih.gov/11413520/>
34. Bandini, M., *et al.* Association Between Human Papillomavirus Infection and Outcome of Perioperative Nodal Radiotherapy for Penile Carcinoma. *Eur Urol Oncol*, 2021. 4: 802.
<https://www.sciencedirect.com/science/article/abs/pii/S2588931120301760?via%3Dihub>
35. Hölter, S., *et al.* Challenging the prognostic impact of the new WHO and TNM classifications with special emphasis on HPV status in penile carcinoma. *Virchows Arch*, 2019. 475: 211.
<https://pubmed.ncbi.nlm.nih.gov/30972551/>
36. Sand, F.L., *et al.* Prognostic Significance of HPV and p16 Status in Men Diagnosed with Penile Cancer: A Systematic Review and Meta-analysis. *Cancer Epidemiol Biomarkers Prev*, 2018. 27: 1123.
<https://pubmed.ncbi.nlm.nih.gov/29987099/>
37. Liu, H., *et al.* Human papillomavirus as a favorable prognostic factor in a subset of head and neck squamous cell carcinomas: A meta-analysis. *J Med Virol*, 2017. 89: 710.
<https://pubmed.ncbi.nlm.nih.gov/27575972/>
38. Urbute, A., *et al.* Prognostic Significance of HPV DNA and p16(INK4a) in Anal Cancer: A Systematic Review and Meta-Analysis. *Cancer Epidemiol Biomarkers Prev*, 2020. 29: 703.
<https://pubmed.ncbi.nlm.nih.gov/32051192/>
39. Zhang, J., *et al.* Prognostic Significance of P16(INK4a) Expression in Penile Squamous Cell Carcinoma: A Meta-Analysis with Trial Sequential Analysis. *Biomed Res Int*, 2018. 2018: 8345893.
<https://pubmed.ncbi.nlm.nih.gov/30105253/>
40. Sand, F.L., *et al.* The prognostic value of p16 and p53 expression for survival after vulvar cancer: A systematic review and meta-analysis. *Gynecol Oncol*, 2019. 152: 208.
<https://pubmed.ncbi.nlm.nih.gov/30415992/>

41. Mirghani, H., *et al.* Is there an increased risk of cancer among spouses of patients with an HPV-related cancer: A systematic review. *Oral Oncol*, 2017. 67: 138.
<https://pubmed.ncbi.nlm.nih.gov/28351568/>
42. de Bruijn, R.E., *et al.* Patients with penile cancer and the risk of (pre)malignant cervical lesions in female partners: a retrospective cohort analysis. *BJU Int*, 2013. 112: 905.
<https://pubmed.ncbi.nlm.nih.gov/23905914/>
43. Zhang, J., *et al.* The efficacy of vaccination to prevent human papilloma viruses infection at anal and oral: a systematic review and meta-analysis. *Public Health*, 2021. 196: 165.
<https://pubmed.ncbi.nlm.nih.gov/34229128/>
44. Harder, T., *et al.* Efficacy, effectiveness and safety of vaccination against human papillomavirus in males: a systematic review. *BMC Med*, 2018. 16: 110.
<https://pubmed.ncbi.nlm.nih.gov/30016957/>
45. Elst, L., *et al.* HPV Vaccination: Does It Have a Role in Preventing Penile Cancer and Other Preneoplastic Lesions? *Semin Oncol Nurs*, 2022. 38: 151284.
<https://pubmed.ncbi.nlm.nih.gov/35577640/>
46. Tsen, H.F., *et al.* Risk factors for penile cancer: results of a population-based case-control study in Los Angeles County (United States). *Cancer Causes Control*, 2001. 12: 267.
<https://pubmed.ncbi.nlm.nih.gov/11405332/>
47. Koifman, L., *et al.* Epidemiological aspects of penile cancer in Rio de Janeiro: evaluation of 230 cases. *Int Braz J Urol*, 2011. 37: 231.
<https://pubmed.ncbi.nlm.nih.gov/21557840/>
48. Van Howe, R.S., *et al.* The carcinogenicity of smegma: debunking a myth. *J Eur Acad Dermatol Venereol*, 2006. 20: 1046.
<https://pubmed.ncbi.nlm.nih.gov/16987256/>
49. Daling, J.R., *et al.* Penile cancer: importance of circumcision, human papillomavirus and smoking in *in situ* and invasive disease. *Int J Cancer*, 2005. 116: 606.
<https://pubmed.ncbi.nlm.nih.gov/15825185/>
50. Velazquez, E.F., *et al.* Limitations in the interpretation of biopsies in patients with penile squamous cell carcinoma. *Int J Surg Pathol*, 2004. 12: 139.
<https://pubmed.ncbi.nlm.nih.gov/15173919/>
51. Velazquez, E.F., *et al.* Lichen sclerosus in 68 patients with squamous cell carcinoma of the penis: frequent atypias and correlation with special carcinoma variants suggests a precancerous role. *Am J Surg Pathol*, 2003. 27: 1448.
<https://pubmed.ncbi.nlm.nih.gov/14576478/>
52. Teichman, J.M., *et al.* Noninfectious penile lesions. *Am Fam Physician*, 2010. 81: 167.
<https://pubmed.ncbi.nlm.nih.gov/20082512/>
53. Renaud-Vilmer, C., *et al.* Analysis of alterations adjacent to invasive squamous cell carcinoma of the penis and their relationship with associated carcinoma. *J Am Acad Dermatol*, 2010. 62: 284.
<https://pubmed.ncbi.nlm.nih.gov/20115951/>
54. Moch, H., *et al.* The 2022 World Health Organization Classification of Tumours of the Urinary System and Male Genital Organs-Part A: Renal, Penile, and Testicular Tumours. *Eur Urol*, 2022. 82: 458.
<https://pubmed.ncbi.nlm.nih.gov/35853783/>
55. Chau, A., *et al.* Metastatic tumors to the penis: a report of 17 cases and review of the literature. *Int J Surg Pathol*, 2011. 19: 597.
<https://pubmed.ncbi.nlm.nih.gov/20075023/>
56. Ebel, J.J., *et al.* Whole-mount evaluation of penectomies for penile cancer: feasibility, cost and comparison to routine sectioning. *Histopathology*, 2013. 63: 64.
<https://pubmed.ncbi.nlm.nih.gov/23738630/>
57. Corbishley C., *et al.* Standards and datasets for reporting cancers Dataset for penile and distal urethral cancer histopathology reports. 2015. 2022.
<https://www.rcpath.org/uploads/assets/d0e70985-300e-4835-af4583df56025869/Dataset-for-penile-and-distal-urethral-cancer-histopathology-reports.pdf>
58. Tang, V., *et al.* Should centralized histopathological review in penile cancer be the global standard? *BJU Int*, 2014. 114: 340.
<https://pubmed.ncbi.nlm.nih.gov/24053106/>
59. Vanthoor, J., *et al.* Making surgery safer by centralization of care: impact of case load in penile cancer. *World J Urol*, 2020. 38: 1385.
<https://pubmed.ncbi.nlm.nih.gov/31292733/>

60. Aumayr, K., *et al.* P16INK4A immunohistochemistry for detection of human papilloma virus-associated penile squamous cell carcinoma is superior to in-situ hybridization. *Int J Immunopathol Pharmacol*, 2013. 26: 611.
<https://pubmed.ncbi.nlm.nih.gov/24067458/>
61. Bezerra, S.M., *et al.* Human papillomavirus infection and immunohistochemical p16(INK4a) expression as predictors of outcome in penile squamous cell carcinomas. *Hum Pathol*, 2015. 46: 532.
<https://pubmed.ncbi.nlm.nih.gov/25661481/>
62. Mannweiler, S., *et al.* Two major pathways of penile carcinogenesis: HPV-induced penile cancers overexpress p16ink4a, HPV-negative cancers associated with dermatoses express p53, but lack p16ink4a overexpression. *J Am Acad Dermatol*, 2013. 69: 73.
<https://pubmed.ncbi.nlm.nih.gov/23474228/>
63. Corbishley M., *et al.* Carcinoma of the Penis and Distal Urethra Histopathology Reporting Guide 1st edition. International Collaboration on Cancer Reporting; Sydney, Australia. ISBN: 978-1-925687-05-7. 2017.
<https://nla.gov.au/nla.obj-775927924/view>
64. Guimarães, G.C., *et al.* Front pattern of invasion in squamous cell carcinoma of the penis: new prognostic factor for predicting risk of lymph node metastases. *Urology*, 2006. 68: 148.
<https://pubmed.ncbi.nlm.nih.gov/16844455/>
65. Sanchez, D.F., *et al.* What Is New in the Pathologic Staging of Penile Carcinoma in the 8th Edition of AJCC TNM Model: Rationale for Changes With Practical Stage-by-stage Category Diagnostic Considerations. *Adv Anat Pathol*, 2021. 28: 209.
<https://pubmed.ncbi.nlm.nih.gov/34050061/>
66. Sali, A.P., *et al.* Histopathological risk scoring system as a tool for predicting lymph nodal metastasis in penile squamous cell carcinoma. *Pathology*, 2019. 51: 696.
<https://pubmed.ncbi.nlm.nih.gov/31635947/>
67. Winters, B.R., *et al.* Predictors of Nodal Upstaging in Clinical Node Negative Patients With Penile Carcinoma: A National Cancer Database Analysis. *Urology*, 2016. 96: 29.
<https://pubmed.ncbi.nlm.nih.gov/27450944/>
68. Feng, M.A., *et al.* Concordance of lymphovascular invasion diagnosed in penile carcinoma with and without the immunohistochemical markers ERG and CD31. *Histol Histopathol*, 2016. 31: 293.
<https://pubmed.ncbi.nlm.nih.gov/26452171/>
69. Dorofte, L., *et al.* Low level of interobserver concordance in assessing histological subtype and tumor grade in patients with penile cancer may impair patient care. *Virchows Arch*, 2022. 480: 879.
<https://pubmed.ncbi.nlm.nih.gov/34889977/>
70. Cubilla, A.L. The role of pathologic prognostic factors in squamous cell carcinoma of the penis. *World J Urol*, 2009. 27: 169.
<https://pubmed.ncbi.nlm.nih.gov/18766352/>
71. Zekan, D.S., *et al.* Prognostic predictors of lymph node metastasis in penile cancer: a systematic review. *Int Braz J Urol*, 2021. 47: 943.
<https://pubmed.ncbi.nlm.nih.gov/33650835/>
72. Fankhauser, C.D., *et al.* Lymphovascular and perineural invasion are risk factors for inguinal lymph node metastases in men with T1G2 penile cancer. *J Cancer Res Clin Oncol*, 2022. 148: 2231.
<https://pubmed.ncbi.nlm.nih.gov/35411405/>
73. Brierley, J., *et al.*, TNM Classification of Malignant Tumours, 8th Edn. 2016.
<https://www.uicc.org/resources/tnm-classification-malignant-tumours-8th-edition>
74. Li, Z., *et al.* Corpora Caverosa invasion vs. Corpus Spongiosum invasion in Penile Cancer: A systematic review and meta-analysis. *J Cancer*, 2021. 12: 1960.
<https://pubmed.ncbi.nlm.nih.gov/33753994/>
75. Sali, A.P., *et al.* A comparative study of AJCC and the modified staging system in pT2/pT3 penile squamous cell carcinoma - a validation on an external data set. *Histopathology*, 2022. 80: 566.
<https://pubmed.ncbi.nlm.nih.gov/34586682/>
76. Zhang, Z.L., *et al.* The importance of extranodal extension in penile cancer: a meta-analysis. *BMC Cancer*, 2015. 15: 815.
<https://pubmed.ncbi.nlm.nih.gov/26510975/>
77. Gunia, S., *et al.* Does the width of the surgical margin of safety or premalignant dermatoses at the negative surgical margin affect outcome in surgically treated penile cancer? *J Clin Pathol*, 2014. 67: 268.
<https://pubmed.ncbi.nlm.nih.gov/24100380/>

78. Wang, J.Y., *et al.* Prognostic significance of the degree of extranodal extension in patients with penile carcinoma. *Asian J Androl*, 2014. 16: 437.
<https://pubmed.ncbi.nlm.nih.gov/24480925/>
79. Chaux, A., *et al.* The prognostic index: a useful pathologic guide for prediction of nodal metastases and survival in penile squamous cell carcinoma. *Am J Surg Pathol*, 2009. 33: 1049.
<https://pubmed.ncbi.nlm.nih.gov/19384188/>
80. Zito Marino, F., *et al.* Discrepancy of p16 immunohistochemical expression and HPV RNA in penile cancer. A multiplex *in situ* hybridization/immunohistochemistry approach study. *Infect Agent Cancer*, 2021. 16: 22.
<https://pubmed.ncbi.nlm.nih.gov/33789689/>
81. Cubilla, A.L., *et al.* Value of p16(INK)⁴(a) in the pathology of invasive penile squamous cell carcinomas: A report of 202 cases. *Am J Surg Pathol*, 2011. 35: 253.
<https://pubmed.ncbi.nlm.nih.gov/21263246/>
82. Canete-Portillo, S., *et al.* Report From the International Society of Urological Pathology (ISUP) Consultation Conference on Molecular Pathology of Urogenital Cancers V: Recommendations on the Use of Immunohistochemical and Molecular Biomarkers in Penile Cancer. *Am J Surg Pathol*, 2020. 44: e80.
<https://pubmed.ncbi.nlm.nih.gov/32235153/>
83. Amin, M.B., *et al.* The Eighth Edition AJCC Cancer Staging Manual: Continuing to build a bridge from a population-based to a more “personalized” approach to cancer staging. *CA Cancer J Clin*, 2017. 67: 93.
<https://pubmed.ncbi.nlm.nih.gov/28094848/>
84. Velazquez, E.F., *et al.* Histologic grade and perineural invasion are more important than tumor thickness as predictor of nodal metastasis in penile squamous cell carcinoma invading 5 to 10 mm. *Am J Surg Pathol*, 2008. 32: 974.
<https://pubmed.ncbi.nlm.nih.gov/18460979/>
85. Leijte, J.A., *et al.* Evaluation of current TNM classification of penile carcinoma. *J Urol*, 2008. 180: 933.
<https://pubmed.ncbi.nlm.nih.gov/18635216/>
86. Sun, M., *et al.* Development and external validation of a prognostic tool for prediction of cancer-specific mortality after complete loco-regional pathological staging for squamous cell carcinoma of the penis. *BJU Int*, 2015. 116: 734.
<https://pubmed.ncbi.nlm.nih.gov/24552303/>
87. Li, Z.S., *et al.* Modification of N staging systems for penile cancer: a more precise prediction of prognosis. *Br J Cancer*, 2015. 113: 1746.
<https://pubmed.ncbi.nlm.nih.gov/26695555/>
88. Chipollini, J., *et al.* Patient presentation, differential diagnosis, and management of penile lesions. *Can Urol Assoc J*, 2019. 13: S2.
<https://pubmed.ncbi.nlm.nih.gov/31237837/>
89. Lont, A.P., *et al.* A comparison of physical examination and imaging in determining the extent of primary penile carcinoma. *BJU Int*, 2003. 91: 493.
<https://pubmed.ncbi.nlm.nih.gov/12656901/>
90. Bertolotto, M., *et al.* Primary and secondary malignancies of the penis: ultrasound features. *Abdom Imaging*, 2005. 30: 108.
<https://pubmed.ncbi.nlm.nih.gov/15759326/>
91. Kayes, O., *et al.* The role of magnetic resonance imaging in the local staging of penile cancer. *Eur Urol*, 2007. 51: 1313.
<https://pubmed.ncbi.nlm.nih.gov/17113213/>
92. Hanchanale, V., *et al.* The accuracy of magnetic resonance imaging (MRI) in predicting the invasion of the tunica albuginea and the urethra during the primary staging of penile cancer. *BJU Int*, 2016. 117: 439.
<https://pubmed.ncbi.nlm.nih.gov/25600638/>
93. Krishna, S., *et al.* Diagnostic Accuracy of MRI in Local Staging (T Category) of Penile Cancer and the Value of Artificial Erection: A Systematic Review and Meta-Analysis. *AJR Am J Roentgenol*, 2022. 219: 28.
<https://pubmed.ncbi.nlm.nih.gov/35195435/>
94. Bozzini, G., *et al.* Role of Penile Doppler US in the Preoperative Assessment of Penile Squamous Cell Carcinoma Patients: Results From a Large Prospective Multicenter European Study. *Urology*, 2016. 90: 131.
<https://pubmed.ncbi.nlm.nih.gov/26776562/>

95. Wood, H.M., *et al.* Anatomic considerations of the penis, lymphatic drainage, and biopsy of the sentinel node. *Urol Clin North Am*, 2010. 37: 327.
<https://pubmed.ncbi.nlm.nih.gov/20674689/>
96. Horenblas, S., *et al.* Squamous cell carcinoma of the penis. IV. Prognostic factors of survival: analysis of tumor, nodes and metastasis classification system. *J Urol*, 1994. 151: 1239.
<https://pubmed.ncbi.nlm.nih.gov/8158767/>
97. Srinivas, V., *et al.* Penile cancer: relation of extent of nodal metastasis to survival. *J Urol*, 1987. 137: 880.
<https://pubmed.ncbi.nlm.nih.gov/3573181/>
98. Kroon, B.K., *et al.* Patients with penile carcinoma benefit from immediate resection of clinically occult lymph node metastases. *J Urol*, 2005. 173: 816.
<https://pubmed.ncbi.nlm.nih.gov/15711276/>
99. Horenblas, S., *et al.* Squamous cell carcinoma of the penis. II. Treatment of the primary tumor. *J Urol*, 1992. 147: 1533.
<https://pubmed.ncbi.nlm.nih.gov/1593683/>
100. Woldu, S.L., *et al.* Usage and survival implications of surgical staging of inguinal lymph nodes in intermediate- to high-risk, clinical localized penile cancer: A propensity-score matched analysis. *Urol Oncol*, 2018. 36: 159.e7.
<https://pubmed.ncbi.nlm.nih.gov/29288008/>
101. Mueller-Lisse, U.G., *et al.* Functional imaging in penile cancer: PET/computed tomography, MRI, and sentinel lymph node biopsy. *Curr Opin Urol*, 2008. 18: 105.
<https://pubmed.ncbi.nlm.nih.gov/18090498/>
102. Leijte, J.A., *et al.* Prospective evaluation of hybrid 18F-fluorodeoxyglucose positron emission tomography/computed tomography in staging clinically node-negative patients with penile carcinoma. *BJU Int*, 2009. 104: 640.
<https://pubmed.ncbi.nlm.nih.gov/19281465/>
103. Schlenker, B., *et al.* Detection of inguinal lymph node involvement in penile squamous cell carcinoma by 18F-fluorodeoxyglucose PET/CT: a prospective single-center study. *Urol Oncol*, 2012. 30: 55.
<https://pubmed.ncbi.nlm.nih.gov/20022269/>
104. Jakobsen, J.K., *et al.* DaPeCa-7: comparative assessment of fluorodeoxyglucose positron emission tomography/computed tomography (CT) and conventional diagnostic CT in diagnosis of lymph node metastases, distant metastases and incidental findings in patients with invasive penile cancer. *BJU Int*, 2021. 127: 254.
<https://pubmed.ncbi.nlm.nih.gov/33448605/>
105. Sadeghi, R., *et al.* Accuracy of 18F-FDG PET/CT for diagnosing inguinal lymph node involvement in penile squamous cell carcinoma: systematic review and meta-analysis of the literature. *Clin Nucl Med*, 2012. 37: 436.
<https://pubmed.ncbi.nlm.nih.gov/22475891/>
106. Krishna, R.P., *et al.* Sonography: an underutilized diagnostic tool in the assessment of metastatic groin nodes. *J Clin Ultrasound*, 2008. 36: 212.
<https://pubmed.ncbi.nlm.nih.gov/17960822/>
107. Kroon, B.K., *et al.* Ultrasonography-guided fine-needle aspiration cytology before sentinel node biopsy in patients with penile carcinoma. *BJU Int*, 2005. 95: 517.
<https://pubmed.ncbi.nlm.nih.gov/15705071/>
108. Lee, E.W.C., *et al.* High diagnostic accuracy of inguinal ultrasonography and fine-needle aspiration followed by dynamic sentinel lymph node biopsy in men with impalpable and palpable inguinal lymph nodes. *BJU Int*, 2022. 130: 331.
<https://pubmed.ncbi.nlm.nih.gov/35098622/>
109. Graafland, N.M., *et al.* Prognostic factors for occult inguinal lymph node involvement in penile carcinoma and assessment of the high-risk EAU subgroup: a two-institution analysis of 342 clinically node-negative patients. *Eur Urol*, 2010. 58: 742.
<https://pubmed.ncbi.nlm.nih.gov/20800339/>
110. Catalona, W.J. Modified inguinal lymphadenectomy for carcinoma of the penis with preservation of saphenous veins: technique and preliminary results. *J Urol*, 1988. 140: 306.
<https://pubmed.ncbi.nlm.nih.gov/3398125/>
111. Protzel, C., *et al.* Lymphadenectomy in the surgical management of penile cancer. *Eur Urol*, 2009. 55: 1075.
<https://pubmed.ncbi.nlm.nih.gov/19264390/>

112. d'Ancona, C.A., *et al.* Long-term followup of penile carcinoma treated with penectomy and bilateral modified inguinal lymphadenectomy. *J Urol*, 2004. 172: 498.
<https://pubmed.ncbi.nlm.nih.gov/15247713/>
113. Thyavihally, Y.B., *et al.* Comparative study of perioperative and survival outcomes after video endoscopic inguinal lymphadenectomy (VEIL) and open inguinal lymph node dissection (O-ILND) in the management of inguinal lymph nodes in carcinoma of the penis. *J Robot Surg*, 2021. 15: 905.
<https://pubmed.ncbi.nlm.nih.gov/33484414/>
114. Wever, L., *et al.* Incidence and risk factor analysis of complications after sentinel node biopsy for penile cancer. *BJU Int*, 2022. 130: 486.
<https://pubmed.ncbi.nlm.nih.gov/35257463/>
115. Gopman, J.M., *et al.* Predicting postoperative complications of inguinal lymph node dissection for penile cancer in an international multicentre cohort. *BJU Int*, 2015. 116: 196.
<https://pubmed.ncbi.nlm.nih.gov/25777366/>
116. Gómez-Ferrer, A., *et al.* A single-center comparison of our initial experiences in treating penile and urethral cancer with video-endoscopic inguinal lymphadenectomy (VEIL) and later experiences in melanoma cases. *Front Surg*, 2022. 9: 870857.
<https://pubmed.ncbi.nlm.nih.gov/36225221/>
117. Muñoz Guillermo, V., *et al.* [Video endoscopic inguinal lymphadenectomy in penile cancer: Systematic review]. *Arch Esp Urol*, 2019. 72: 992.
<https://pubmed.ncbi.nlm.nih.gov/31823847/>
118. Horenblas, S., *et al.* Detection of occult metastasis in squamous cell carcinoma of the penis using a dynamic sentinel node procedure. *J Urol*, 2000. 163: 100.
<https://pubmed.ncbi.nlm.nih.gov/10604324/>
119. de Vries, H.M., *et al.* Clinicopathological predictors of finding additional inguinal lymph node metastases in penile cancer patients after positive dynamic sentinel node biopsy: a European multicentre evaluation. *BJU Int*, 2022. 130: 126.
<https://pubmed.ncbi.nlm.nih.gov/34927790/>
120. Dell'Oglio, P., *et al.* Hybrid Indocyanine Green-(99m)Tc-nanocolloid for Single-photon Emission Computed Tomography and Combined Radio- and Fluorescence-guided Sentinel Node Biopsy in Penile Cancer: Results of 740 Inguinal Basins Assessed at a Single Institution. *Eur Urol*, 2020. 78: 865.
<https://pubmed.ncbi.nlm.nih.gov/32950298/>
121. Leijte, J.A., *et al.* Reliability and safety of current dynamic sentinel node biopsy for penile carcinoma. *Eur Urol*, 2007. 52: 170.
<https://pubmed.ncbi.nlm.nih.gov/17316967/>
122. Zou, Z.J., *et al.* Radiocolloid-based dynamic sentinel lymph node biopsy in penile cancer with clinically negative inguinal lymph node: an updated systematic review and meta-analysis. *Int Urol Nephrol*, 2016. 48: 2001.
<https://pubmed.ncbi.nlm.nih.gov/27577753/>
123. Hughes, B., *et al.* Non-invasive and minimally invasive staging of regional lymph nodes in penile cancer. *World J Urol*, 2009. 27: 197.
<https://pubmed.ncbi.nlm.nih.gov/18594830/>
124. Hövels, A.M., *et al.* The diagnostic accuracy of CT and MRI in the staging of pelvic lymph nodes in patients with prostate cancer: a meta-analysis. *Clin Radiol*, 2008. 63: 387.
<https://pubmed.ncbi.nlm.nih.gov/18325358/>
125. Antoch, G., *et al.* Accuracy of whole-body dual-modality fluorine-18-2-fluoro-2-deoxy-D-glucose positron emission tomography and computed tomography (FDG-PET/CT) for tumor staging in solid tumors: comparison with CT and PET. *J Clin Oncol*, 2004. 22: 4357.
<https://pubmed.ncbi.nlm.nih.gov/15514377/>
126. Graafland, N.M., *et al.* Scanning with 18F-FDG-PET/CT for detection of pelvic nodal involvement in inguinal node-positive penile carcinoma. *Eur Urol*, 2009. 56: 339.
<https://pubmed.ncbi.nlm.nih.gov/19477581/>
127. Ashley, S., *et al.* Human Papilloma Virus (HPV) status may impact treatment outcomes in patients with pre-cancerous penile lesions (an eUROGEN Study). *Int J Impot Res*, 2021. 33: 620.
<https://pubmed.ncbi.nlm.nih.gov/32710000/>
128. Hoekstra, R.J., *et al.* Penile intraepithelial neoplasia: Nomenclature, incidence and progression to malignancy in the Netherlands. *Int J Urol*, 2019. 26: 353.
<https://pubmed.ncbi.nlm.nih.gov/30508877/>

129. Kravvas, G., *et al.* The management of penile intraepithelial neoplasia (PeIN): clinical and histological features and treatment of 345 patients and a review of the literature. *J Dermatolog Treat*, 2022. 33: 1047.
<https://pubmed.ncbi.nlm.nih.gov/32705920/>
130. Kristiansen, S., *et al.* Incidence of penile intraepithelial neoplasia and treatment strategies in Sweden 2000-2019. *BJU Int*, 2022. 129: 752.
<https://pubmed.ncbi.nlm.nih.gov/35044047/>
131. Alnajjar, H.M., *et al.* Treatment of carcinoma *in situ* of the glans penis with topical chemotherapy agents. *Eur Urol*, 2012. 62: 923.
<https://pubmed.ncbi.nlm.nih.gov/22421082/>
132. Issa, A., *et al.* Treatment Options and Outcomes for Men with Penile Intraepithelial Neoplasia: A Systematic Review. *Eur Urol Focus*, 2022. 8: 829.
<https://pubmed.ncbi.nlm.nih.gov/33994168/>
133. Kim, J.Y.S., *et al.* Guidelines of care for the management of cutaneous squamous cell carcinoma. *J Am Acad Dermatol*, 2018. 78: 560.
<https://pubmed.ncbi.nlm.nih.gov/29331386/>
134. Leone, A., *et al.* Need for Evidence and Consensus on Laser Treatment for Management of Select Primary Penile Tumors. *Eur Urol*, 2017. 72: 4.
<https://pubmed.ncbi.nlm.nih.gov/28131464/>
135. Shaw, K.S., *et al.* Combination of imiquimod with cryotherapy in the treatment of penile intraepithelial neoplasia. *JAAD Case Rep*, 2017. 3: 546.
<https://pubmed.ncbi.nlm.nih.gov/29264388/>
136. Paoli, J., *et al.* Penile intraepithelial neoplasia: results of photodynamic therapy. *Acta Derm Venereol*, 2006. 86: 418.
<https://pubmed.ncbi.nlm.nih.gov/16955186/>
137. Schlenker, B., *et al.* Organ-preserving neodymium-yttrium-aluminium-garnet laser therapy for penile carcinoma: a long-term follow-up. *BJU Int*, 2010. 106: 786.
<https://pubmed.ncbi.nlm.nih.gov/20089106/>
138. Meijer, R.P., *et al.* Long-term follow-up after laser therapy for penile carcinoma. *Urology*, 2007. 69: 759.
<https://pubmed.ncbi.nlm.nih.gov/17445665/>
139. Shabbir, M., *et al.* Glans resurfacing for the treatment of carcinoma *in situ* of the penis: surgical technique and outcomes. *Eur Urol*, 2011. 59: 142.
<https://pubmed.ncbi.nlm.nih.gov/21050658/>
140. Caldamone, A.A., *et al.* Buccal mucosal grafts for urethral reconstruction. *Urology*, 1998. 51: 15.
<https://pubmed.ncbi.nlm.nih.gov/9610551/>
141. Håkansson, U., *et al.* Organ-sparing reconstructive surgery in penile cancer: initial experiences at two Swedish referral centres. *Scand J Urol*, 2015. 49: 149.
<https://pubmed.ncbi.nlm.nih.gov/25313620/>
142. Pang, K.H., *et al.* Advances in penile-sparing surgical approaches. *Asian J Urol*, 2022. 9: 359.
<https://pubmed.ncbi.nlm.nih.gov/36381598/>
143. Cakir, O.O., *et al.* Surgical technique and outcomes following coronal-sparing glans resurfacing for benign and malignant penile lesions. *Int J Impot Res*, 2022. 34: 495.
<https://pubmed.ncbi.nlm.nih.gov/34285385/>
144. Corbishley, C.M., *et al.* Glans resurfacing for precancerous and superficially invasive carcinomas of the glans penis: Pathological specimen handling and reporting. *Semin Diagn Pathol*, 2015. 32: 232.
<https://pubmed.ncbi.nlm.nih.gov/25662797/>
145. Roussel, E., *et al.* Predictors of local recurrence and its impact on survival after glansectomy for penile cancer: time to challenge the dogma? *BJU Int*, 2021. 127: 606.
<https://pubmed.ncbi.nlm.nih.gov/33180969/>
146. Djajadiningrat, R.S., *et al.* Penile sparing surgery for penile cancer-does it affect survival? *J Urol*, 2014. 192: 120.
<https://pubmed.ncbi.nlm.nih.gov/24373799/>
147. Leijte, J.A., *et al.* Recurrence patterns of squamous cell carcinoma of the penis: recommendations for follow-up based on a two-centre analysis of 700 patients. *Eur Urol*, 2008. 54: 161.
<https://pubmed.ncbi.nlm.nih.gov/18440124/>
148. Agrawal, A., *et al.* The histological extent of the local spread of carcinoma of the penis and its therapeutic implications. *BJU Int*, 2000. 85: 299.
<https://pubmed.ncbi.nlm.nih.gov/10671885/>

149. Minhas, S., *et al.* What surgical resection margins are required to achieve oncological control in men with primary penile cancer? *BJU Int*, 2005. 96: 1040.
<https://pubmed.ncbi.nlm.nih.gov/16225525/>
150. Philippou, P., *et al.* Conservative surgery for squamous cell carcinoma of the penis: resection margins and long-term oncological control. *J Urol*, 2012. 188: 803.
<https://pubmed.ncbi.nlm.nih.gov/22818137/>
151. Sri, D., *et al.* A study into the association between local recurrence rates and surgical resection margins in organ-sparing surgery for penile squamous cell cancer. *BJU Int*, 2018. 122: 576.
<https://pubmed.ncbi.nlm.nih.gov/29604228/>
152. Ellul, T., *et al.* Frozen section analysis for organ-conserving surgery in penile cancer: Assessing oncological outcomes and trends of local recurrence. *J Clin Urol*, 2020. 13: 419.
<https://journals.sagepub.com/doi/full/10.1177/2051415820903192>
153. Kamel, M.H., *et al.* Organ Sparing Surgery for Penile Cancer: A Systematic Review. *J Urol*, 2017. 198: 770.
<https://pubmed.ncbi.nlm.nih.gov/28286072/>
154. Tang, D.H., *et al.* Laser ablation as monotherapy for penile squamous cell carcinoma: A multi-center cohort analysis. *Urol Oncol*, 2018. 36: 147.
<https://pubmed.ncbi.nlm.nih.gov/29097087/>
155. Musi, G., *et al.* Thulium-yttrium-aluminium-garnet (Tm:YAG) laser treatment of penile cancer: oncological results, functional outcomes, and quality of life. *World J Urol*, 2018. 36: 265.
<https://pubmed.ncbi.nlm.nih.gov/29197968/>
156. Falcone, M., *et al.* Total Glans Resurfacing for the Management of Superficial Penile Cancer: A Retrospective Cohort Analysis in a Tertiary Referral Center. *Urology*, 2020. 145: 281.
<https://pubmed.ncbi.nlm.nih.gov/32683069/>
157. Pérez, J., *et al.* Oncological and Functional Outcomes After Organ-Sparing Plastic Reconstructive Surgery for Penile Cancer. *Urology*, 2020. 142: 161.
<https://pubmed.ncbi.nlm.nih.gov/32380155/>
158. O'Kelly, F., *et al.* A Prospective Study of Total Glans Resurfacing for Localized Penile Cancer to Maximize Oncologic and Functional Outcomes in a Tertiary Referral Network. *J Urol*, 2017. 197: 1258.
<https://pubmed.ncbi.nlm.nih.gov/28027867/>
159. Pang, K.H., *et al.* Glansectomy and Reconstruction for Penile Cancer: A Systematic Review. *Eur Urol Focus*, 2021.
<https://pubmed.ncbi.nlm.nih.gov/34903488/>
160. Crook, J., *et al.* Penile brachytherapy: technical aspects and postimplant issues. *Brachytherapy*, 2010. 9: 151.
<https://pubmed.ncbi.nlm.nih.gov/19854685/>
161. de Crevoisier, R., *et al.* Long-term results of brachytherapy for carcinoma of the penis confined to the glans (N- or NX). *Int J Radiat Oncol Biol Phys*, 2009. 74: 1150.
<https://pubmed.ncbi.nlm.nih.gov/19395183/>
162. Delaunay, B., *et al.* Brachytherapy for penile cancer: efficacy and impact on sexual function. *Brachytherapy*, 2014. 13: 380.
<https://pubmed.ncbi.nlm.nih.gov/23896397/>
163. Kamsu-Kom, L., *et al.* Clinical Experience with Pulse Dose Rate Brachytherapy for Conservative Treatment of Penile Carcinoma and Comparison with Historical Data of Low Dose Rate Brachytherapy. *Clin Oncol (R Coll Radiol)*, 2015. 27: 387.
<https://pubmed.ncbi.nlm.nih.gov/26003455/>
164. Sharma, D.N., *et al.* High-dose-rate interstitial brachytherapy for T1-T2-stage penile carcinoma: short-term results. *Brachytherapy*, 2014. 13: 481.
<https://pubmed.ncbi.nlm.nih.gov/25037912/>
165. Pohanková, D., *et al.* High-Dose Rate Brachytherapy in the Treatment of Early Stages of Penile Carcinoma. *Klin Onkol*, 2019. 32: 52.
<https://pubmed.ncbi.nlm.nih.gov/30764630/>
166. Martz, N., *et al.* High-dose rate brachytherapy in localized penile cancer: 5-Year clinical outcome analysis. *Clin Transl Radiat Oncol*, 2021. 27: 89.
<https://pubmed.ncbi.nlm.nih.gov/33537466/>
167. Kellas-Ślęczka, S., *et al.* Nineteen-year single-center experience in 76 patients with penile cancer treated with high-dose-rate brachytherapy. *Brachytherapy*, 2019. 18: 493.
<https://pubmed.ncbi.nlm.nih.gov/31101437/>
168. Rouscuff, Y., *et al.* High-dose rate brachytherapy in localized penile cancer: short-term clinical outcome analysis. *Radiat Oncol*, 2014. 9: 142.
<https://pubmed.ncbi.nlm.nih.gov/24941956/>

169. Rishi, A., *et al.* Novel portable apparatus for outpatient high-dose-rate (HDR) brachytherapy in penile cancer. *Brachytherapy*, 2022. 21: 839.
<https://pubmed.ncbi.nlm.nih.gov/35915039/>
170. Azrif, M., *et al.* External-beam radiotherapy in T1-2 N0 penile carcinoma. *Clin Oncol (R Coll Radiol)*, 2006. 18: 320.
<https://pubmed.ncbi.nlm.nih.gov/16703750/>
171. Rozan, R., *et al.* Interstitial brachytherapy for penile carcinoma: a multicentric survey (259 patients). *Radiother Oncol*, 1995. 36: 83.
<https://pubmed.ncbi.nlm.nih.gov/7501816/>
172. Delannes, M., *et al.* Iridium-192 interstitial therapy for squamous cell carcinoma of the penis. *Int J Radiat Oncol Biol Phys*, 1992. 24: 479.
<https://pubmed.ncbi.nlm.nih.gov/1399733/>
173. Hasan, S., *et al.* The role of brachytherapy in organ preservation for penile cancer: A meta-analysis and review of the literature. *Brachytherapy*, 2015. 14: 517.
<https://pubmed.ncbi.nlm.nih.gov/25944394/>
174. Zouhair, A., *et al.* Radiation therapy alone or combined surgery and radiation therapy in squamous-cell carcinoma of the penis? *Eur J Cancer*, 2001. 37: 198.
<https://pubmed.ncbi.nlm.nih.gov/11166146/>
175. Cordoba, A., *et al.* Low-dose brachytherapy for early stage penile cancer: a 20-year single-institution study (73 patients). *Radiat Oncol*, 2016. 11: 96.
<https://pubmed.ncbi.nlm.nih.gov/27464910/>
176. Gambachidze, D., *et al.* Long-term evaluation of urinary, sexual, and quality of life outcomes after brachytherapy for penile carcinoma. *Brachytherapy*, 2018. 17: 221.
<https://pubmed.ncbi.nlm.nih.gov/29089276/>
177. Djajadiningrat, R.S., *et al.* Neoadjuvant taxane-based combination chemotherapy in patients with advanced penile cancer. *Clin Genitourin Cancer*, 2015. 13: 44.
<https://pubmed.ncbi.nlm.nih.gov/25009098/>
178. Johnstone, P.A.S., *et al.* Changing Radiotherapy Paradigms in Penile Cancer. *Eur Urol Open Sci*, 2022. 36: 47.
<https://pubmed.ncbi.nlm.nih.gov/35028598/>
179. Ottenhof, S.R., *et al.* Surgical and Oncological Outcomes in Patients After Vascularised Flap Reconstruction for Locoregionally Advanced Penile Cancer. *Eur Urol Focus*, 2019. 5: 867.
<https://pubmed.ncbi.nlm.nih.gov/29433986/>
180. Pagliaro, L.C., *et al.* Neoadjuvant paclitaxel, ifosfamide, and cisplatin chemotherapy for metastatic penile cancer: a phase II study. *J Clin Oncol*, 2010. 28: 3851.
<https://pubmed.ncbi.nlm.nih.gov/20625118/>
181. Pizzocaro, G., *et al.* Taxanes in combination with cisplatin and fluorouracil for advanced penile cancer: preliminary results. *Eur Urol*, 2009. 55: 546.
<https://pubmed.ncbi.nlm.nih.gov/18649992/>
182. Necchi, A., *et al.* Clinical Outcomes of Perioperative Chemotherapy in Patients With Locally Advanced Penile Squamous-Cell Carcinoma: Results of a Multicenter Analysis. *Clin Genitourin Cancer*, 2017. 15: 548.
<https://pubmed.ncbi.nlm.nih.gov/28325636/>
183. Nicolai, N., *et al.* A Combination of Cisplatin and 5-Fluorouracil With a Taxane in Patients Who Underwent Lymph Node Dissection for Nodal Metastases From Squamous Cell Carcinoma of the Penis: Treatment Outcome and Survival Analyses in Neoadjuvant and Adjuvant Settings. *Clin Genitourin Cancer*, 2016. 14: 323.
<https://pubmed.ncbi.nlm.nih.gov/26341040/>
184. Nicholson, S., *et al.* Phase II trial of docetaxel, cisplatin and 5FU chemotherapy in locally advanced and metastatic penis cancer (CRUK/09/001). *Br J Cancer*, 2013. 109: 2554.
<https://pubmed.ncbi.nlm.nih.gov/24169355/>
185. Nicholson, S., *et al.* VinCaP: a phase II trial of vinflunine in locally advanced and metastatic squamous carcinoma of the penis. *Br J Cancer*, 2022. 126: 34.
<https://pubmed.ncbi.nlm.nih.gov/34671131/>
186. Theodore, C., *et al.* A phase II multicentre study of irinotecan (CPT 11) in combination with cisplatin (CDDP) in metastatic or locally advanced penile carcinoma (EORTC PROTOCOL 30992). *Ann Oncol*, 2008. 19: 1304.
<https://pubmed.ncbi.nlm.nih.gov/18417462/>

187. Azizi, M., *et al.* Systematic Review and Meta-Analysis-Is there a Benefit in Using Neoadjuvant Systemic Chemotherapy for Locally Advanced Penile Squamous Cell Carcinoma? *J Urol*, 2020. 203: 1147.
<https://pubmed.ncbi.nlm.nih.gov/31928407/>
188. Yi, X.Y., *et al.* Neoadjuvant chemotherapy for patients with locally advanced penile cancer: an updated evidence. *Asian J Androl*, 2022. 24: 180.
<https://pubmed.ncbi.nlm.nih.gov/34975068/>
189. McComas, K., *et al.* Definitive Chemoradiotherapy for Locally Advanced, Lymph-node Positive, Nonmetastatic Penile Squamous Cell Carcinoma. *Clin Genitourin Cancer*, 2020. 18: e573.
<https://pubmed.ncbi.nlm.nih.gov/32335061/>
190. Ottenhof, S.R., *et al.* 497 - Chemoradiation in the treatment of loco-regionally advanced penile cancer. *Eur Urol Suppl*, 2019. 18: e655.
<https://www.sciencedirect.com/science/article/abs/pii/S1569905619304841?via%3Dihub>
191. Ornellas, A.A., *et al.* Surgical treatment of invasive squamous cell carcinoma of the penis: Brazilian National Cancer Institute long-term experience. *J Surg Oncol*, 2008. 97: 487.
<https://pubmed.ncbi.nlm.nih.gov/18425779/>
192. Veeratterapillay, R., *et al.* Oncologic Outcomes of Penile Cancer Treatment at a UK Supraregional Center. *Urology*, 2015. 85: 1097.
<https://pubmed.ncbi.nlm.nih.gov/25769781/>
193. Gotsadze, D., *et al.* Is conservative organ-sparing treatment of penile carcinoma justified? *Eur Urol*, 2000. 38: 306.
<https://pubmed.ncbi.nlm.nih.gov/10940705/>
194. Daseler, E.H., *et al.* Radical excision of the inguinal and iliac lymph glands; a study based upon 450 anatomical dissections and upon supportive clinical observations. *Surg Gynecol Obstet*, 1948. 87: 679.
<https://pubmed.ncbi.nlm.nih.gov/18120502/>
195. Leijte, J.A., *et al.* Anatomical mapping of lymphatic drainage in penile carcinoma with SPECT-CT: implications for the extent of inguinal lymph node dissection. *Eur Urol*, 2008. 54: 885.
<https://pubmed.ncbi.nlm.nih.gov/18502024/>
196. Omorphos, S., *et al.* Zonal mapping of sentinel lymph nodes in penile cancer patients using fused SPECT/CT imaging and lymphoscintigraphy. *Urol Oncol*, 2018. 36: 530.e1.
<https://pubmed.ncbi.nlm.nih.gov/30318180/>
197. Yao, K., *et al.* Lymph Node Mapping in Patients with Penile Cancer Undergoing Pelvic Lymph Node Dissection. *J Urol*, 2021. 205: 145.
<https://pubmed.ncbi.nlm.nih.gov/32755338/>
198. Culkin, D.J., *et al.* Advanced penile carcinoma. *J Urol*, 2003. 170: 359.
<https://pubmed.ncbi.nlm.nih.gov/12853775/>
199. Leewansangtong, S., *et al.* The risks of lymph node metastasis and the prognostic factors in carcinoma of the penis: analysis of 50 patients treated with bilateral ilioinguinal lymphadenectomy. *J Med Assoc Thai*, 2001. 84: 204.
<https://pubmed.ncbi.nlm.nih.gov/11336079/>
200. Marconnet, L., *et al.* Long-term followup of penile carcinoma with high risk for lymph node invasion treated with inguinal lymphadenectomy. *J Urol*, 2010. 183: 2227.
<https://pubmed.ncbi.nlm.nih.gov/20399455/>
201. Martin, T.G., *et al.* Inguinal Lymphadenectomy for Squamous Cell Cancer of the Penis—Experience of a UK Supra-Regional Network. *Brit J Med Surg Urol*, 2012. 5: 241.
<https://journals.sagepub.com/doi/10.1016/j.bjmsu.2011.12.009>
202. Joshi, S.S., *et al.* Treatment Trends and Outcomes for Patients With Lymph Node-Positive Cancer of the Penis. *JAMA Oncol*, 2018. 4: 643.
<https://pubmed.ncbi.nlm.nih.gov/29494739/>
203. Johnson, T.V., *et al.* Extensive inguinal lymphadenectomy improves overall 5-year survival in penile cancer patients: results from the Surveillance, Epidemiology, and End Results program. *Cancer*, 2010. 116: 2960.
<https://pubmed.ncbi.nlm.nih.gov/20564401/>
204. Chang, E.K., *et al.* Underutilization of Surgical Standard of Care for Insured Men with Invasive Penile Cancer. *Urol Pract*, 2021. 8: 348.
<https://pubmed.ncbi.nlm.nih.gov/33898656/>
205. Cindolo, L., *et al.* Adherence to EAU guidelines on penile cancer translates into better outcomes: a multicenter international study. *World J Urol*, 2019. 37: 1649.
<https://pubmed.ncbi.nlm.nih.gov/30377813/>

206. Fankhauser, C.D., *et al.* Practice Patterns Among Penile Cancer Surgeons Performing Dynamic Sentinel Lymph Node Biopsy and Radical Inguinal Lymph Node Dissection in Men with Penile Cancer: A eUROGEN Survey. *Eur Urol Open Sci*, 2021. 24: 39.
<https://pubmed.ncbi.nlm.nih.gov/34337494/>
207. Yao, K., *et al.* Fascia lata preservation during inguinal lymphadenectomy for penile cancer: rationale and outcome. *Urology*, 2013. 82: 642.
<https://pubmed.ncbi.nlm.nih.gov/23876593/>
208. Chipollini, J., *et al.* Identifying an optimal lymph node yield for penile squamous cell carcinoma: prognostic impact of surgical dissection. *BJU Int*, 2020. 125: 82.
<https://pubmed.ncbi.nlm.nih.gov/31356716/>
209. Li, Z.S., *et al.* Disease-specific survival after radical lymphadenectomy for penile cancer: prediction by lymph node count and density. *Urol Oncol*, 2014. 32: 893.
<https://pubmed.ncbi.nlm.nih.gov/24994488/>
210. Mao, W., *et al.* More lymph node dissection improves survival in patients with newly diagnosed lymph node-positive penile cancer. *Int Urol Nephrol*, 2019. 51: 641.
<https://pubmed.ncbi.nlm.nih.gov/30758771/>
211. Soodana-Prakash, N., *et al.* Lymph node yield as a predictor of overall survival following inguinal lymphadenectomy for penile cancer. *Urol Oncol*, 2018. 36: 471.e19.
<https://pubmed.ncbi.nlm.nih.gov/30143385/>
212. Zhu, Y., *et al.* Population-based assessment of the number of lymph nodes removed in the treatment of penile squamous cell carcinoma. *Urol Int*, 2014. 92: 186.
<https://pubmed.ncbi.nlm.nih.gov/24246932/>
213. Johnson, D.E., *et al.* Management of regional lymph nodes in penile carcinoma. Five-year results following therapeutic groin dissections. *Urology*, 1984. 24: 308.
<https://pubmed.ncbi.nlm.nih.gov/6485188/>
214. Chipollini, J., *et al.* Delay to Inguinal Lymph Node Dissection Greater than 3 Months Predicts Poorer Recurrence-Free Survival for Patients with Penile Cancer. *J Urol*, 2017. 198: 1346.
<https://pubmed.ncbi.nlm.nih.gov/28652123/>
215. Gulia, A.K., *et al.* Impact of delay in inguinal lymph node dissection in patients with carcinoma of penis. *Indian J Cancer*, 2009. 46: 214.
<https://pubmed.ncbi.nlm.nih.gov/19574673/>
216. Hegarty, P.K., *et al.* Controversies in ilioinguinal lymphadenectomy. *Urol Clin North Am*, 2010. 37: 421.
<https://pubmed.ncbi.nlm.nih.gov/20674697/>
217. Ravi, R. Morbidity following groin dissection for penile carcinoma. *Br J Urol*, 1993. 72: 941.
<https://pubmed.ncbi.nlm.nih.gov/8306161/>
218. Koifman, L., *et al.* Radical open inguinal lymphadenectomy for penile carcinoma: surgical technique, early complications and late outcomes. *J Urol*, 2013. 190: 2086.
<https://pubmed.ncbi.nlm.nih.gov/23770135/>
219. Stuijver, M.M., *et al.* Early wound complications after inguinal lymphadenectomy in penile cancer: a historical cohort study and risk-factor analysis. *Eur Urol*, 2013. 64: 486.
<https://pubmed.ncbi.nlm.nih.gov/23490726/>
220. Sharma, P., *et al.* Sarcopenia as a predictor of complications in penile cancer patients undergoing inguinal lymph node dissection. *World J Urol*, 2015. 33: 1585.
<https://pubmed.ncbi.nlm.nih.gov/25552207/>
221. Bevan-Thomas, R., *et al.* Contemporary morbidity from lymphadenectomy for penile squamous cell carcinoma: the M.D. Anderson Cancer Center Experience. *J Urol*, 2002. 167: 1638.
<https://pubmed.ncbi.nlm.nih.gov/11912379/>
222. Bouchot, O., *et al.* Morbidity of inguinal lymphadenectomy for invasive penile carcinoma. *Eur Urol*, 2004. 45: 761.
<https://pubmed.ncbi.nlm.nih.gov/15149749/>
223. Mistretta, F.A., *et al.* Adherence to guideline recommendations for lymph node dissection in squamous cell carcinoma of the penis: Effect on survival and complication rates. *Urol Oncol*, 2019. 37: 578.e11.
<https://pubmed.ncbi.nlm.nih.gov/31296420/>
224. Nelson, B.A., *et al.* Complications of inguinal and pelvic lymphadenectomy for squamous cell carcinoma of the penis: a contemporary series. *J Urol*, 2004. 172: 494.
<https://pubmed.ncbi.nlm.nih.gov/15247712/>

225. Ray, M.D., *et al.* Minimizing Post-operative Complications of Groin Dissection Using Modified Skin Bridge Technique: A Single-Centre Descriptive Study Showing Post-operative and Early Oncological Outcomes. *World J Surg*, 2018. 42: 3196.
<https://pubmed.ncbi.nlm.nih.gov/29654358/>
226. Bertheuil, N., *et al.* Inguinal lymphadenectomy for stage III melanoma: a comparative study of two surgical approaches at the onset of lymphoedema. *Eur J Surg Oncol*, 2015. 41: 215.
<https://pubmed.ncbi.nlm.nih.gov/25524886/>
227. Abbas, S., *et al.* Systematic review and meta-analysis of the used surgical techniques to reduce leg lymphedema following radical inguinal nodes dissection. *Surg Oncol*, 2011. 20: 88.
<https://pubmed.ncbi.nlm.nih.gov/20005090/>
228. Tonouchi, H., *et al.* Operative morbidity associated with groin dissections. *Surg Today*, 2004. 34: 413.
<https://pubmed.ncbi.nlm.nih.gov/15108079/>
229. Schmid, S.C., *et al.* Final results of the PräVAC trial: prevention of wound complications following inguinal lymph node dissection in patients with penile cancer using epidermal vacuum-assisted wound closure. *World J Urol*, 2021. 39: 613.
<https://pubmed.ncbi.nlm.nih.gov/32372159/>
230. Tranoulis, A., *et al.* The Impact of Saphenous Vein Sparing During Inguinal Lymphadenectomy on Postoperative Morbidity in Women With Vulval Cancer: An Updated Per-Groin Meta-analysis of Short-term Outcomes. *Int J Gynecol Cancer*, 2018. 28: 1232.
<https://pubmed.ncbi.nlm.nih.gov/29787421/>
231. Cui, Y., *et al.* Saphenous vein sparing during laparoscopic bilateral inguinal lymphadenectomy for penile carcinoma patients. *Int Urol Nephrol*, 2016. 48: 363.
<https://pubmed.ncbi.nlm.nih.gov/26660956/>
232. Pouwer, A.W., *et al.* Volume-controlled versus short drainage after inguofemoral lymphadenectomy in vulvar cancer patients: A Dutch nationwide prospective study. *Gynecol Oncol*, 2017. 146: 580.
<https://pubmed.ncbi.nlm.nih.gov/28687171/>
233. Weldrick, C., *et al.* A comparison of fibrin sealant versus standard closure in the reduction of postoperative morbidity after groin dissection: A systematic review and meta-analysis. *Eur J Surg Oncol*, 2014. 40: 1391.
<https://pubmed.ncbi.nlm.nih.gov/25125341/>
234. Matthey-Gié, M.L., *et al.* Prospective Randomized Study to Compare Lymphocele and Lymphorrhea Control Following Inguinal and Axillary Therapeutic Lymph Node Dissection With or Without the Use of an Ultrasonic Scalpel. *Ann Surg Oncol*, 2016. 23: 1716.
<https://pubmed.ncbi.nlm.nih.gov/26714939/>
235. Pouwer, A.W., *et al.* Reduced morbidity by using LigaSure compared to conventional inguofemoral lymphadenectomy in vulvar cancer patients: A randomized controlled trial. *Surg Oncol*, 2020. 35: 149.
<https://pubmed.ncbi.nlm.nih.gov/32877884/>
236. Schwentner, C., *et al.* Endoscopic inguofemoral lymphadenectomy--extended follow-up. *J Endourol*, 2013. 27: 497.
<https://pubmed.ncbi.nlm.nih.gov/23067251/>
237. Kumar, V., *et al.* Prospective study comparing video-endoscopic radical inguinal lymph node dissection (VEILND) with open radical ILND (OILND) for penile cancer over an 8-year period. *BJU Int*, 2017. 119: 530.
<https://pubmed.ncbi.nlm.nih.gov/27628265/>
238. Singh, A., *et al.* Comparing Outcomes of Robotic and Open Inguinal Lymph Node Dissection in Patients with Carcinoma of the Penis. *J Urol*, 2018. 199: 1518.
<https://pubmed.ncbi.nlm.nih.gov/29307685/>
239. Mosti, G., *et al.* Compression therapy in lymphedema: Between past and recent scientific data. *Phlebology*, 2019. 34: 515.
<https://pubmed.ncbi.nlm.nih.gov/30626269/>
240. Ettema, H.B., *et al.* Prevention of venous thromboembolism in patients with immobilization of the lower extremities: a meta-analysis of randomized controlled trials. *J Thromb Haemost*, 2008. 6: 1093.
<https://pubmed.ncbi.nlm.nih.gov/18429944/>
241. Lightner, D.J., *et al.* Best Practice Statement on Urologic Procedures and Antimicrobial Prophylaxis. *J Urol*, 2020. 203: 351.
<https://pubmed.ncbi.nlm.nih.gov/31441676/>
242. Jindal, T., *et al.* Laparoscopic and robotic video endoscopic inguinal lymphadenectomy by the lateral approach. *Asian J Endosc Surg*, 2021. 14: 464.
<https://pubmed.ncbi.nlm.nih.gov/33200462/>

243. Yuan, P., *et al.* Comparative Study of Video Endoscopic Inguinal Lymphadenectomy Through a Hypogastric vs Leg Subcutaneous Approach for Penile Cancer. *J Endourol*, 2018. 32: 66.
<https://pubmed.ncbi.nlm.nih.gov/29256632/>
244. Subirá-Ríos, D., *et al.* Minimally Invasive Laparoscopic Technique for Lymph Node Dissection in Penile Cancer: The Pelvic and Inguinal Single-Site Approach: PISA Technique. *Urology*, 2021. 153: 351.
<https://pubmed.ncbi.nlm.nih.gov/33915082/>
245. Postlewait, L.M., *et al.* A Minimally Invasive Approach for Inguinal Lymphadenectomy in Melanoma and Genitourinary Malignancy: Long-Term Outcomes in an Attempted Randomized Control Trial. *Ann Surg Oncol*, 2017. 24: 3237.
<https://pubmed.ncbi.nlm.nih.gov/28770482/>
246. Fankhauser, C.D., *et al.* Saphenous-sparing Ascending Video Endoscopic Inguinal Lymph Node Dissection Using a Leg Approach: Surgical Technique and Perioperative and Pathological Outcomes. *Eur Urol Open Sci*, 2022. 35: 9.
<https://pubmed.ncbi.nlm.nih.gov/34825230/>
247. Wang, S., *et al.* Comparison of Efficiency of Video Endoscopy and Open Inguinal Lymph Node Dissection. *Anticancer Res*, 2017. 37: 4623.
<https://pubmed.ncbi.nlm.nih.gov/28739762/>
248. Shao, Y., *et al.* Comparison of different surgical methods and strategies for inguinal lymph node dissection in patients with penile cancer. *Sci Rep*, 2022. 12: 2560.
<https://pubmed.ncbi.nlm.nih.gov/35169241/>
249. Lont, A.P., *et al.* Pelvic lymph node dissection for penile carcinoma: extent of inguinal lymph node involvement as an indicator for pelvic lymph node involvement and survival. *J Urol*, 2007. 177: 947.
<https://pubmed.ncbi.nlm.nih.gov/17296384/>
250. Liu, J.Y., *et al.* The risk factors for the presence of pelvic lymph node metastasis in penile squamous cell carcinoma patients with inguinal lymph node dissection. *World J Urol*, 2013. 31: 1519.
<https://pubmed.ncbi.nlm.nih.gov/23455885/>
251. Djajadiningrat, R.S., *et al.* Prophylactic pelvic lymph node dissection in patients with penile cancer. *J Urol*, 2015. 193: 1976.
<https://pubmed.ncbi.nlm.nih.gov/25498573/>
252. Lughezzani, G., *et al.* The relationship between characteristics of inguinal lymph nodes and pelvic lymph node involvement in penile squamous cell carcinoma: a single institution experience. *J Urol*, 2014. 191: 977.
<https://pubmed.ncbi.nlm.nih.gov/24262497/>
253. Zhu, Y., *et al.* Prospectively packaged ilioinguinal lymphadenectomy for penile cancer: the disseminative pattern of lymph node metastasis. *J Urol*, 2009. 181: 2103.
<https://pubmed.ncbi.nlm.nih.gov/19286211/>
254. Li, Z.S., *et al.* Bilateral pelvic lymph node dissection for Chinese patients with penile cancer: a multicenter collaboration study. *J Cancer Res Clin Oncol*, 2017. 143: 329.
<https://pubmed.ncbi.nlm.nih.gov/27771796/>
255. Ottenhof, S.R., *et al.* F-18 Fluorodeoxyglucose Positron Emission Tomography with Computed Tomography Has High Diagnostic Value for Pelvic and Distant Staging in Patients with High-risk Penile Carcinoma. *Eur Urol Focus*, 2022. 8: 98.
<https://pubmed.ncbi.nlm.nih.gov/33685842/>
256. Sachdeva A., *et al.* Management of lymph node-positive penile cancer: a systematic review. prior to print.
https://www.crd.york.ac.uk/prospero/display_record.php?RecordID=290784
257. Ravi, R., *et al.* Role of radiation therapy in the treatment of carcinoma of the penis. *Br J Urol*, 1994. 74: 646.
<https://pubmed.ncbi.nlm.nih.gov/7530129/>
258. Alnajjar, H.M., *et al.* Long-term outcomes for penile cancer patients presenting with advanced N3 disease requiring a myocutaneous flap reconstruction or primary closure-a retrospective single centre study. *Transl Androl Urol*, 2019. 8: S13.
<https://pubmed.ncbi.nlm.nih.gov/31143667/>
259. Koifman, L., *et al.* The role of primary inguinal surgical debulking for locally advanced penile cancer followed by reconstruction with myocutaneous flap. *Int Braz J Urol*, 2021. 47: 1162.
<https://pubmed.ncbi.nlm.nih.gov/34115458/>
260. Canter, D.J., *et al.* The International Penile Advanced Cancer Trial (InPACT): Rationale and Current Status. *Eur Urol Focus*, 2019. 5: 706.
<https://pubmed.ncbi.nlm.nih.gov/31160252/>

261. Hussein, A.M., *et al.* Chemotherapy with cisplatin and 5-fluorouracil for penile and urethral squamous cell carcinomas. *Cancer*, 1990. 65: 433.
<https://pubmed.ncbi.nlm.nih.gov/2297633/>
262. Shammas, F.V., *et al.* Cisplatin and 5-fluorouracil in advanced cancer of the penis. *J Urol*, 1992. 147: 630.
<https://pubmed.ncbi.nlm.nih.gov/1538445/>
263. Leijte, J.A., *et al.* Neoadjuvant chemotherapy in advanced penile carcinoma. *Eur Urol*, 2007. 52: 488.
<https://pubmed.ncbi.nlm.nih.gov/17316964/>
264. Sharma, P., *et al.* Adjuvant chemotherapy is associated with improved overall survival in pelvic node-positive penile cancer after lymph node dissection: a multi-institutional study. *Urol Oncol*, 2015. 33: 496 e17.
<https://pubmed.ncbi.nlm.nih.gov/26072110/>
265. Necchi, A., *et al.* Prognostic Factors of Adjuvant Taxane, Cisplatin, and 5-Fluorouracil Chemotherapy for Patients With Penile Squamous Cell Carcinoma After Regional Lymphadenectomy. *Clin Genitourin Cancer*, 2016. 14: 518.
<https://pubmed.ncbi.nlm.nih.gov/27050716/>
266. Necchi, A., *et al.* Nomogram-based prediction of overall survival after regional lymph node dissection and the role of perioperative chemotherapy in penile squamous cell carcinoma: A retrospective multicenter study. *Urol Oncol*, 2019. 37: 531.e7.
<https://pubmed.ncbi.nlm.nih.gov/31053524/>
267. Raup, V., *et al.* MP49-09 - Adjuvant chemotherapy in the treatment of lymph node positive squamous cell carcinoma of the penis: analysis of the national cancer data base. *J Urol*, 2019. 201: e709.
<https://www.auajournals.org/doi/10.1097/01.JU.0000556432.48421.1e>
268. Paz Rojas, J.F., *et al.* Effectiveness and safety of adjuvant chemotherapy compared to neoadjuvant chemotherapy in patients with penile cancer and positive lymph nodes regarding overall survival and free disease survival: a systematic review and meta-analysis. *Urol Oncol*, 2022. 40: 200.e11.
<https://pubmed.ncbi.nlm.nih.gov/35307290/>
269. Patel, A., *et al.* Updates in the use of radiotherapy in the management of primary and locally-advanced penile cancer. *Asian J Urol*, 2022. 9: 389.
<https://pubmed.ncbi.nlm.nih.gov/36381600/>
270. Hakenberg, O.W., *et al.* EAU guidelines on penile cancer: 2014 update. *Eur Urol*, 2015. 67: 142.
<https://pubmed.ncbi.nlm.nih.gov/25457021/>
271. Robinson, R., *et al.* Risks and Benefits of Adjuvant Radiotherapy After Inguinal Lymphadenectomy in Node-positive Penile Cancer: A Systematic Review by the European Association of Urology Penile Cancer Guidelines Panel. *Eur Urol*, 2018. 74: 76.
<https://pubmed.ncbi.nlm.nih.gov/29703686/>
272. Chen, M.F., *et al.* Contemporary management of penile cancer including surgery and adjuvant radiotherapy: an experience in Taiwan. *World J Urol*, 2004. 22: 60.
<https://pubmed.ncbi.nlm.nih.gov/14657999/>
273. Yuan, Z., *et al.* The relationship between HPV status and chemoradiotherapy in the locoregional control of penile cancer. *World J Urol*, 2018. 36: 1431.
<https://pubmed.ncbi.nlm.nih.gov/29589134/>
274. Jaipuria, J., *et al.* Adjuvant radiation compares favorably to chemotherapy in patients with carcinoma penis and nodal positivity restricted to groin. *Urol Oncol*, 2020. 38: 641.e9.
<https://pubmed.ncbi.nlm.nih.gov/32334927/>
275. Johnstone, P.A.S., *et al.* Primary Penile Cancer: The Role of Adjuvant Radiation Therapy in the Management of Extranodal Extension in Lymph Nodes. *Eur Urol Focus*, 2019. 5: 737.
<https://pubmed.ncbi.nlm.nih.gov/30327282/>
276. Ager, M., *et al.* Long-term multicentre experience of adjuvant radiotherapy for pN3 squamous cell carcinoma of the penis. *BJU Int*, 2021. 128: 451.
<https://pubmed.ncbi.nlm.nih.gov/33249744/>
277. Tang, D.H., *et al.* Adjuvant pelvic radiation is associated with improved survival and decreased disease recurrence in pelvic node-positive penile cancer after lymph node dissection: A multi-institutional study. *Urol Oncol*, 2017. 35: 605 e17.
<https://pubmed.ncbi.nlm.nih.gov/28666722/>
278. Yuan, Z., *et al.* Intrinsic radiosensitivity, genomic-based radiation dose and patterns of failure of penile cancer in response to adjuvant radiation therapy. *Rep Pract Oncol Radiother*, 2019. 24: 593.
<https://pubmed.ncbi.nlm.nih.gov/31719799/>

279. Yuan, Z., *et al.* Radiation therapy in the management of the inguinal region in penile cancer: What's the evidence? *Urol Oncol*, 2022. 40: 223.
<https://pubmed.ncbi.nlm.nih.gov/32482510/>
280. Winters, B.R., *et al.* Is there a benefit to adjuvant radiation in stage III penile cancer after lymph node dissection? Findings from the National Cancer Database. *Urol Oncol*, 2018. 36: 92.e11.
<https://pubmed.ncbi.nlm.nih.gov/29174944/>
281. Choo, R., *et al.* Is there any benefit in adding postoperative adjuvant concurrent radiotherapy and chemotherapy for penile cancer with regional lymph node metastasis? *Minerva Urol Nefrol*, 2020. 72: 474.
<https://pubmed.ncbi.nlm.nih.gov/31353875/>
282. Maibom, S.L., *et al.* DaPeCa-4: outcome in penile cancer patients with N3 disease due to extra nodal extension treated with surgery and chemo-irradiation. *Scand J Urol*, 2020. 54: 334.
<https://pubmed.ncbi.nlm.nih.gov/32734838/>
283. Haas, G.P., *et al.* Cisplatin, methotrexate and bleomycin for the treatment of carcinoma of the penis: a Southwest Oncology Group study. *J Urol*, 1999. 161: 1823.
<https://pubmed.ncbi.nlm.nih.gov/10332445/>
284. Di Lorenzo, G., *et al.* Cisplatin and 5-fluorouracil in inoperable, stage IV squamous cell carcinoma of the penis. *BJU Int*, 2012. 110: E661.
<https://pubmed.ncbi.nlm.nih.gov/22958571/>
285. Zhang, S., *et al.* Phase II study of docetaxel, cisplatin, and fluorouracil in patients with distantly metastatic penile cancer as first-line chemotherapy. *Oncotarget*, 2015. 6: 32212.
<https://pubmed.ncbi.nlm.nih.gov/26311739/>
286. Di Lorenzo, G., *et al.* Paclitaxel in pretreated metastatic penile cancer: final results of a phase 2 study. *Eur Urol*, 2011. 60: 1280.
<https://pubmed.ncbi.nlm.nih.gov/21871710/>
287. Liu, W.K., *et al.* Longitudinal cohort analysis of patients with metastatic penile cancer treated in a large quaternary academic centre. *J Clin Urol*, 2021.
<https://journals.sagepub.com/doi/full/10.1177/20514158211025913>
288. Wang, J., *et al.* Treatment for Metastatic Penile Cancer After First-line Chemotherapy Failure: Analysis of Response and Survival Outcomes. *Urology*, 2015. 85: 1104.
<https://pubmed.ncbi.nlm.nih.gov/25819619/>
289. Noronha, V., *et al.* Role of paclitaxel and platinum-based adjuvant chemotherapy in high-risk penile cancer. *Urol Ann*, 2012. 4: 150.
<https://pubmed.ncbi.nlm.nih.gov/23248520/>
290. Bermejo, C., *et al.* Neoadjuvant chemotherapy followed by aggressive surgical consolidation for metastatic penile squamous cell carcinoma. *J Urol*, 2007. 177: 1335.
<https://pubmed.ncbi.nlm.nih.gov/17382727/>
291. Joshi, V.B., *et al.* Immune-based therapies in penile cancer. *Nat Rev Urol*, 2022. 19: 457.
<https://pubmed.ncbi.nlm.nih.gov/35851333/>
292. Pouessel, D., *et al.* 715P: Nivolumab in pretreated metastatic penile squamous cell carcinoma: Results of the penile cohort from the French AcSé prospective program. *Ann Oncol*, 2021. 32: S720.
[https://www.annalsofoncology.org/article/S0923-7534\(21\)02325-5/fulltext](https://www.annalsofoncology.org/article/S0923-7534(21)02325-5/fulltext)
293. Vries, H.M.d., *et al.* Clinical results of PERICLES: A phase II trial investigating atezolizumab +/- radiotherapy for advanced squamous cell carcinoma of the penis. *J Clin Oncol*, 2022. 40: 3.
https://ascopubs.org/doi/abs/10.1200/JCO.2022.40.6_suppl.003
294. Apolo, A.B., *et al.* Phase I Study of Cabozantinib and Nivolumab Alone or With Ipilimumab for Advanced or Metastatic Urothelial Carcinoma and Other Genitourinary Tumors. *J Clin Oncol*, 2020. 38: 3672.
<https://pubmed.ncbi.nlm.nih.gov/32915679/>
295. McGregor, B.A., *et al.* Results of a multicenter, phase 2 study of nivolumab and ipilimumab for patients with advanced rare genitourinary malignancies. *Cancer*, 2021. 127: 840.
<https://pubmed.ncbi.nlm.nih.gov/33216356/>
296. Brown, A., *et al.* Epidermal growth factor receptor-targeted therapy in squamous cell carcinoma of the penis: a report of 3 cases. *Urology*, 2014. 83: 159.
<https://pubmed.ncbi.nlm.nih.gov/24238569/>
297. Carthon, B.C., *et al.* Epidermal growth factor receptor-targeted therapy in locally advanced or metastatic squamous cell carcinoma of the penis. *BJU Int*, 2014. 113: 871.
<https://pubmed.ncbi.nlm.nih.gov/24053151/>

298. Necchi, A., *et al.* Proof of activity of anti-epidermal growth factor receptor-targeted therapy for relapsed squamous cell carcinoma of the penis. *J Clin Oncol*, 2011. 29: e650.
<https://pubmed.ncbi.nlm.nih.gov/21632506/>
299. Necchi, A., *et al.* First-line therapy with dacomitinib, an orally available pan-HER tyrosine kinase inhibitor, for locally advanced or metastatic penile squamous cell carcinoma: results of an open-label, single-arm, single-centre, phase 2 study. *BJU Int*, 2018. 121: 348.
<https://pubmed.ncbi.nlm.nih.gov/28921872/>
300. Necchi, A., *et al.* Advanced Squamous Cell Carcinomas of the Pelvic and Perineal Region: A Comprehensive Genomic Profiling Study. *Oncologist*, 2022.
<https://pubmed.ncbi.nlm.nih.gov/35881043/>
301. Lutz, S.T., *et al.* Role of radiation therapy in palliative care of the patient with cancer. *J Clin Oncol*, 2014. 32: 2913.
<https://pubmed.ncbi.nlm.nih.gov/25113773/>
302. Brennan, J. Adjustment to cancer - coping or personal transition? *Psychooncology*, 2001. 10: 1.
<https://pubmed.ncbi.nlm.nih.gov/11180573/>
303. Horenblas, S., *et al.* Local recurrent tumour after penis-conserving therapy. A plea for long-term follow-up. *Br J Urol*, 1993. 72: 976.
<https://pubmed.ncbi.nlm.nih.gov/8306171/>
304. Branney, P., *et al.* The feasibility of patient reported outcome measures for the care of penile cancer. *Int J Urol Nurs*, 2022. 16: 138.
<https://onlinelibrary.wiley.com/doi/abs/10.1111/ijun.12307>
305. Ager, M., *et al.* MP49-15 - Surveillance CT algorithm for node positive squamous cell carcinoma of the penis. *J Urol*, 2019. 201: e711.
<https://www.researchgate.net/publication/332608124>
306. Arora, A., *et al.* A0694 - Patterns of recurrence in penile cancer: Implications for surveillance strategies. *Eur Urol*, 2022. 81: S1033.
<https://www.auajournals.org/doi/abs/10.1097/JU.0000000000002622.12>
307. Parnham, A.S., *et al.* Glansectomy and Split-thickness Skin Graft for Penile Cancer. *Eur Urol*, 2018. 73: 284.
<https://pubmed.ncbi.nlm.nih.gov/27746062/>
308. Djajadiningrat, R.S., *et al.* Ultrasound examination and fine needle aspiration cytology-useful for followup of the regional nodes in penile cancer? *J Urol*, 2014. 191: 652.
<https://pubmed.ncbi.nlm.nih.gov/23994372/>
309. Branney, P., *et al.* Mortality and sexuality after diagnosis of penile cancer: a participative study. *Int J Urol Nurs*, 2016. 10: 137.
<https://onlinelibrary.wiley.com/doi/abs/10.1111/ijun.12106>
310. Simpson, W.G., *et al.* Analysis of Suicide Risk in Patients with Penile Cancer and Review of the Literature. *Clin Genitourin Cancer*, 2018. 16: e257.
<https://pubmed.ncbi.nlm.nih.gov/29126815/>
311. Keeley, V., *et al.* A quality of life measure for limb lymphoedema (LYMQOL). *J Lymphoedema*, 2010. 5: 26.
https://www.woundsinternational.com/download/wint_article/7140
312. Rosen, R.C., *et al.* The international index of erectile function (IIEF): a multidimensional scale for assessment of erectile dysfunction. *Urology*, 1997. 49: 822.
<https://pubmed.ncbi.nlm.nih.gov/9187685/>
313. Ware, J.E., *et al.*, Conceptualization and Measurement of Health for Adults in the Health Insurance Study: Vol. I, Model of Health and Methodology. 1980, Santa Monica, CA, USA.
<https://www.rand.org/content/dam/rand/pubs/reports/2006/R1987.1.pdf>
314. (EORTC), EORTC QLQ-C30 (version 3). 2018. 2022.
<https://www.eortc.org/app/uploads/sites/2/2018/08/Specimen-QLQ-C30-English.pdf>
315. Draeger, D.L., *et al.* Cross-Sectional Patient-Reported Outcome Measuring of Health-Related Quality of Life With Establishment of Cancer- and Treatment-Specific Functional and Symptom Scales in Patients With Penile Cancer. *Clin Genitourin Cancer*, 2018. 16: e1215.
<https://pubmed.ncbi.nlm.nih.gov/30201215/>
316. Zigmond, A.S., *et al.* The hospital anxiety and depression scale. *Acta Psychiatr Scand*, 1983. 67: 361.
<https://pubmed.ncbi.nlm.nih.gov/6880820/>
317. Bigelow, D.A., *et al.* Quality of life of community mental health program clients: validating a measure. *Community Ment Health J*, 1991. 27: 43.
<https://pubmed.ncbi.nlm.nih.gov/2019098/>

318. Herbenick, D., et al. The development and validation of the Male Genital Self-Image Scale: results from a nationally representative probability sample of men in the United States. *J Sex Med*, 2013. 10: 1516. <https://pubmed.ncbi.nlm.nih.gov/23551571/>
319. Romero, F.R., et al. Sexual function after partial penectomy for penile cancer. *Urology*, 2005. 66: 1292. <https://pubmed.ncbi.nlm.nih.gov/16360459/>
320. D'Ancona, C.A., et al. Quality of life after partial penectomy for penile carcinoma. *Urology*, 1997. 50: 593. <https://pubmed.ncbi.nlm.nih.gov/9338738/>
321. Kieffer, J.M., et al. Quality of life for patients treated for penile cancer. *J Urol*, 2014. 192: 1105. <https://pubmed.ncbi.nlm.nih.gov/24747092/>
322. Ficarra, V., et al. General state of health and psychological well-being in patients after surgery for urological malignant neoplasms. *Urol Int*, 2000. 65: 130. <https://pubmed.ncbi.nlm.nih.gov/11054029/>
323. Sosnowski, R., et al. Assessment of quality of life in patients surgically treated for penile cancer: Impact of aggressiveness in surgery. *Eur J Oncol Nurs*, 2017. 31: 1. <https://pubmed.ncbi.nlm.nih.gov/29173821/>
324. Wan, X., et al. A Comparative study of two types of organ-sparing surgeries for early stage penile cancer: Wide local excision vs partial penectomy. *Eur J Surg Oncol*, 2018. 44: 1425. <https://pubmed.ncbi.nlm.nih.gov/29656798/>
325. Skeppner, E., et al. Treatment-seeking, aspects of sexual activity and life satisfaction in men with laser-treated penile carcinoma. *Eur Urol*, 2008. 54: 631. <https://pubmed.ncbi.nlm.nih.gov/18788122/>
326. Croghan, S.M., et al. Phallus Preservation in Penile Cancer Surgery: Patient-reported Aesthetic & Functional Outcomes. *Urology*, 2021. 152: 60. <https://pubmed.ncbi.nlm.nih.gov/33600836/>
327. Opjordsmoen, S., et al. Quality of life in patients treated for penile cancer. A follow-up study. *Br J Urol*, 1994. 74: 652. <https://pubmed.ncbi.nlm.nih.gov/7827818/>
328. Gulino, G., et al. Sexual outcomes after organ potency-sparing surgery and glans reconstruction in patients with penile carcinoma. *Indian J Urol*, 2013. 29: 119. <https://pubmed.ncbi.nlm.nih.gov/23956513/>
329. Carver, B.S., et al. Squamous cell carcinoma of the penis: a retrospective review of forty-five patients in northwest Louisiana. *South Med J*, 2002. 95: 822. <https://pubmed.ncbi.nlm.nih.gov/12190215/>
330. Lukowiak, T.M., et al. Mohs micrographic surgery for male genital tumors: Local recurrence rates and patient-reported outcomes. *J Am Acad Dermatol*, 2021. 84: 1030. <https://pubmed.ncbi.nlm.nih.gov/33279645/>
331. Sansalone, S., et al. Sexual outcomes after partial penectomy for penile cancer: results from a multi-institutional study. *Asian J Androl*, 2017. 19: 57. <https://pubmed.ncbi.nlm.nih.gov/26643562/>
332. Sosnowski, R., et al. Assessment of selected quality of life domains in patients who have undergone conservative or radical surgical treatment for penile cancer: an observational study. *Sex Health*, 2019. 16: 32. <https://pubmed.ncbi.nlm.nih.gov/30532994/>
333. Sedigh, O., et al. Sexual function after surgical treatment for penile cancer: Which organ-sparing approach gives the best results? *Can Urol Assoc J*, 2015. 9: E423. <https://pubmed.ncbi.nlm.nih.gov/26279710/>
334. Yang, J., et al. Glans-reconstruction with preputial flap is superior to primary closure for post-surgical restoration of male sexual function in glans-preserving surgery. *Andrology*, 2014. 2: 729. <https://pubmed.ncbi.nlm.nih.gov/24923484/>
335. Morelli, G., et al. Glansectomy with split-thickness skin graft for the treatment of penile carcinoma. *Int J Impot Res*, 2009. 21: 311. <https://pubmed.ncbi.nlm.nih.gov/19458620/>
336. O'Kane, H.F., et al. Outcome of glansectomy and skin grafting in the management of penile cancer. *Adv Urol*, 2011. 2011: 240824. <https://pubmed.ncbi.nlm.nih.gov/21603193/>
337. Palminteri, E., et al. Aesthetic neo-glans reconstruction after penis-sparing surgery for benign, premalignant or malignant penile lesions. *Arab J Urol*, 2011. 9: 115. <https://pubmed.ncbi.nlm.nih.gov/26579279/>

338. Li, J., *et al.* Organ-sparing surgery for penile cancer: complications and outcomes. *Urology*, 2011. 78: 1121.
<https://pubmed.ncbi.nlm.nih.gov/22054385/>
339. Preto, M., *et al.* Functional and Patient Reported Outcomes Following Total Glans Resurfacing. *J Sex Med*, 2021. 18: 1099.
<https://pubmed.ncbi.nlm.nih.gov/33935017/>
340. Monteiro, L.L., *et al.* Erectile function after partial penectomy for penile cancer. *Int Braz J Urol*, 2021. 47: 515.
<https://pubmed.ncbi.nlm.nih.gov/33620995/>
341. Crook, J.M., *et al.* Penile brachytherapy: results for 49 patients. *Int J Radiat Oncol Biol Phys*, 2005. 62: 460.
<https://pubmed.ncbi.nlm.nih.gov/15890588/>
342. Makarewicz, R., *et al.* Interstitial brachytherapy for penile cancer: the experience of Oncology Centre in Bydgoszcz. *J Contemp Brachyther*, 2010. 2: 157.
<https://pubmed.ncbi.nlm.nih.gov/27853477/>
343. Windahl, T., *et al.* Sexual function and satisfaction in men after laser treatment for penile carcinoma. *J Urol*, 2004. 172: 648.
<https://pubmed.ncbi.nlm.nih.gov/15247753/>
344. Yan, S., *et al.* Impact of lymphoedema on quality of life following radical lymph node dissection for penile cancer. *J. Clin Urol*, 2017. 10: 34.
<https://www.researchgate.net/publication/310833025>
345. Correa, A.F., *et al.* Differences in Survival Associated with Performance of Lymph Node Dissection in Patients with Invasive Penile Cancer: Results from the National Cancer Database. *J Urol*, 2018. 199: 1238.
<https://pubmed.ncbi.nlm.nih.gov/29248557/>
346. British Lymphology Society and The Lymphoedema Support Network, Guidelines on the Management of Cellulitis in Lymphoedema 2022. Access date January 2023.
https://www.lymphoedema.org/wp-content/uploads/2022/10/management_cellulitis.pdf
347. Scaglioni, M.F., *et al.* Systematic review of lymphovenous anastomosis (LVA) for the treatment of lymphedema. *Microsurgery*, 2017. 37: 947.
<https://pubmed.ncbi.nlm.nih.gov/28972280/>
348. Jakobsen, J.K., *et al.* Centralization and Equitable Care in Rare Urogenital Malignancies: The Case for Penile Cancer. *Eur Urol Focus*, 2021. 7: 924.
<https://pubmed.ncbi.nlm.nih.gov/34593356/>
349. Jakobsen, J.K., *et al.* DaPeCa-2: Implementation of fast-track clinical pathways for penile cancer shortens waiting time and accelerates the diagnostic process—A comparative before-and-after study in a tertiary referral centre in Denmark. *Scand J Urol*, 2016. 50: 80.
<https://pubmed.ncbi.nlm.nih.gov/26271679/>
350. Ayres, B.E., *et al.* 50 Has centralisation of penile cancer services in the United Kingdom improved survival? *Eur Urol Suppl*, 2014. 13: e50.
<https://www.sciencedirect.com/science/article/abs/pii/S156990561460052X?via%3Dihub>
351. Ottenhof, S.R., *et al.* A Prospective Study of Chemoradiotherapy as Primary Treatment in Patients With Locoregionally Advanced Penile Carcinoma. *Int J Radiat Oncol Biol Phys*. 2023 Sep 1;117(1):139-147.
[https://www.redjournal.org/article/S0360-3016\(23\)00310-3/fulltext](https://www.redjournal.org/article/S0360-3016(23)00310-3/fulltext)

9. CONFLICT OF INTEREST

All members of the EAU-ASCO Penile Cancer Guidelines working group have provided disclosure statements of all relationships that they have that might be perceived as a potential source of a conflict of interest. This information is publicly accessible through the European Association of Urology website: <http://uroweb.org/guideline/penile-cancer/>.

This guidelines document was developed with the financial support of the European Association of Urology. No external sources of funding and support have been involved. The EAU is a non-profit organisation and funding is limited to administrative assistance and travel and meeting expenses. No honoraria or other reimbursements have been provided.

10. CITATION INFORMATION

The format in which to cite the EAU Guidelines will vary depending on the style guide of the journal in which the citation appears. Accordingly, the number of authors or whether, for instance, to include the publisher, location, or an ISBN number may vary.

The compilation of the complete Guidelines should be referenced as:

EAU-ASCO Penile Cancer Guidelines. Edn. presented at the EAU Annual Congress Paris 2024. ISBN 978-94-92671-23-3.

If a publisher and/or location is required, include:

EAU Guidelines Office, Arnhem, The Netherlands. <http://uroweb.org/guidelines/compilations-of-all-guidelines/>

References to individual guidelines should be structured in the following way:

Contributors' names. Title of resource. Publication type. ISBN. Publisher and publisher location, year.