EAU GUIDELINES ON URETHRAL STRICTURES

(Limited text update April 2024)

N. Lumen (Chair), F. Campos-Juanatey, K. Dimitropoulos, T. Greenwell, F.E. Martins, N. Osman, A. Ploumidis, S. Riechardt, M. Waterloos
Guidelines Associates: R. Barratt, G. Chan, F. Esperto, W. Verla
Guidelines Office: R. Shepherd

Introduction

The European Association of Urology (EAU) Urethral Strictures Guidelines aim to provide a comprehensive overview of urethral strictures in male, female and transgender patients. In this Guideline, the Panel agreed to avoid the term "success" as this is poorly defined and subjective. Instead, the term "patency rate" or "stricture recurrence rate" are used to clarify that only stricture recurrence was taken into consideration.

Aetiology and Prevention

The following pathologies are frequent causes of urethral stricture disease in males:

- Sexually transmitted infection;
- Inflammation;
- External urethral trauma;
- Iatrogenic urethral injury: urethral catheterisation, transurethral prostate surgery, radical prostatectomy, prostate radiation and ablative treatments;
- Failed hypospadias repair;
- Congenital;
- Idiopathic.

Urethral stricture disease in females is mainly idiopathic. Other aetiologies are iatrogenic injury, trauma, infection and radiation therapy.

Recommendations	Strength rating
Advise safe sexual practices, recognise symptoms of sexually transmitted infection and provide access to prompt investigation and treatment for men with urethritis.	Strong
Avoid unnecessary urethral catheterisation.	Strong
Implement training programmes for physicians and nurses performing urinary catheterisation.	Strong
Do not use catheters larger than 18 Fr if urinary drainage only is the purpose.	Weak
Avoid using non-coated latex catheters.	Strong
Do not routinely perform urethrotomy when there is no pre-existent urethral stricture.	Strong

Classification

Classification according to stricture location will affect further management. The male urethra is divided into:

- Anterior urethra (surrounded by spongious tissue): meatus, penile urethra and bulbar urethra.
- Posterior urethra: membranous urethra, prostatic urethra and bladder neck.

For classification according to stricture tightness see Table 1.

Table 1: EAU classification according to the degree of urethral narrowing

Category	Description	Urethral lumen (French [Fr.])	Degree
0	Normal urethra on imaging	-	-
1	Subclinical strictures	Urethral narrowing but ≥ 16 Fr	Low
2	Low grade strictures	11-15 Fr	
3	High grade or flow significant strictures	4-10 Fr	High
4	Nearly obliterative strictures	1-3 Fr	
5	Obliterative strictures	No urethral lumen (0 Fr)	

Diagnostic Evaluation

History taking and physical examination

Recommendations	Strength rating
Use a validated patient reported outcome measure (PROM) to assess symptom severity and impact upon quality of life in men undergoing surgery for urethral stricture disease.	Strong
Use a validated tool to assess sexual function in men undergoing surgery for urethral stricture disease.	Strong

Further diagnostic evaluation

Figure 1: Diagnostic flowchart of patients with suspected urethral stricture disease

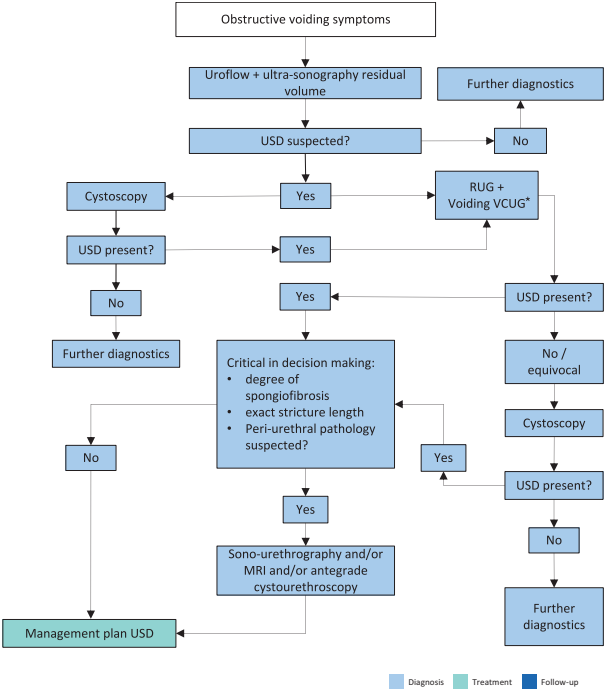

**Use VCUG in case of (nearly-) obliterative strictures or stenosis. MRI = magnetic resonance imaging; RUG = retrograde urethrography, USD = urethral stricture disease; VCUG = voiding cystourethrogram.*

Recommendations	Strength rating
Perform uroflowmetry and estimation of post-void residual in patients with suspected urethral stricture disease.	Strong
Perform retrograde urethrography (RUG) to assess stricture location and length in men with urethral stricture disease being considered for reconstructive surgery.	Strong
Combine RUG with voiding cystourethrography to assess (nearly)-obliterative strictures, stenoses and pelvic fracture urethral injuries (PFUI).	Strong
Use clamp devices in preference to the Foley catheter technique for urethrographic evaluation to reduce pain.	Weak
Perform cystourethroscopy as an adjunct to imaging if further information is required.	Weak
Combine RUG and antegrade cystoscopy to evaluate PFUI as an adjunct to imaging if further information is required.	Weak
Consider magnetic resonance imaging urethrography as an ancillary test in posterior urethral stenosis.	Strong

Disease Management In Males

Conservative treatment

Patients with a stricture or stricture recurrence (≥ 16 Fr) will rarely develop symptoms or need surgical intervention.

Recommendations	Strength rating
Do not intervene in patients with asymptomatic incidental (> 16 Fr) strictures.	Weak
Consider long-term suprapubic catheter in patients with radiation-induced bulbomembranous strictures and/or poor performance status.	Weak

Endoluminal treatment of anterior urethral strictures in males

Direct vision internal urethrotomy and dilatation

Direct vision internal urethrotomy (DVIU)/dilatation is commonly performed as first line treatment of non-obliterative urethral strictures. There is no difference in patency rate between dilatation and DVIU.

The best patency rates with DVIU/dilatation are reported among untreated patients with a single, short (max. 2 cm) bulbar stricture. Direct vision internal urethrotomy/dilatation performs poorly in penile and long segment strictures. Direct vision internal urethrotomy of the penile urethra might provoke venous leakage from the corpora cavernosa with subsequent risk of erectile dysfunction (ED).

Repetitive dilatations/DVIU have no long-term freedom of recurrence and might increase stricture complexity.

Recommendations	Strength rating
Do not use direct vision internal urethrotomy (DVIU) for penile strictures.	Strong
Do not use DVIU/dilatation as solitary treatment for long (> 2 cm) segment strictures.	Strong

Perform DVIU/dilatation for a primary, single, short (< 2 cm) and non-obliterative stricture at the bulbar urethra.	Weak
Perform DVIU/dilatation for a short, veil-like recurrent stricture after prior bulbar urethroplasty.	Weak
Use either "hot" or "cold" knife techniques to perform DVIU depending on operator experience and resources.	Weak
Use visually controlled dilatation in preference to blind dilatation.	Weak
Do not perform repetitive (> 2) DVIU/ dilatations if urethroplasty is a viable option.	Strong

Post-dilatation/direct vision internal urethrotomy strategies

Intermittent self-dilatation (ISD) is able to reduce stricture recurrence and need for reintervention but at the cost of impairment of quality of life (QoL) in a substantial proportion of patients. Intra-urethral corticosteroids via steroid ointment on the dilatator device in addition to ISD delay the time to recurrence.

Intralesional injections with steroids and mitomycin C (MMC) have been proposed to reduce stricture recurrence after DVIU. For steroid injections, there was no difference in recurrence rate although the time to recurrence was longer. Mitomycin C injection might reduce stricture recurrence although, anecdotally, severe complications have been reported.

Permanent stainless-steel mesh stents are no longer commercially available. Temporary stent insertion after DVIU/ dilatation prolongs time to recurrence for bulbar strictures. The use of stents in the penile urethra is anecdotal and appears to be associated with a higher recurrence rate.

Recommendations	Strength rating
Perform intermittent self-dilatation (ISD) to stabilise the stricture after dilatation/ direct vision internal urethrotomy (DVIU) if urethroplasty is not a viable option.	Weak
Use intra-urethral corticosteroids in addition to ISD to stabilise the urethral stricture.	Weak
Use intralesional injections only in the confines of a clinical trial.	Weak
Do not use permanent urethral stents.	Strong
Do not use urethral stents for penile strictures.	Strong
Use a temporary stent for recurrent bulbar strictures after DVIU to prolong time to next recurrence only if urethroplasty is not a viable option.	Weak

Drug-coated balloon dilation

Recommendation	Strength rating
Offer drug (paclitaxel)-coated balloon dilatation for a short (< 3cm) bulbar stricture recurring after at least two prior endoscopic treatments, but only in patients for whom urethroplasty is not an option.	Weak

Urethroplasty in males

The role of urethroplasty in the management of penile urethral strictures

Single-stage vs. staged augmentation urethroplasty vs. anastomotic urethroplasty

Staged augmentation urethroplasty is favoured in men with more complex urethral stricture disease (multiple

interventions in the past, unfavourable clinical findings such as significant spongiofibrosis or scarring that requires excision, poor quality of the urethral plate). In the absence of these factors, a single-stage approach might be possible.

Leave an interval of four to six months before proceeding to tubularisation of the urethra in the case of staged urethroplasty.

Revision (usually due to graft contracture) after the first stage has been reported in 0-20% of cases.

Anastomotic urethroplasty of the penile urethra is associated with a risk of chordee, especially if the stricture is longer than 1 cm.

Recommendations	Strength rating
Offer men with penile urethral stricture disease augmentation urethroplasty by either a single-stage or staged approach taking into consideration previous interventions and stricture characteristics.	Strong
Offer an interval of at least four to six months before proceeding to the second stage of the procedure provided that the outcome of the first stage is satisfactory.	Weak
Do not offer anastomotic urethroplasty to patients with penile strictures > 1 cm due to the risk of penile chordee post-operatively.	Strong
Counsel patients with penile strictures that single-stage procedures might be converted to staged ones in the face of adverse intra-operative findings.	Strong

Specific considerations for failed hypospadias repair-related and lichen sclerosus-related strictures

The management of failed hypospadias repair is challenging and complex as the urethral plate, penile skin and dartos fascia are often deficient/non-existent.

Given the fact that lichen sclerosus (LS) affects the skin, the use of genital skin as a flap or graft is not advised.

Recommendations	Strength rating
Men with failed hypospadias repair (FHR) should be considered complex patients and referred to specialist centres for further management.	Weak
Propose psychological and/or psychosexual counselling to men with unsatisfactory cosmesis and sexual or urinary dysfunction related to FHR.	Weak
Do not use penile skin grafts or flaps in failed FHR patients with lichen sclerosus (LS) or scarred skin.	Strong
Do not use genital skin in augmentation penile urethroplasty in men with LS-related strictures.	Strong
Perform single-stage oral mucosal graft urethroplasty in the absence of adverse local conditions in men with LS-related strictures.	Weak

Distal urethral strictures (meatal stenosis, fossa navicularis strictures)

Open repair of distal urethral strictures can be in the form of Malone meatoplasty, skin flap meatoplasty or graft (skin [SG]/ oral mucosal graft [OMG]) urethroplasty.

Recommendation	Strength rating
Offer open meatoplasty or distal urethroplasty to patients with meatal stenosis or fossa navicularis/distal urethral strictures.	Weak

Urethroplasty for bulbar strictures

Shorter bulbar strictures

"Short" bulbar strictures are those amenable to excision and primary anastomosis (EPA), with a limit of around 2-3 cm.

Recommendations	Strength rating
Use transecting excision and primary anastomosis (tEPA) for short post-traumatic bulbar strictures with (nearly) complete obliteration of the lumen and full thickness spongiofibrosis.	Strong
Use non-transecting excision and primary anastomosis or free graft urethroplasty instead of tEPA for short bulbar strictures not related to straddle injury.	Weak

"Longer" bulbar strictures

Free graft urethroplasty

There is insufficient evidence to routinely recommend the nerve- and muscle-sparing modifications of bulbar urethroplasty.

Recommendations	Strength rating
Use free graft urethroplasty for bulbar strictures not amendable to excision and primary anastomosis (EPA).	Strong

Use oral mucosa free graft urethroplasty for ReDo urethroplasty in the case of a long stricture.	Strong
Use augmented anastomotic repair for bulbar strictures not amenable to EPA but with a short, nearly obliterative segment within the whole strictured segment.	Weak
Use dorsal, dorsal-lateral or ventral approach according to surgical practice, expertise and intra-operative findings.	Strong

Staged urethroplasty for bulbar urethral strictures

Staged urethroplasty may be considered when:

- there are locally adverse conditions such as fistula, false passage, abscess or cancer;
- there has been a previously unsuccessful complex urethroplasty including failed hypospadias repair;
- there is a lack of certainty on behalf of the surgeon regarding the most appropriate form of urethroplasty for the patient;
- the stricture is radiotherapy induced;
- the stricture is consequent to LS (this is controversial and for some groups LS is a contraindication for a staged urethroplasty);
- severe spongiofibrosis.

Late complications of first-stage urethroplasty include a need for revision in up to 19% - consequent to recurrence of LS in graft(s) (8.8%), graft contracture (6.6%) and stomal stenosis (3.3%).

Recommendations	Strength rating
Offer staged urethroplasty to men with complex anterior urethral stricture disease not suitable for single stage urethroplasty and who are fit for reconstruction.	Weak
Do not perform staged bulbar urethroplasty for lichen sclerosis if single stage urethroplasty is possible.	Weak
Consider staged procedure in patients unsure about perineal urethrostomy versus urethral reconstruction.	Weak
Warn men that staged urethroplasty may comprise more than two stages.	Weak

Urethroplasty for penobulbar or panurethral strictures

Generally, only high-volume centres publish series on panurethral urethroplasties. Alternative techniques and grafts may be required.

Recommendations	Strength rating
Offer panurethral urethroplasties in specialised centres because different techniques and materials might be needed.	Weak
Combine techniques to treat panurethral strictures if one technique is not able to treat the whole extent of the stricture.	Weak

Perineal urethrostomy

Perineal urethrostomy (PU) offers a permanent or temporary solution for restoration of voiding in men with complex urethral stricture disease in whom:

- there are no further options to restore urethral patency either due to multiple previous failed urethroplasties or multiple co-morbidities precluding a more expansive surgical undertaking after failed endoscopic management;
- there is a lack of certainty on behalf of the surgeon regarding the most appropriate form of urethroplasty for the patient;
- following urethrectomy and/or penectomy for cancer.

Recommendations	Strength rating
Offer perineal urethrostomy (PU) as a management option to men with complex anterior urethral stricture disease.	Strong
Offer PU to men with anterior urethral stricture disease who are not fit or not willing to undergo formal reconstruction.	Weak
Choose type of PU based on personal experience and patient characteristics.	Weak
Consider augmented Gil-Vernet-Blandy PU or "7-flap" PU in men with proximal bulbar or membranous urethral stricture disease.	Weak
Consider "7-flap" urethroplasty in obese men.	Weak

Posterior urethra

Non-traumatic posterior urethral stenosis

Endoluminal management of non-traumatic posterior urethral stenosis

Endoluminal treatment of complete obliterative strictures is not advised because of a very low likelihood of durable patency and the risk of false passage towards the rectum.

Recommendations	Strength rating
Perform visually controlled dilatation or direct vision internal urethrotomy (DVIU) as 1st line-treatment for a non-obliterative vesico-urethral anastomosis stricture (VUAS) or radiation-induced bulbomembranous strictures (BMS).	Weak
Do not perform deep incisions at the 6 and 12 o' clock position during DVIU for VUAS or radiation-induced BMS.	Strong
Perform transurethral resection (TUR) or "hot-knife" DVIU as 1st line-treatment for patients with non-obliterative bladder neck stenosis (BNS) after surgery for benign prostatic obstruction.	Strong
Perform repeat endoluminal treatments in non-obliterative VUAS or BNS in an attempt to stabilise the stricture.	Weak
Warn patients about the risk of *de novo* urinary incontinence or exacerbation of existing urinary incontinence after endoluminal treatment.	Weak
Do not perform endoluminal treatment in case of VUAS, BMS and BNS with complete obliteration.	Strong
Do not use stents for strictures at the posterior urethra.	Weak

Lower urinary tract reconstruction for non-traumatic posterior urethral stenosis

De novo urinary incontinence (UI) with transperineal ReDo vesico-urethral anastomosis (VUA) is universal and artificial urinary sphincter placement can be offered after three to six months. *De novo* UI with retropubic ReDo VUA is 0-58%.

Urinary incontinence rates are up to 14% with bladder neck reconstruction and up to 25% after reconstruction of bulbomembranous strictures (BMS) after surgery for benign prostatic obstruction (BPO).
De novo UI and new onset ED after urethral surgery for radiation-induced BMS are reported in 11-50% and 0-35% of cases, respectively.

Salvage prostatectomy is able to achieve patency in 67% of patients for prostatic strictures after irradiation or high-energy treatments but morbidity is substantial.

Figure 2: Options for lower urinary tract reconstruction of non-traumatic posterior urethral obstruction (stenosis/stricture)

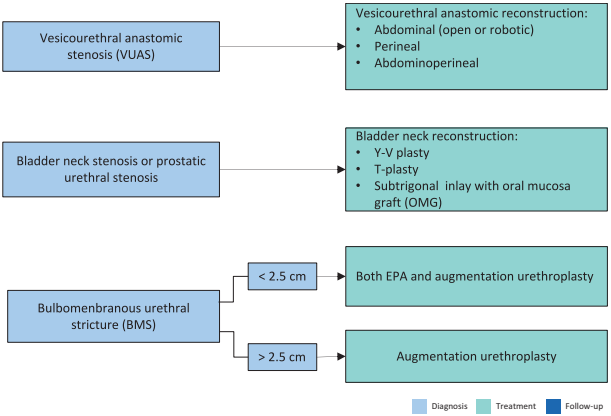

Recommendations	Strength rating
Perform ReDo vesico-urethral anastomosis (VUA) in non-irradiated patients and irradiated patients with adequate bladder function with obliterative vesico-urethral anastomosis stricture or vesico-urethral anastomosis stricture refractory to endoluminal treatment.	Weak
Warn patient that urinary incontinence (UI) is inevitable after transperineal ReDo VUA and that subsequent anti-UI surgery might be needed in a next stage, after at least three to six months.	Strong
Offer ReDo VUA by retropubic approach if the patient is pre-operatively continent.	Weak
Perform bladder neck reconstruction with Y-V or T-plasty for treatment refractory bladder neck stenosis (BNS).	Weak
Warn patients about *de novo* UI after reconstruction for BNS or bulbomembranous strictures (BMS) with previous benign prostatic obstruction surgery as aetiology.	Strong
Use either excision and primary anastomosis or augmentation urethroplasty for short (< 2.5 cm) radiation-induced BMS refractory to endoscopic treatment depending on surgeon's experience.	Weak
Perform augmentation urethroplasty for long (> 2.5 cm) radiation-induced BMS.	Weak
Warn patients about the risk of *de novo* UI and new onset erectile dysfunction after urethroplasty for radiation-induced BMS.	Strong

Offer salvage prostatectomy in motivated and fit patients with adequate bladder function in case of a prostatic stricture due to prior irradiation or high-energy treatment.	Weak

Extirpative surgery and urinary diversion for non-traumatic posterior urethral stenosis

This is reserved for complex and/or recurrent cases associated with severe necrosis, calcification and significant morbidity, especially severe pain, intractable haematuria or fistulation.

Recommendations	Strength rating
Perform urinary diversion in recurrent or complex cases with loss of bladder capacity and/or incapacitating local symptoms.	Weak
Perform cystectomy during urinary diversion in case of intractable bladder pain, spasms and/or haematuria.	Weak

Post-traumatic posterior stenosis

The acute and early management of pelvic fracture urethral injuries (PFUIs) is discussed in the EAU Guidelines on Urological Trauma. The deferred management of PFUI is at earliest three months after the trauma at the time a stable post-traumatic posterior stenosis has been formed.

Endoluminal treatment for post-traumatic posterior stenosis

Endoluminal treatment of an obliterative stenosis will not be successful and has a risk of creating a false passage towards the bladder base or rectum.

Endoluminal treatment of short (≤ 1.5 cm), non-obliterative stenoses has a 20-96.5% stricture-free rate, with a 4% *de novo* UI rate.

Direct vision internal urethrotomy has stricture-free rates of 22.9-77.3% for a short and non-obliterative recurrence after EPA.

Recommendations	Strength rating
Do not perform endoscopic treatment for an obliterative stenosis.	Strong
Perform one attempt at endoluminal treatment for a short, non-obliterative stenosis.	Weak
Do not perform more than two direct vision internal urethrotomies and/or dilatations for a short and non-obliterative recurrence after excision and primary anastomosis for a traumatic posterior stenosis if long-term urethral patency is the desired intent.	Weak

Urethroplasty for post-traumatic posterior stenosis

It has been calculated that to achieve and maintain sufficient experience in the reconstruction of PFUI, one centre per twelve million inhabitants is sufficient (for well-resourced countries).

In case of a recurrent stenosis, a repeat ("ReDo") urethroplasty is possible in motivated patients. Several different types of urethroplasty have been described for this with a 37.5-100% patency rate.

Recommendations	Strength rating
Perform open reconstruction for post-traumatic posterior stenosis only in high-volume centres.	Weak

Perform progressive perineal excision and primary anastomosis (EPA) for obliterative stenosis.	Strong
Perform progressive perineal EPA for non-obliterative stenosis after failed endoluminal treatment.	Strong
Perform a midline perineal incision to gain access to the posterior urethra.	Strong
Do not perform total pubectomy during abdomino-perineal reconstruction.	Strong
Reserve abdomino-perineal reconstruction for complicated situations including very long distraction defect, para-urethral bladder base fistula, trauma-related rectourethral fistula, and bladder neck injury.	Weak
Perform another urethroplasty after 1st failed urethroplasty in motivated patients not willing to accept palliative endoluminal treatments or urinary diversion.	Weak
Use a local tissue flap to fill up excessive dead space or after correction of a concomitant recto-urethral fistula.	Weak

Female Urethral Strictures

Female urethral stricture (FUS) symptoms are long-standing and non-specific but most commonly reported are frequency, urgency, poor flow, incomplete emptying and UI. It is important to exclude FUS in female patients with lower urinary tract symptoms.

It is important to assess flow rate and post-void residuals. All suspected of having FUS should have voiding cystourethrography (VCUG) or video-urodynamics (VUDS) to confirm the diagnosis.

Recommendations	Strength rating
Perform flow rate, post-void residual and voiding cystourethrogram or video-urodynamics in all women with refractory lower urinary tract symptoms.	Strong
Perform urethral dilatation to 24-41 Fr as initial treatment of female urethral stricture (FUS).	Weak
Perform repeat urethral dilatation and start planned weekly intermittent self-dilatation (ISD) with a 16-18 Fr catheter for the 1st recurrence of FUS, or plan repeat dilation.	Weak
Perform urethroplasty in women with a 2nd recurrence of FUS and who cannot perform ISD or wish definitive treatment. The technique for urethroplasty should be determined by the surgeon's experience, availability and quality of graft/flap material, and the quality of the ventral vs. dorsal urethra.	Strong
Treat meatal strictures by meatotomy/ meatoplasty.	Weak

Disease Management In Transgender Patients

In transmen, stricture treatment depends on the time after neophallic reconstruction, stricture location, stricture length and quality of local tissues. Endoscopic incision has been performed for short (< 3 cm) strictures in transmen, usually at the anastomotic site with a 45.5% patency rate. Endoscopic incision shortly after neophallic reconstruction and repetitive incisions are not successful. After failure of endoscopic incision or in case of a (nearly-) obliterative short stricture at the anastomosis, excision and primary anastomosis has

been proposed with a 57.1% patency rate. Strictures of the neophallic urethra are usually treated with staged urethroplasty (+/- graft augmentation).

In transwomen, it is acceptable to start with dilatation of a short and non-obliterative stricture. If this is not possible or if it fails, a short (< 1 cm) meatal stricture can be treated by Y-V meatoplasty with an 85% stricture-free rate. Somewhat longer (1-2 cm) meatal strictures can be treated by a neovaginal advancement flap.

Recommendations	Strength rating
Do not perform endoscopic incision or urethroplasty within six months after neophalloplasty.	Strong
Do not perform more than two endoscopic incisions for strictures in transmen unless with palliative intent.	Strong
Perform staged urethroplasty for strictures at the neophallic urethra if open reconstruction is indicated.	Weak
Perform Y-V meatoplasty for short (< 1 cm) meatal stenosis in transwomen if open reconstruction is indicated.	Weak

Tissue Transfer

Different local flaps have been described: penile skin, perineal and scrotal flaps (hair-bearing). Flaps have a higher urogenital morbidity but a comparable patency rate compared to grafts. When complete tubularisation is needed in a single stage approach, grafts have a significantly higher complication rate compared to flaps. Hair-bearing flaps have a lower urethral patency rate compared to non-hair-bearing flaps.

Possible grafts are oral mucosa, penile skin, and a multitude of other autologous grafts. Patency rates of buccal mucosa and lingual mucosa are comparable. Different types of oral grafts have different types of oral morbidity and some of the oral complications might persist in the long-term. Patency rates with penile skin grafts are 79-81.8% vs. 85.9-88.1% with buccal mucosa. In LS-related strictures, the use of genital skin graft is associated with poor patency rates (4%).

The post-operative morbidity of closure vs. non-closure of the buccal mucosa harvesting site has been evaluated and no clear recommendation can be provided whether or not to close the harvesting site.

Recommendations	Strength rating
Use a graft above a flap when both are equally indicated.	Strong
Do not use grafts in a tubularised fashion in a single-stage approach.	Strong
Use flaps in case of poor vascularisation of the urethral bed.	Weak
Do not use hair-bearing perineal or scrotal flaps unless no other option is feasible.	Strong
Use buccal or lingual mucosa if a graft is needed and these grafts are available.	Weak
Inform the patient about the potential complications of the different types of oral grafting (buccal versus lingual versus lower lip) when an oral graft is proposed.	Strong
Use penile skin if buccal/lingual mucosa is not available, suitable, or accepted by the patient for reconstruction.	Weak

Do not use genital skin graft in case of lichen sclerosus.	Strong
Do not use cell-free tissue engineered grafts in case of extensive spongiofibrosis, after failed previous urethroplasty or stricture length > 4 cm.	Weak
Do not use autologous tissue-engineered oral mucosa grafts outside the frame of a clinical trial.	Strong

Peri-Operative Care Of Urethral Surgery

After any form of urethral manipulation (urethral catheter, ISD, dilatation, DVIU), a period of urethral rest is necessary in order to allow tissue recovery and stricture "maturation" before considering urethroplasty.

A urine culture is performed one to two weeks prior to surgery and if infection is present, a therapeutic course with antibiotics is recommended pre-operatively. An intra-operative prophylactic regimen with antibiotics is effective in reducing the rate of post-operative surgical site infection and UTIs.

Prior to catheter removal after urethroplasty, it is important to assess for urinary extravasation to avoid ensuing complications including peri-urethral inflammation, abscess formation and fistulation.

Recommendations	Strength rating
Do not perform urethroplasty within three months of any form of urethral manipulation.	Weak
Administer an intra-operative prophylactic regimen with antibiotics at the time of urethral surgery.	Strong

Perform a form of validated urethrography after urethroplasty to assess for urinary extravasation prior to catheter removal.	Strong
Remove the catheter within 72 hours after uncomplicated direct vision internal urethrotomy or urethral dilatation.	Weak
Consider 1st urethrography seven to ten days after uncomplicated urethroplasty to assess whether catheter removal is possible, especially in patients with bother from their urethral catheter.	Weak

Follow-Up

After urethroplasty surgery, recurrent strictures appear with different frequency depending on stricture features and urethroplasty techniques.

Follow-up, should not only focus on detection of stricture recurrence but should also assess functional outcomes and patient satisfaction.

The same tools used for the primary diagnosis of urethral stricture disease can be used to detect stricture recurrence (Figure 3).

The majority of stricture recurrences present within one year after surgery although late recurrences are possible, especially after augmentation urethroplasty. Risk-adapted follow-up protocols are cost-effective and safe for the patients (Tables 2 and 3).

Figure 3: Follow-up after urethroplasty

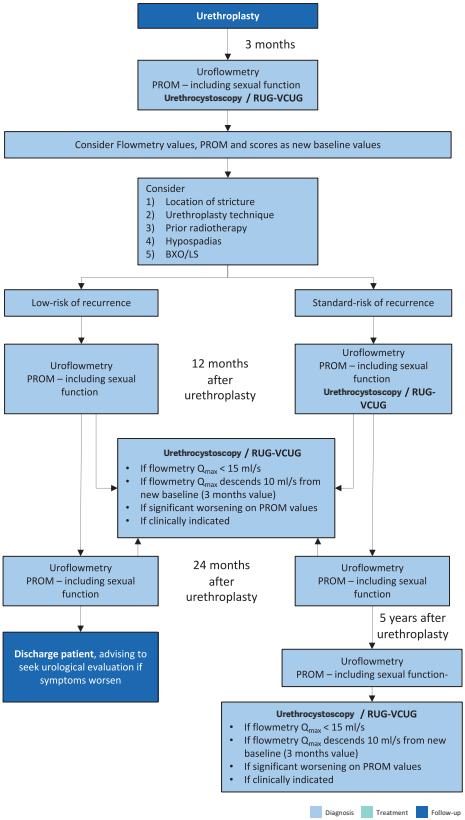

BXO = balanitis xerotica obliterans; LS = lichen sclerosus; PROM = patient reported outcome measure; Q_{max} = maximum flow rate; RUG = retrograde urethrography; VCUG = voiding cystourethrography.

Table 2: Follow-up protocol for urethroplasty with low risk of recurrence

- Anastomotic urethroplasties in the bulbar/(bulbo) membranous segment with no history of radiotherapy, hypospadias or balanitis xerotica obliterans (BXO)/LS features.

Surgery	3 months	12 months	24 months*
Uroflowmetry	+	+	+
PROM (incl. sexual function)	+	+	+
Anatomic evaluation: (Urethrocystoscopy/RUG-VCUG)	+**	On indication	On indication

**Follow-up could be discontinued after two years, advising the patient to seek urological evaluation if symptoms worsen. Academic centres could increase the length of follow-up for research purposes.*

***The Panel suggests performing an anatomic assessment at three months.*

Table 3: Follow-up protocol for urethroplasty with standard risk of recurrence

- Anastomotic urethroplasties in the bulbar segment with prior history of radiotherapy, hypospadias or BXO/LS features;
- Penile urethroplasties;
- Non-traumatic posterior urethroplasties;
- Graft or/and flap – substitution – urethroplasties.

Surgery	3 months	12 months	24 months	5 years *
Uroflowmetry	+	+	+	+
PROM (incl. sexual function)	+	+	+	+
Anatomic evaluation: (Urethrocystoscopy/ RUG-VCUG)	+	+	+	On indication

**Follow-up could be discontinued after five years, advising the patient to seek urological evaluation if symptoms worsen. A longer follow-up period should be considered after penile and substitution urethroplasties. Academic centres could increase the length of follow-up for research purposes.*

Recommendations	Strength rating
Offer follow-up to all patients after urethroplasty surgery.	Strong
Use cystoscopy or retrograde urethrography to assess anatomic success after urethroplasty surgery.	Weak
Use patient-reported outcome measures (PROM) questionnaires to assess subjective outcomes and patient satisfaction.	Strong
Use validated questionnaires to evaluate sexual function after urethral stricture surgeries.	Strong
Offer a routine follow-up of at least one year after urethroplasty.	Strong
Adopt a risk-adjusted follow-up protocol.	Weak

This short booklet text is based on the more comprehensive EAU Guidelines (ISBN 978-94-92671-29-5) available on the EAU website, http://www.uroweb.org/guidelines/.