EAU GUIDELINES ON TESTICULAR CANCER

(Limited text update April 2024)

D. Nicol (Chair), D. M. Berney, J.L. Boormans, D. di Nardo (Patient advocate), C.D. Fankhauser, S. Fischer, H. Gremmels (Patient advocate), A. Heidenreich, R. Leão, N. Nicolai, C. Oing, A. Patrikidou, T. Tandstad, R. Cornes (patient advocate) A. Papachristofilou, H.S. Haugnes
Guidelines Associates: I. de Angst, W. Cazzaniga, C. Gravina, F. Janisch
Consultant radiologist: Y. Jain
Guidelines Office: C. Bezuidenhout

Introduction

Epidemiology, aetiology and pathology

Testicular cancer (TC) represents 1% of adult neoplasms and 5% of urological tumours. At diagnosis, 1-2% are bilateral and 90-95% of cases are germ cell tumours (GCT).

Most malignant post-pubertal GCTs originate from germ cell neoplasia "in situ" (GCNIS). Histologically and clinically, these are subdivided into seminomas and non-seminomas, the latter encompassing somatic and extra-embryonal elements of embryonal carcinoma, yolk sac, choriocarcinoma and post-pubertal teratoma. Non-GCNIS derived tumours include pre-pubertal type teratoma and yolk sac tumour, which occur in early childhood, and spermatocytic tumours which usually occurs in older men.

Peak incidence is in the third decade of life for non-seminoma testis (NST) and mixed GCT patients, and fourth decade for pure seminoma testis (ST) patients. Epidemiological

risk factors for the development of TC are components of testicular dysgenesis syndrome, which encompasses cryptorchidism, hypospadias, decreased spermatogenesis evidenced by sub- or infertility, or disorders/differences of sex development. Additional risk factors include family history TC among first-grade relatives, and the presence of a contralateral tumour, or GCNIS.

Histological classification

The recommended pathological classification shown below is based on the 2022 update of the World Health Organization (WHO) pathological classification.

Staging and classification systems

Staging systems

The 2016 Tumour, Node, Metastasis (TNM) classification of the International Union Against Cancer (UICC) is recommended to assess the anatomical extent of the disease (Table 1).

Table 1: TNM classification for testicular cancer (adapted from UICC, 2016, 8th edn.)

T - Primary Tumour[1]	
pTX	Primary tumour cannot be assessed (see note[1])
pT0	No evidence of primary tumour (e.g., histological scar in testis)
pTis	Intratubular germ cell neoplasia (carcinoma *in situ*)+
pT1	Tumour limited to testis (including rete testis) and epididymis without vascular/lymphatic invasion and without invasion of the epididymis*#
pT2	Tumour limited to testis with vascular/lymphatic invasion, or invading hilar soft tissue or the epididymis or tumour extending through tunica albuginea with involvement of visceral tunica vaginalis**#

pT3	Tumour invades spermatic cord with or without vascular/lymphatic invasion**
pT4	Tumour invades scrotum with or without vascular/ lymphatic invasion
N - Regional Lymph Nodes - Clinical	
NX	Regional lymph nodes cannot be assessed
N0	No regional lymph node metastasis
N1	Metastasis with a lymph node mass 2 cm or less in greatest dimension or multiple lymph nodes, none more than 2 cm in greatest dimension
N2	Metastasis with a lymph node mass more than 2 cm but not more than 5 cm in greatest dimension; or more than 5 nodes positive, none more than 5 cm; or evidence of extranodal extension of tumour
N3	Metastasis with a lymph node mass more than 5 cm in greatest dimension
Pn - Regional Lymph Nodes - Pathological	
pNX	Regional lymph nodes cannot be assessed
pN0	No regional lymph node metastasis
pN1	Metastasis with a lymph node mass 2 cm or less in greatest dimension and 5 or fewer positive nodes, none more than 2 cm in greatest dimension
pN2	Metastasis with a lymph node mass more than 2 cm but not more than 5 cm in greatest dimension; or more than 5 nodes positive, none more than 5 cm; or evidence of extranodal extension of tumour
pN3	Metastasis with a lymph node mass more than 5 cm in greatest dimension
M - Distant Metastasis	
MX	Distant metastasis cannot be assessed
M0	No distant metastasis
M1	Distant metastasis**

	M1a Non-regional lymph node(s) or lung metastasis		
	M1b Distant metastasis other than non-regional lymph nodes and lung		
S - Serum tumour markers (Pre-chemotherapy)			
SX	Serum marker studies not available or not performed		
S0	Serum marker study levels within normal limits		
	LDH (U/l)	**β- hCG (mIU/mL)**	**AFP (ng/mL)**
S1	< 1.5 x N and	< 5,000 and	< 1,000
S2	1.5-10 x N or	5,000-50,000 or	1,000-10,000
S3	> 10 x N or	50,000 or	> 10,000

N indicates the upper limit of normal.
LDH = lactate dehydrogenase; hCG = human chorionic gonadotrophin; AFP = alpha-fetoprotein.
[1] *Except for pTis and pT4, where radical orchidectomy is not always necessary for classification purposes, the extent of the primary tumour is classified after radical orchidectomy; see pT. In other circumstances, Tx is used if no radical orchidectomy has been performed.*
[+] *The current "carcinoma in situ" nomenclature is replaced by GCNIS.*
[*] *AJCC 8th edition subdivides T1 Pure Seminoma by T1a and T1b depending on size no greater than 3 cm or greater than 3 cm in greatest dimension.*
[**] *AJCC 8th edition considers the hilar soft tissue invasion as pT2, while the discontinuous involvement of the spermatic cord is considered as pM1.*
[#] *As updated in the UICC 8th Edition Errata*

The International Germ Cell Cancer Collaborative Group (IGCCCG) defined a prognostic factor-based staging system for metastatic germ cell cancer that includes 'good' and 'intermediate' prognosis seminoma germ cell tumour (SGCT) and 'good', 'intermediate', and 'poor' prognosis non-seminomatous germ cell tumour (NSGCT) (Table 2).

The IGCCCG for metastatic testicular cancer

A prognostic risk factor-based staging system is widely used for metastatic TC based on identification of clinically independent adverse factors.

Table 2: Prognostic-based staging system for metastatic germ cell cancer (IGCCCG)*

Good-prognosis group	
NSGCT 5-year PFS 90% 5-year survival 96%	*All of the following criteria:* • Testis/retro-peritoneal primary • No non-pulmonary visceral metastases • AFP < 1,000 ng/mL • β-hCG < 5,000 IU/L (1,000 ng/mL) • LDH < 1.5 x ULN
SGCT 5-year PFS 89% 5-year survival 95%	*All of the following criteria:* • Any primary site • No non-pulmonary visceral metastases • Normal AFP • Any β-hCG • Any LDH
Intermediate-prognosis group	
NSGCT 5-year PFS 78% 5-year survival 89%	*Any of the following criteria:* • Testis/retro-peritoneal primary • No non-pulmonary visceral metastases • AFP 1,000 - 10,000 ng/mL or • β-hCG 5,000 - 50,000 IU/L or • LDH 1.5 - 10 x ULN

SGCT 5-year PFS 79% 5-year survival 88%	*All of the following criteria:* • Any primary site Non-pulmonary visceral metastases • Normal AFP • Any β-hCG • Any LDH
Poor-prognosis group	
NSGCT 5-year PFS 54% 5-year survival 67%	*Any of the following criteria:* • Mediastinal primary • Non-pulmonary visceral metastases • AFP > 10,000 ng/mL or • β-hCG > 50,000 IU/L (10,000 ng/mL) or • LDH > 10 x ULN
SGCT	No patients classified as poor-prognosis

** Pre-chemotherapy serum tumour markers should be assessed immediately prior to the administration of chemotherapy (same day).*
AFP = alpha-fetoprotein; hCG = human chorionic gonadotrophin; LDH = lactate dehydrogenase;
NSGCT = non-seminomatous germ cell tumour; PFS = progression-free survival; SGCT = seminoma germ cell tumour.

Diagnostic evaluation

1. ***Physical examination***
   Testicular cancer usually presents as a painless testicular mass or incidental finding on ultrasound (US). Pain, either scrotal or abdominal/back, may occur and result

in delayed diagnosis. Gynaecomastia may be present in a small number of patients. Clinical assessment should thus include abdominal, chest and supraclavicular examination.

2. ***Imaging***

   a. Primary Tumour

   The primary tumour and contralateral testis need to be assessed radiologically to

   i. confirm the presence of a mass;
   ii. determine whether it is intra- or extra-testicular;
   iii. assess its volume and anatomical location;
   iv. characterise the contralateral testicle – to exclude other lesions and identify risk factors for GCNIS (see section 5.4.4).

   High-frequency (>10 MHz) testicular US is recommended. Scrotal US is also recommended for all men with retroperitoneal or visceral masses with/or without elevated serum β-hCG or Alpha-fetoprotein (AFP) in the absence of a palpable testicular mass.

   Small, usually non-palpable incidental masses may be incidental findings on scrotal US which may be benign. Of lesions with small diameter virtually all < 3mm, 87% of those < 5mm and 70% < 10mm are benign. With small masses US features may assist in discriminating between benign and malignant tumours although none are completely reliable.

   Scrotal magnetic resonance imaging (MRI) provides higher sensitivity and specificity than US in the diagnosis of TC, but its high cost does not justify its routine use for this purpose. It should only be considered when US is inconclusive as local staging for potential testis-sparing surgery (TSS), to differentiate between paratesticular

and intratesticular lesions, and/or to characterise intratesticular masses (e.g., distinctive features of Leydig tumours)

b. Staging
Cross-sectional imaging of the chest, abdomen and pelvis is recommended This may be postponed in patients with small or indeterminant masses until histopathological confirmation of malignancy. Contrast enhanced CT scan (CECT) and MRI are the imaging modalities used. Evidence does not support the use of Fluorodeoxyglucose-positron emission tomography (FDG-PET) for initial staging of TC.

I. Thorax, Abdomen and Pelvis
   Contrast enhanced CT scan is used to identify nodal and visceral metastases. The size of metastases should be described in three dimensions, or at least by the greatest diameter. MRI appears comparable to CECT for the abdomen and pelvis but is significantly more expensive and less available. MRI is less sensitive than CECT and is not recommended as a routine alternative to CT.

II. Other Sites
   Cerebral and spinal imaging is recommended in GCT patients with either multiple lung metastases or poor-prognosis IGCCCG risk group or clinical symptoms. Data from cerebral and spinal metastasis detection in other malignancies suggest that MRI is far more sensitive than CECT. Contrast enhanced computerised tomography may be used if MRI is not available or contraindicated.

3. Serum tumour markers

Serum tumour markers (AFP, ß-hCG and LDH,) should be determined before, and after orchidectomy as they support the diagnosis of TC, may be indicative of GCT histology and provide risk stratification. Normal serum marker levels do not exclude the presence of TC, whilst persistence or increase of elevated serum tumour markers following orchidectomy indicates the likely presence of metastatic disease. Significant elevation of AFP in patients with seminomas should raise concerns of a non-seminoma component. In addition to staging, tumour markers are used to define risk stratification and prognosis as well as to monitor treatment response and detect disease relapse. Micro RNAs (miRNAs) are emerging as potential new biomarkers. However, issues around their use in routine clinical practice (including laboratory standardisation, availability of the test and prognostic validation) need to be resolved.

4. Inguinal exploration and initial management

- Orchidectomy including division of the spermatic cord at the internal inguinal ring represents the standard of care in patients with TC.
- Testis-sparing surgery (TSS) may be offered for small or indeterminate testicular masses, negative tumour markers and a normal contralateral testis to avoid over-treatment of potentially benign lesions and preserve testicular function. Patients should be informed that cancer can be present even in small (i.e., < 1 cm) masses*.
- Testis-sparing surgery should always only be offered accompanied with frozen section examination.
- Testicular prosthesis should be offered to all patients receiving unilateral or bilateral orchidectomy.

- Routine contralateral biopsy for diagnosis of GCNIS should be discussed with the patient and is recommended in 'high-risk' patients (testicular volume < 12 mL, a history of cryptorchidism and age < 40 years).

* *Limited data exists on oncological safety of TSS. Local recurrence rates (up to 26.9% when TC in specimen) necessitate close surveillance of the testis, possible use of adjuvant radiotherapy when GCNIS is present, as well as potential infertility and need for hormonal supplementation.*

5. Pathological examination of the testis

Following orchidectomy, the pathological examination of the testis should include a number of investigations:

1. *Macroscopic features:* It must indicate radical or partial orchidectomy, side, testis size, number of tumours, and macroscopic features of the epididymis, cord length, and tunica vaginalis.
2. *sampling:* At least a 1 cm^2 section for every centimetre of maximum tumour diameter including normal macroscopic parenchyma (if present), tunica albuginea and epididymis, with selection of suspicious areas. If the tumour is < 20 mm it should be completely sampled.
3. At least one proximal (base of the cord) and one distal section of spermatic cord plus any suspicious area. Cord blocks should preferably be taken prior to tumour sections to avoid contamination
4. *microscopic features and diagnosis* histological types (specify individual components and estimate amount as percentage) according to WHO 2022:
   - Presence or absence of peri-tumoural lymph and/or blood vessel invasion. In case of doubt, the use of endothelial markers, such as CD31, are recommended.
   - Presence or absence of GCNIS in non-tumour parenchyma.

- In case of rete testis invasion attention should be paid to distinguishing between pagetoid involvement and stromal invasion.

5. *pT* category according to TNM 2016;
6. *immunohistochemical* studies: in seminoma and mixed GCT, AFP and β-hCG.

6. Screening

There are no high-level evidence studies supporting screening programs. Young males should be informed about the importance of physical self-examination, particularly those with risk factors including a history of cryptorchidism or a male relative with TC.

7. Impact on fertility and fertility-associated issues

Sperm abnormalities and Leydig cell dysfunction are frequently found in patients with TCs prior to orchidectomy. Furthermore, treatment for TC, including orchidectomy, may have a negative impact on reproductive function. As such, all patients should be offered semen preservation.

Recommendations for diagnosis and staging of testicular cancer	**Strength rating**
Discuss sperm banking with all men prior to starting treatment for testicular cancer (TC).	Strong
Perform bilateral testicular ultrasound in all patients with suspicion of TC.	Strong
Perform physical examination including supraclavicular, cervical, axillary, and inguinal lymph nodes, breasts, and testicles.	Strong

Measure serum tumour markers both before and after orchidectomy taking into account half-life kinetics.	Strong
Perform orchidectomy and pathological examination of the testis to confirm the diagnosis and to define the local extension (pT category). In a life-threatening situation due to extensive metastasis, commence chemotherapy prior to orchidectomy.	Strong
Perform contrast enhanced computerised tomography (CECT) scan (chest, abdomen, and pelvis) in patients with diagnosis of TC. In case of iodine allergy or other limiting factors occur, perform abdominal and pelvic magnetic resonance imaging (MRI).	Strong
Perform MRI of the brain (or brain CECT if not available) in patients with multiple lung metastases, or high beta subunit of human Chorionic Gonadotropin (ß-hCG) values, or those in the poor-prognosis International Germ Cell Cancer Collaborative Group (IGCCCG) risk group.	Strong
Do not use positron-emission tomography computed tomography or bone scan for staging.	Strong
Encourage patients with TC to perform self-examination and to inform first degree male relatives of the need for self-examination.	Weak
Discuss testis-sparing surgery with frozen section examination in patients with a high likelihood of having a benign testicular tumour which are suitable for enucleation.	Strong

Discuss biopsy of the contralateral testis to patients with TC and high-risk for contralateral germ cell neoplasia *"in situ"*.	Strong

Prognosis

Table 3: Pathological risk factors for occult metastatic disease in Stage I TC

Histological type	Seminoma	Non-seminoma
Pathological risk factors	• Tumour size • Invasion of the rete testis	• Lympho-vascular invasion in peri-tumoural tissue

Disease management

1. Stage I Germ Cell Tumours

Germ cell neoplasia *"in situ"*, when diagnosed, can be treated by local radiotherapy (18-20 Gy in fractions of 2 Gy) or orchidectomy when the contralateral testis is normal.

Recommendations for the treatment of stage I seminoma	Strength rating
Fully inform the patient about all available management options, including surveillance or adjuvant chemotherapy after orchidectomy, as well as treatment-specific recurrence rates and acute and long-term side effects.	Strong
Offer surveillance as the preferred management option if facilities are available and the patient is compliant.	Strong

Offer one dose of carboplatin at area under curve (AUC) 7 if adjuvant chemotherapy is considered.	Strong
Do not perform adjuvant treatment in patients at very low risk of recurrence (no risk factors).	Strong
Do not routinely perform adjuvant radiotherapy.	Strong
Adjuvant radiotherapy should be reserved only for highly selected patients not suitable for surveillance and with contraindication for chemotherapy.	Strong

Recommendations for the treatment of stage I non-seminomatous germ cell tumour of the testis	**Strength rating**
Inform patients about all management options after orchidectomy: surveillance, adjuvant chemotherapy, and retroperitoneal lymph node dissection, including treatment-specific recurrence rates as well as acute and long-term side effects.	Strong
Offer surveillance or risk-adapted treatment based on lymphovascular invasion.	Strong
Discuss one course of cisplatin, etoposide, bleomycin as an adjuvant treatment alternative in patients with stage I non-seminomatous germ cell tumour if patients are not willing to undergo or comply with surveillance.	Strong

Recommendations for risk-adapted treatment for clinical stage I non-seminomatous germ cell tumour based on vascular invasion	**Strength rating**
Stage IA (pT1, no vascular invasion): low risk	
Offer surveillance if the patient is willing and able to comply.	Strong
Offer adjuvant chemotherapy with one course of cisplatin, etoposide, bleomycin (BEP) in low-risk patients not willing (or unsuitable) to undergo surveillance.	Strong
Stage IB (pT2-pT4): high risk	
Offer adjuvant chemotherapy with one course of BEP, or surveillance and discuss the advantages and disadvantages.	Strong
Offer surveillance to patients not willing to undergo adjuvant chemotherapy.	Strong
Offer nerve-sparing retroperitoneal lymph node dissection (RPLND) to highly selected patients only; those with contraindication to adjuvant chemotherapy and unwilling to accept surveillance.	Strong

Figure 1: Risk-adapted treatment in patients with clinical stage I non-seminoma NSGCT*

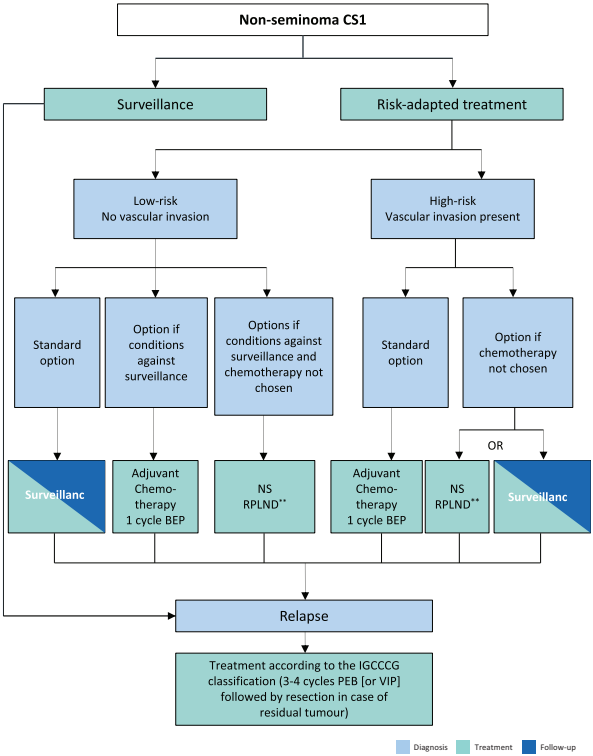

* *Discuss all treatment options with individual patients, to allow them to make an informed decision as to their further care.*

** *In case of PS II, the rate of recurrence is higher and chemotherapy can be discussed (max. 2 cycles).*

BEP = cisplatin, etoposide, bleomycin; CS = clinical stage; IGCCCG = International Germ Cell Cancer Collaborative Group; NS = nerve-sparing; RLNPD = retroperitoneal lymph node dissection; VIP = etoposide, cisplatin, ifosfamide.

2. Metastatic Germ cell Tumours

- Clinical Stage I (CS I) patients with persistently elevated serum tumours markers require repeated imaging including US examination of contralateral testis as well as MRI/CT of abdominal and extra-abdominal sites at 4 weeks. True CS I cases should be treated as other metastatic NSGCT with chemotherapy. Patients with stable marginal marker elevations may be initially monitored and treated when markers rise or subsequent imaging demonstrates metastatic disease.

- Patients with metastatic disease should be treated with upfront chemotherapy (cisplatin, etoposide, bleomycin (BEP) 3 or 4 cycles) according to the IGCCCG prognostic groups ± surgery of residual masses.

- An exception to this rule is Stage II low-volume seminoma that may be treated with radiotherapy (30 Gy) in case of contraindication for chemotherapy.

- In CS IIA NSGCT without elevated tumour markers nerve-sparing retroperitoneal lymph node dissection, when performed by an experienced surgeon in a specialised centre, is the recommended initial treatment. Initial surveillance may be considered in NSGCT patients with normal markers and equivocal lymph nodes < 2 cm) but requires early re-evaluation at six weeks. If the lesion progresses or fails to resolve it should be regarded and treated as CS II.

Figure 2: Treatment options in patients with seminoma clinical stage IIA and IIB*

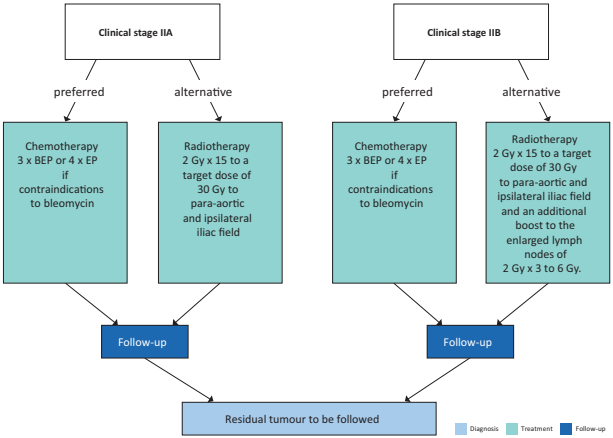

** When enlarged retroperitoneal lymph nodes are < 2 cm and with normal markers, treatment should not be initiated unless metastatic disease is unequivocal based on biopsy, increasing nodal size/number, or subsequent marker rise.*
BEP = cisplatin, etoposide, bleomycin; EP = etopside and cisplatin.

Figure 3: Flowchart Nonseminoma CS IIA Mk- at Diagnosis/Staging

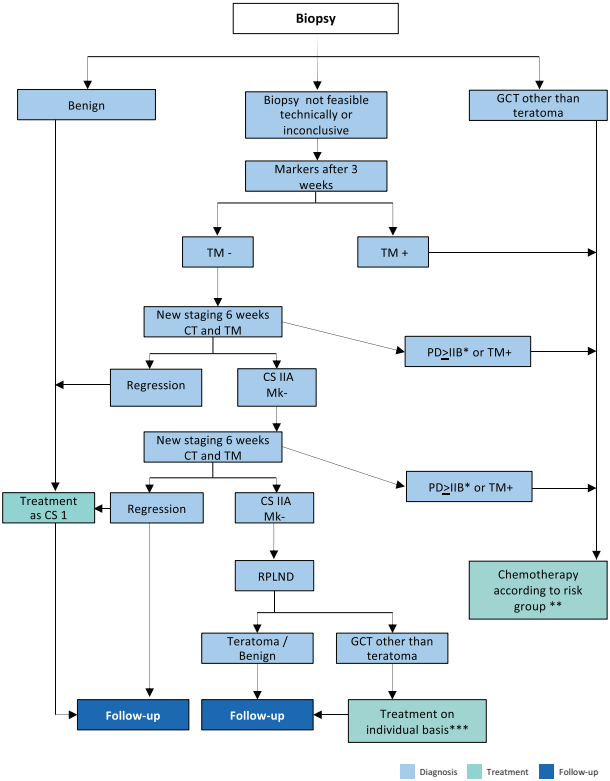

Recommendations for the Prevention of thromboembolism events during chemotherapy	Strength rating
Balance the individual patients' potential benefits and risks of thrombo-prophylaxis during first-line chemotherapy in men with metastatic germ cell tumours.	Weak
Avoid use of central venous-access devices during first-line chemotherapy whenever possible.	Weak

Recommendations for the treatment of metastatic germ cell tumours	Strength rating
Treat low-volume non-seminomatous germ cell tumour (NSGCT) stage IIA/B with elevated markers like metastatic good- or intermediate-prognosis risk group IGCCCG with three or four cycles of cisplatin, etoposide, bleomycin (BEP).	Strong
Nerve-sparing retroperitoneal lymph node dissection when performed by an experienced surgeon in a specialised centre is the recommended initial treatment in clinical stage (CS) IIA NSGCT disease without elevated tumour markers.	Weak
Repeat staging after six weeks before making a final decision on further management should be considered in patients with small volume (CS IIA < 2 cm) marker-negative NSGCT.	Weak
Treat metastatic NSGCT (stage > IIC) with an intermediate prognosis with four cycles of standard BEP.	Strong

Treat metastatic NSGCT with a poor prognosis and favourable marker decline with four cycles of BEP.	Strong
Assess tumour marker decline after one cycle of standard chemotherapy in metastatic NSGCT with a poor-prognosis. With unfavourable decline, consider chemotherapy intensification.	Weak
Perform surgical resection of visible (> 1 cm in longest diameter) residual masses after chemotherapy for NSGCT when serum levels of tumour markers are normal or normalising.	Strong
Offer cisplatin chemotherapy according to IGCCCG prognosis groups, or alter-natively radiotherapy to seminoma patients with stage II A/B and, inform the patient of potential long-term side effects of both treatment options.	Weak
Treat seminoma stage IIC and higher, with primary chemotherapy according to IGCCCG classification (BEP x 3 in good-prognosis and BEP x 4 in intermedi-ate prognosis).	Strong

Relapse after chemotherapy

The treatment of relapsed GCT after chemotherapy is typically salvage chemotherapy. For patients at first relapse with good prognostic features - initial achievement of complete response/partial remission negative markers and gonadal primary tumour. The regimens of choice are four cycles of a three-agent regimen including cisplatin and ifosfamide plus a third drug: VIP, paclitaxel (TIP), or potentially gemcitabine (GIP). Due to their potential risk of lethal haematological

toxicity, these regimens should be used with granulocyte colony-stimulating factor (G-CSF) support. For patients with poor prognostic factors (extra-gonadal primary and/or incomplete response to first-line chemotherapy) and for all patients with subsequent (second or more) relapse, high-dose chemotherapy with autologous stem cell support is recommended.

Follow-up

The primary aim of follow-up in the first five years is the timely diagnosis of recurrent disease in order to be able to treat the patient with curative intent with the least aggressive therapy. The following factors should be considered:

a) Follow-up must be tailored to the individual patient with a schedule acceptable to the patient, the clinician, and the health care system.
b) The interval of follow-up visits and the clinical investigations to be performed at each visit should depend on the risk of relapse, in general, as well as the likely sites of relapse in an individual patient.
c) When possible, an effort should be made to minimise any risks associated with ionising radiation exposure.
d) The increased risk of second malignancy (in the primary site and in other tissues that may have been exposed to the same carcinogens, or in which there is epidemiological evidence of increased risk) should also guide the selection of tests.

Table 4: Recommended minimal follow-up for seminoma stage I on active surveillance or after adjuvant treatment (carboplatin or radiotherapy)[1]

Modality	Year 1	Year 2	Year 3	Years 4 & 5	After 5 years
Tumour markers ± doctor visit	2 times	2 times	2 times	Once	Further management according to survivorship care plan
Chest X-ray	-	-	-	-	
Abdominopelvic Computed tomography (CT)/ magnetic resonance imaging	2 times	2 times	Once at 36 months	Once at 60 months	

[1] *Recommendations based upon ESMO (European Society for Medical Oncology) Testicular seminoma and non-seminoma consensus meeting outcomes.*

Table 5: Recommended minimal follow-up for non-seminoma clinical stage I on active surveillance[1]

Modality	Year 1	Year 2	Year 3	Years 4 & 5	After 5 years
Tumour markers ± doctor visit	4 times*	4 times	2 times	1-2 times	Further management according to survivorship care plan
Chest X-ray	2 times	2 times	Once, in case of LVI+	At 60 months if LVI+	
Abdominopelvic Computed tomography (CT)/ magnetic resonance imaging	2 times	At 24 months**	Once at 36 months***	Once at 60 months***	

LVI+ = lymphovascular invasion.

[1] *Recommendations based upon ESMO Testicular seminoma and non-seminoma consensus meeting outcomes.*

** In case of high risk (LVI+) a minority of the consensus group members recommended six times.*
*** In case of high risk (LVI+) a majority of the consensus group members recommended an additional CT at eighteen months.*
**** Recommended by 50% of the consensus group members.*

Table 6: Recommended minimal follow-up after adjuvant treatment or complete remission for advanced disease (excluded: poor prognosis and no remission)[1]

Modality	Year 1	Year 2	Year 3	Years 4 & 5	After 5 years
Tumour markers ± doctor visit	4 times	4 times	2 times	2 times	Further management according to survivorship care plan**
Chest X-ray	1-2 times	Once	Once	Once	
Abdominopelvic Computed tomography (CT)/ magnetic resonance imaging	1-2 times	At 24 months	Once at 36 months	Once at 60 months	
Thorax CT	1-2 times*	At 24 months*	Once at 36 months*	Once at 60 months*	

[1] Recommendations based upon ESMO Testicular seminoma and non-seminoma consensus meeting outcomes.
** In conjunction with abdominopelvic CT/MRI in case of pulmonary metastases at diagnosis.*
*** In case of teratoma in resected residual disease: the patient should remain with the uro-oncologist.*

Quality of life and long-term toxicities after cure

Patients diagnosed with TC are usually between 18 and 40 years of age at diagnosis, and life expectancy after cure extends over several decades. Patients should be informed before treatment of common long-term toxicities, which are avoided or minimised by adherence to international guidelines.

During follow-up, patients should be screened and treated for known risk factors such as hypertension, hyperlipidaemia, and testosterone deficiency. When follow-up by the clinical expert is discontinued, a written cancer survivorship plan addressing late toxic effects, lifestyle recommendations, recurrence risk, and cancer-specific follow-up may be helpful.

**For more information regarding long term toxicities and quality of life issues, please see appendix 5, available online https://uroweb.org/guidelines/testicular-cancer/publications-appendices*

Rare adult testicular tumours

Rare testicular tumours have a similar presentation as GCTs and are only identified after histopathological examination. They are classified according to the WHO Classification of Tumours of the Urinary System and Male Genital Organs.

1. Spermatocytic Tumours

Spermatocytic tumours are GCTs unrelated to GCNIS and extremely rare. Normally they do not show elevated markers and cannot be differentiated from seminomatous GCT by frozen section analysis. Radical orchiectomy is the standard treatment option. Metastatic disease is very rare and typically presents at, or soon after, initial diagnosis with limited survival.

2. Sex cord-stromal tumours

Sex cord–stromal tumours are the second largest group of primary testicular tumours after GCTs. They are relatively uncommon and a small minority are malignant. Morphological features associated with malignant potential in both types include two or more of the following features:

- size > 5 cm
- infiltrative borders
- cytological atypia
- 3 or more mitotic figures per 10 high-power fields
- vascular invasion
- necrosis

Leydig cell tumours

Leydig cell tumours comprise about 4% of adult testicular tumours. They may present with hormonal manifestations, including gynecomastia and rarely accompanied by Cushing's Syndrome. Local recurrence of 7% has been reported after TSS. Survival of men with metastatic disease is poor but response to surgical and systemic treatment have been reported.

Sertoli cell tumours

Sertoli cell tumours account for approximately 1% of all testicular neoplasms. The risk of metastates is unclear. After TSS a local recurrence rate of < 1% has been reported. Survival of men with metastatic disease is poor although response to surgery has occasionally been reported.

Granulosa cell tumour

Granulosa cell tumours include adult and juvenile variants and are extremely rare and metastatic potential is unclear. After TSS a local recurrence rate of 5% has been reported. Metastatic disease has only been described, albeit extremely rare, in men with adult type. Survival of men with metastatic disease is poor although rare instances of response to surgical or systemic treatment have been reported.

Thecoma/fibroma group of tumours

These tumours derive from the testicular parenchymal stroma or from the tunica albuginea. They seem to be uniformly benign.

Paratesticular tumours of the epididymis or spermatic cord

The majority of epididymal masses are benign cystic or inflammatory conditions. Solid epididymal tumours are rare and comprise numerous benign and neoplastic lesions. No clear recommendation can be provided regarding surgical approach, extent of resection and neo- or adjuvant treatment can be given.

3. Mesothelioma of the tunica vaginalis testis

Mesothelioma of the tunica vaginalis testis is a rare but aggressive disease. Aggressive local treatment with hemiscrotectomy is recommended. No clear recommendation can be given regarding adjuvant treatment. In case of metastatic disease, the median overall survival is a few months.

4. Rare adult para- and testicular cancers

After local surgical treatment is completed, attention turns to follow-up strategies with the aims of detecting recurrence or secondary cancers at a stage when further curative procedures are possible whilst minimising the burden of follow-up and the potential for over-treatment and concomitant treatment toxicity. Data for rare para- and testicular cancers are limited.

This short booklet text is based on the more comprehensive EAU Guidelines (ISBN 978-94-92671-29-5), available to all members of the European Association of Urology at their website, http://www.uroweb.org/guidelines/.