

EAU GUIDELINES ON PAEDIATRIC UROLOGY

(Limited text update April 2025)

C. Radmayr (Chair), G. Bogaert (Vice-chair), B. Burgu, M.S. Castagnetti, F. O'Kelly, J. Quaedackers, Y.F.H. Rawashdeh, M.S. Silay, L.A 't Hoen

Guidelines Associates: U.K. Kennedy, M. Gnech, M. Skott, A. van Uitert

Guidelines Office: J.A. Darraugh

Introduction

Due to the scope of the extended Guidelines on Paediatric Urology, only a short introduction of the individual chapter in combination with recommendations can be given in this pocket version. Additionally, some algorithms and flow charts are enclosed. For further details please refer to the full length version.

PHIMOSIS

Phimosis is either primary (physiological), with no sign of scarring, or secondary (pathological), resulting from scarring due to conditions such as balanitis xerotica obliterans.

Childhood circumcision should not be recommended without a medical reason. An absolute indication for circumcision is secondary phimosis. Contraindications are congenital anomalies of the penis, particularly hypospadias or buried penis, as the foreskin may be required for a reconstructive procedure.

Paraphimosis is characterised by retracted foreskin with the constrictive ring localised at the level of the sulcus.

| Recommendations | Strength rating |
|---|------------------------|
| Offer topical corticosteroids (ointment or cream) as first-line treatment in symptomatic phimosis. | Strong |
| Consider surgical intervention if patient/caregivers prefer for symptomatic phimosis. | Strong |
| Offer circumcision in case of balanitis xerotica obliterans (BXO) or phimosis refractory to treatment. | Strong |
| Offer treatment for asymptomatic phimosis in infants with a risk of recurrent urinary tract infection due to upper urinary tract abnormalities (vesico-ureteral reflux or posterior urethral valves). | Strong |
| Inform patients about the risk of meatal stenosis in BXO. | Strong |
| Await spontaneous resolution of asymptomatic preputial adhesions before puberty. | Weak |
| Treat paraphimosis by manual reposition and proceed to surgery if this fails. | Strong |
| Do not perform simple circumcision if phimosis is associated with other penile anomalies such as buried penis, congenital penile curvature, epispadias or hypospadias. | Strong |

UNDESCENDED TESTIS

Cryptorchidism or undescended testis is one of the most common congenital malformations of male neonates with an incidence of 1.0-4.6% of full-term neonates. Boys with one undescended testis have a lower fertility rate whereas boys with bilateral undescended testes suffer both, lower fertility and paternity rates. In addition, boys who are treated for an undescended testis have an increased risk of developing testicular malignancy. Therefore, screening and self-examination both during and after puberty is recommended.

Figure 1: Classification of undescended testes

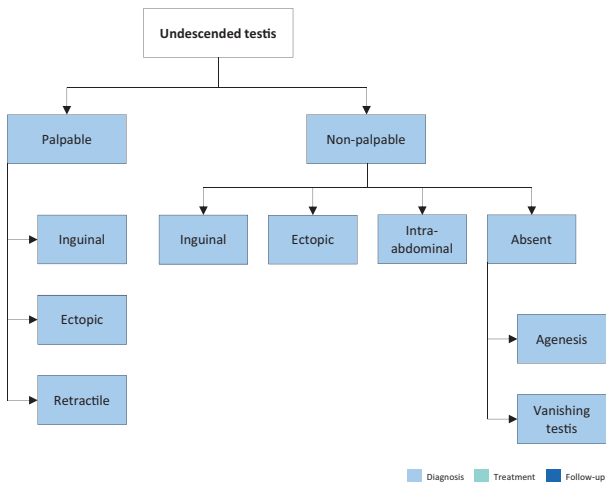
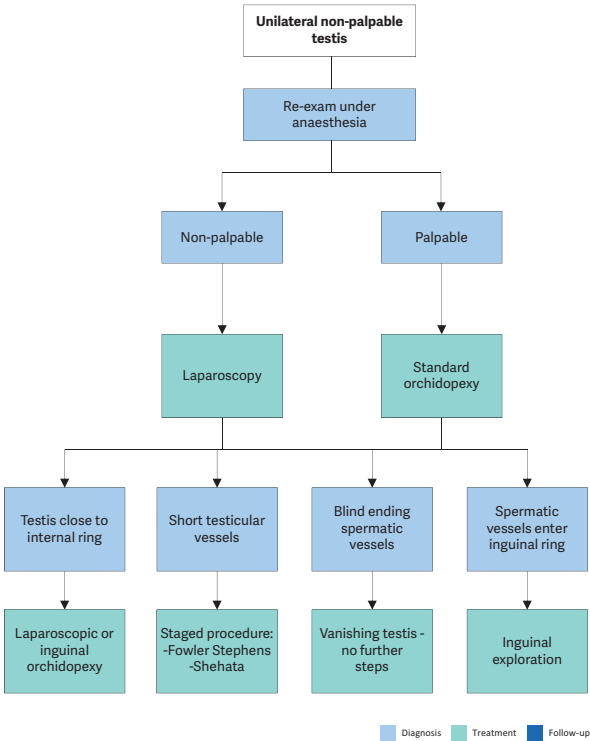


Figure 2: Treatment of unilateral non-palpable undescended testes



| Recommendations | Strength rating |
|---|-----------------|
| Do not offer medical or surgical treatment for retractile testes but undertake close follow-up on a regular basis until puberty. | Strong |
| Do not offer hormonal therapy in unilateral undescended testes for testicular descent only. | Strong |
| Offer endocrine treatment in cases of bilateral undescended testes to preserve future fertility potential. | Weak |
| Perform surgical orchidofunicolysis and orchidopexy before the age of twelve months, and by eighteen months at the latest. | Strong |
| Perform an endocrinological workup in the setting of bilateral non-palpable testes. | Strong |
| Perform an exam under anaesthesia and subsequent diagnostic laparoscopy to locate an intra-abdominal testicle. | Strong |
| Inform the patient/caregivers about the increased risk of malignancy with an undescended testis increasing with the age at orchidopexy. | Weak |

TESTICULAR TUMOURS IN PREPUBERTAL BOYS

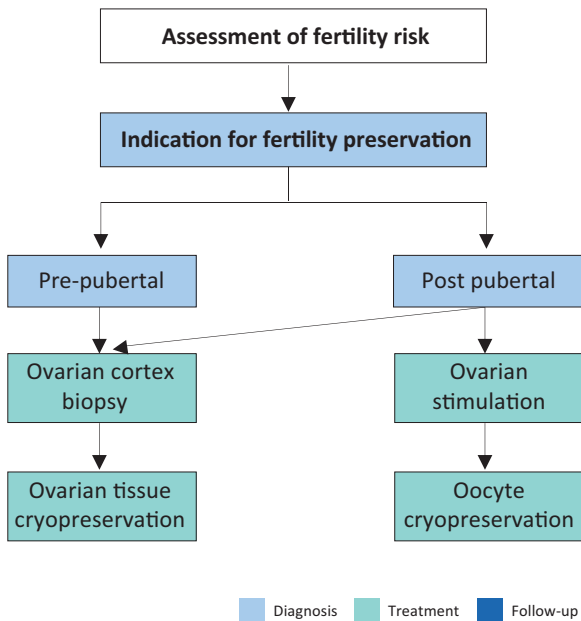
Testicular tumours account for approximately 1-2% of all paediatric solid tumours. In prepubertal boys most intratesticular tumours are benign and teratomas and yolk sac tumours more common than germ cell tumours, whereas post-puberty the tumours are most likely malignant.

| Recommendations | Strength rating |
|--|------------------------|
| High-resolution ultrasound (7.5 – 12.5 MHz), preferably a doppler ultrasound, should be performed to confirm the diagnosis. | Strong |
| Alpha-fetoprotein should be determined in prepubertal boys with a testicular tumour before surgery. | Strong |
| Surgical exploration should be done with the option for frozen section. | Strong |
| Testicular sparing surgery should be performed in all benign tumours. | Strong |
| Staging (MRI abdomen/CT chest) should only be performed in patients with a malignant tumour to exclude metastases. | Strong |
| Patients with a non-organ confined tumour should be treated in a multidisciplinary fashion including paediatric oncologists. | Strong |

FERTILITY PRESERVATION IN CHILDREN AND ADOLESCENTS

The continuous increase in the incidence of paediatric cancers and post-treatment survivorship over the years coupled with the further development of potentially gonadotoxic therapies, has contributed to the recognition and rapid endorsement of fertility preservation counselling for prepubertal children and adolescents. Patients and caregivers should be informed not only about the impact of gonadotoxic treatments on future fertility but also about fertility-preservation options and their risk-benefit ratio. There are also a number of non-oncological congenital anomalies where fertility preservation can become an issue.

Figure 3: Ovarian tissue cryopreservation for girls and adolescents



Adapted from Anderson et al. 2015.

| Recommendations | Strength rating |
|--|------------------------|
| Inform patients and caregivers about the impact of gonadotoxic treatments on future fertility and about fertility preservation options and their risk-benefit balance. | Strong |
| Discuss the indications and options for fertility preservation in a paediatric multidisciplinary fertility preservation team and consider the toxicity of the planned therapy, the age and pubertal status as well ethical and financial issues. | Strong |

HYDROCELE

A communicating hydrocele vacillates in size, usually relative to activity. It is diagnosed by medical history and physical investigation, the swelling is translucent, and transillumination of the scrotum confirms the diagnosis. Non-communicating hydroceles are found secondary to minor trauma, testicular torsion, epididymitis, or varicocele operation, or may appear as a recurrence after primary repair of a communicating hydrocele.

| Recommendations | Strength rating |
|--|------------------------|
| Observe hydrocele for twelve months prior to considering surgical treatment. | Strong |
| Perform early surgery if there is suspicion of a concomitant inguinal hernia or underlying testicular pathology. | Strong |
| Perform ultrasound in case of doubt about the character of an intrascrotal mass, or suspicion of an abdominoscrotal hydrocele. | Strong |

| | |
|---|--------|
| Close the processus vaginalis at the inguinal ring. | Strong |
| Do not use sclerosing agents in children with hydroceles, because of the risk for chemical peritonitis. | Strong |

ACUTE SCROTUM

Acute scrotum is a paediatric urological emergency, most commonly caused by torsion of the testis or appendix testis, or epididymitis/epididymo-orchitis.

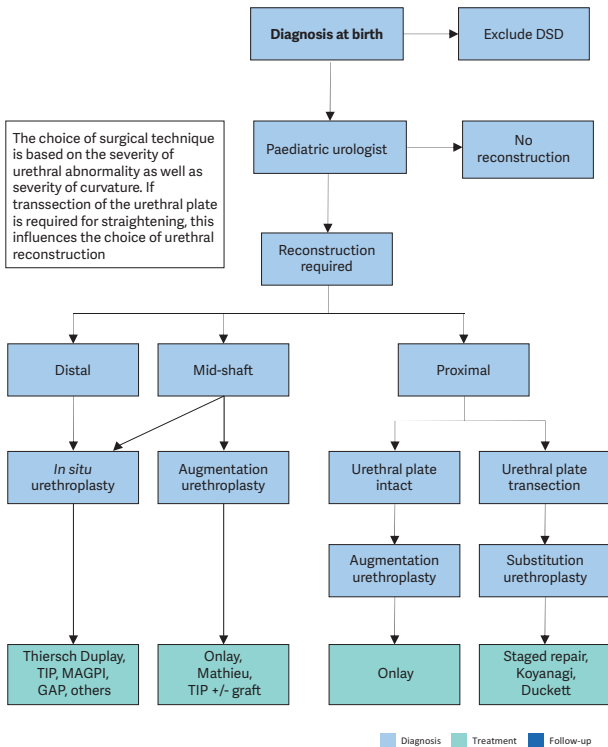
| Recommendations | Strength rating |
|--|-----------------|
| Testicular torsion is a paediatric urological emergency and requires immediate treatment. | Strong |
| In neonates with testicular torsion perform orchidopexy of the contralateral testicle. In prenatal torsion the timing of surgery is usually dictated by clinical findings. | Weak |
| Base the clinical diagnosis on physical examination. The use of Doppler ultrasound to evaluate acute scrotum is useful, but this should not delay the intervention. | Strong |
| Manage torsion of the appendix testis conservatively. Perform surgical exploration in equivocal cases and in patients with persistent pain. | Strong |
| Perform urgent surgical exploration in all cases of testicular torsion as soon as possible. | Strong |

HYPOSPADIAS

Hypospadias are usually classified according to the anatomical location of the proximally displaced urethral orifice.

Patients with hypospadias should be diagnosed at birth. The diagnostic evaluation also includes an assessment of associated anomalies, which include cryptorchidism and open processus vaginalis or inguinal hernia. Severe hypospadias with unilaterally or bilaterally impalpable testis, or with ambiguous genitalia, require a complete genetic and endocrine work-up immediately after birth to exclude disorders of sex development, especially congenital adrenal hyperplasia.

Figure 4: Algorithm for the management of hypospadias



DSD = disorders of sex development; TIP = tubularised incised plate urethroplasty; MAGPI = meatal advancement and glanuloplasty incorporated.

| Recommendations | Strength rating |
|---|------------------------|
| Differentiate isolated hypospadias from disorders of sex development at birth. | Strong |
| Counsel caregivers on functional and aesthetic value of hypospadias corrective surgery and possible complications. | Strong |
| Use the treatment algorithm (Figure 4) to select the most appropriate surgical technique. | Strong |
| Correct significant (> 30 degrees) curvature of the penis. | Weak |
| Ensure long-term follow-up to detect urethral stricture, voiding dysfunction, recurrent penile curvature, ejaculation disorder, and to evaluate patient's satisfaction. | Strong |

CONGENITAL PENILE CURVATURE

Congenital penile curvature presents penile bending of a normally formed penis due to corporal disproportion. Most of the cases are ventral deviations. Curvature > 30° is considered clinically significant; curvature > 60° may interfere with satisfactory sexual intercourse in adulthood. The treatment is surgical.

| Recommendations | Strength rating |
|---|------------------------|
| Ensure that a thorough medical history is taken, and a full clinical examination done to rule out associated anomalies in boys presenting with congenital penile curvature. | Strong |
| Request photo documentation of the erect penis from different angles as a pre-requisite in the pre-operative evaluation. | Strong |
| Perform surgery if the penile curvature has functional implications. | Strong |
| Perform artificial erection at the beginning as well as at the end of surgery. | Strong |

VARICOCELE IN CHILDREN AND ADOLESCENTS

Varicocele is unusual in boys under ten years of age, but becomes more frequent at the beginning of puberty. Fertility problems will arise in about 20% of adolescents with varicocele. Testicular catch-up growth and improvement in sperm parameters after varicocelectomy have been reported in adolescents. Varicocele is mostly asymptomatic, rarely causing pain at this age. Diagnosis and classification depend upon the clinical finding and US investigation.

Figure 5: Algorithm for the diagnosis of varicocele in children and adolescents

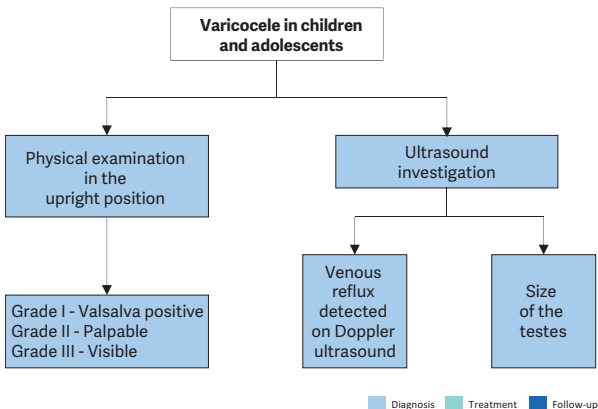
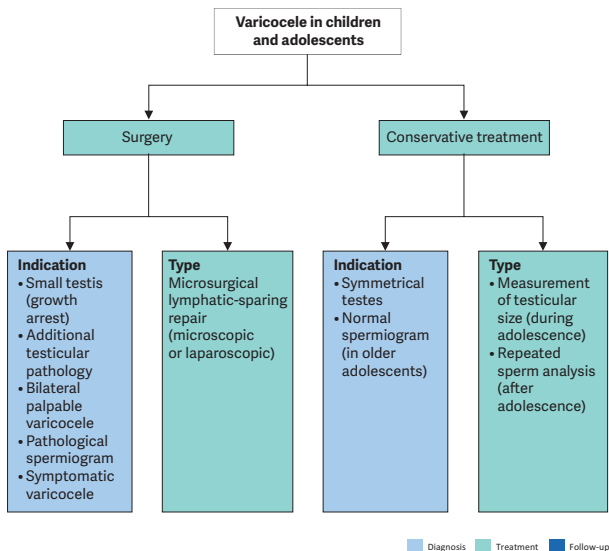


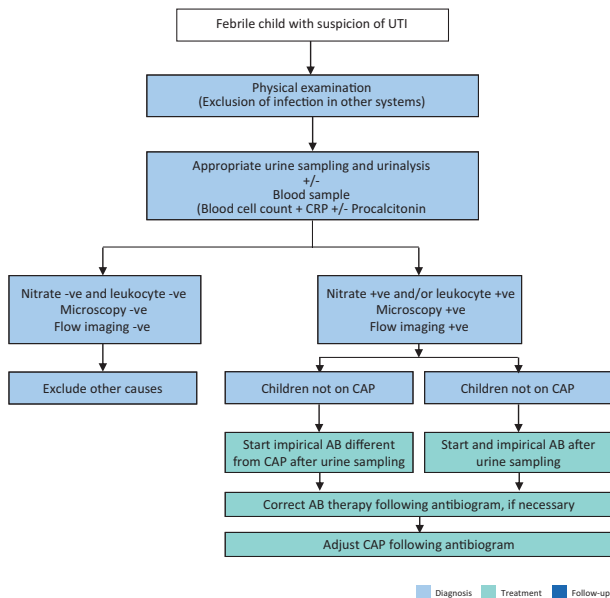
Figure 6: Algorithm for the management of varicocele in children and adolescents



| Recommendations | Strength rating |
|--|------------------------|
| Examine varicocele in the standing position and classify into three grades. | Strong |
| Use scrotal ultrasound to evaluate testicular volume and to detect venous reflux in the supine and upright position and during Valsalva manoeuvre. | Strong |
| In all pre-pubertal boys with a varicocele and in all isolated right varicoceles perform standard abdominal ultrasound to rule out a retroperitoneal mass. | Strong |
| Inform caregivers and patients and offer surgery for varicocele associated with a persistent small testis (size difference of > 2 mL or 20%). | Strong |
| Varicocele treatment can be also considered under the following circumstances: <ul style="list-style-type: none"> • symptomatic varicocele; • additional testicular condition affecting fertility such as a contralateral testicular condition; • bilateral palpable varicocele; • pathological sperm quality (in older adolescents); • cosmetic reasons related to scrotal swelling. | Weak |
| Use some form of optical magnification (microscopic or laparoscopic magnification) for surgical ligation. | Strong |
| Use lymphatic-sparing varicocelectomy to prevent hydrocele formation. | Strong |

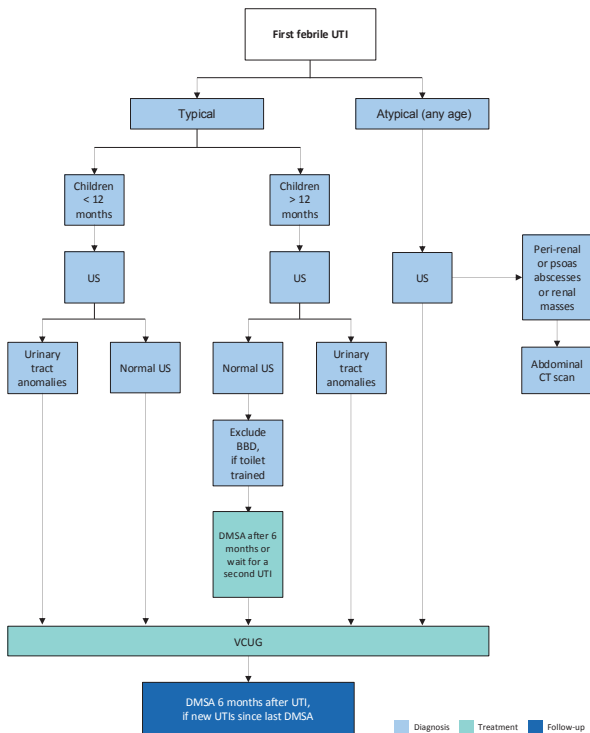
URINARY TRACT INFECTIONS IN CHILDREN

Figure 7: Diagnostic evaluation and subsequent management of a febrile child with suspicion of UTI



*AB = antibiotic; CAP = continuous antibiotic prophylaxis;
CRP = C-reactive protein.*

Figure 8: Diagnosis strategy for first febrile UTI



US = ultrasound; CT = Computed tomography; BBD = bladder and bowel dysfunction; UTI = urinary tract infections; DMSA = dimercaptosuccinic acid; VCUg voiding cystourethrogram.

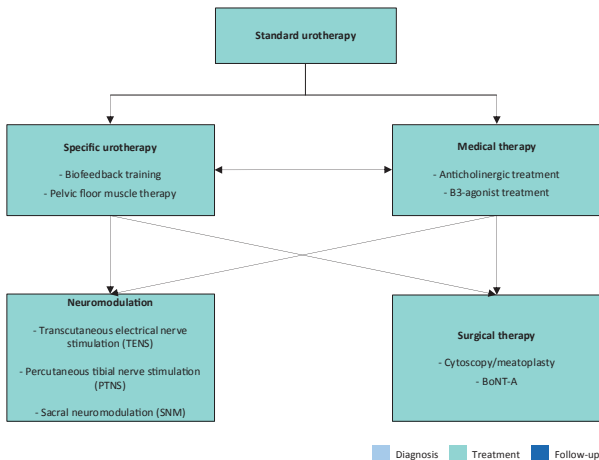
| Recommendations | Strength rating |
|--|-----------------|
| Take a detailed medical history, assess clinical signs and symptoms and perform a physical examination in the evaluation of children suspected of having a urinary tract infection (UTI). | Strong |
| Use bladder catheterisation or suprapubic bladder aspiration to collect urine for urinalysis and cultures in non-toilet-trained children. | Strong |
| Use clean catch urine for screening for UTI in non-toilet-trained children. | Weak |
| Do not use plastic bags for urine sampling in non-toilet-trained children. | Strong |
| Use midstream urine in toilet-trained children for analysis and culture. | Strong |
| Perform renal and bladder US within 24 hours in infants with febrile UTI and acutely ill children to check for abnormalities of the urinary tract. | Strong |
| Consider a voiding cystourethrogram (VCUG) in the follow-up of patients developing febrile UTI < one year of age, with atypical infections, with recurrent infections, or with ultrasound abnormalities. | Weak |
| Consider a dimercaptosuccinic acid (DMSA) scan at least six month after a febrile UTI to assess kidney function and the presence of renal scars. | Weak |
| Treat febrile UTIs with four to seven day courses of oral or parenteral therapy. | Strong |

| | |
|---|--------|
| Chose parenteral therapy in severely ill patients or if oral treatment is not tolerated. | Strong |
| Treat complicated febrile UTI with broad-spectrum antibiotics. | Strong |
| Consider urinary drainage in patients with UTIs unresponsive to antibiotic treatment. | Weak |
| Offer antibacterial prophylaxis in patients at risk of recurrent UTIs. | Strong |
| Consider dietary supplementation as an alternative or add-on preventive measure in selected cases. | Weak |
| Offer treatment for phimosis to patients with underlying urological conditions. | Weak |
| Assess bladder and bowel dysfunction and lower urinary tract function in any toilet-trained child with febrile and/or recurrent UTI and treat it. | Strong |

DAY-TIME LOWER URINARY TRACT DYSFUNCTION

Urinary incontinence in children may be caused by congenital or neurologic abnormalities; however, many children have functional bladder problems for which the term day-time lower urinary tract (LUT) conditions is used. Day-time LUTD has a high prevalence ranging between 1-20%. Symptoms can be classified as filling-phase (storage) dysfunctions and voiding-phase (emptying) dysfunctions.

Figure 9: The treatment of daytime LUT conditions



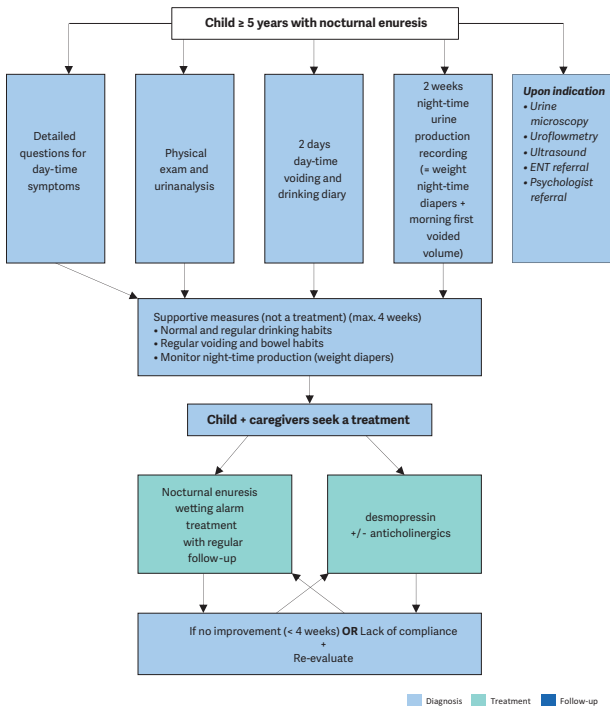
| Recommendations | Strength rating |
|---|------------------------|
| Use two-day voiding diaries and/or structured questionnaires for objective evaluation of symptoms, voiding drinking habits and response to treatment. | Strong |
| Use a stepwise approach, starting with the least invasive treatment in managing daytime lower urinary tract (LUT) conditions in children. | Strong |
| Provide adequate bowel management as part of the treatment, if bladder bowel dysfunction is present. | Strong |
| Re-evaluate in case of treatment failure; this may consist of (video) urodynamics, magnetic resonance imaging of lumbosacral spine and cystoscopy. | Weak |
| Arrange adequate transition into adult urological care for children with persistent daytime LUT conditions in adolescence. | Strong |

MONOSYMPOMATIC NOCTURNAL ENURESIS - BEDWETTING

Monosymptomatic nocturnal enuresis is incontinence during the night without daytime symptoms above the age of five years. Due to an imbalance between night-time urine output and night-time bladder capacity, the bladder can easily become full at night, and the child will either wake-up to empty the bladder or will void during sleep.

A voiding diary, registering the day-time bladder function and the night-time urine output will help guide the treatment.

Figure 10: A stepwise assessment and management options for nocturnal enuresis



ENT = ear, nose, throat.

| Recommendations | Strength rating |
|---|------------------------|
| Do not treat children less than five years of age in whom spontaneous cure is likely, but inform the family about the involuntary nature, the high incidence of spontaneous resolution and the fact that punishment will not help to improve the condition. | Strong |
| Use micturition diaries or questionnaires to exclude day-time symptoms. | Strong |
| Perform a urine test to exclude the presence of infection or potential causes such as diabetes insipidus. | Strong |
| Offer supportive measures in conjunction with other treatment modalities, of which pharmacological and alarm treatment are the two most important. | Strong |
| Offer desmopressin in proven night-time polyuria. | Strong |
| Offer alarm treatment in motivated and compliant families. | Strong |

MANAGEMENT OF NEUROGENIC BLADDER

In partnership with the European Reference Networks ERN eUROGEN, ERN ITHACA, ERN ERKNet, and the IFSBH, the Panel has developed a new joint guideline for the diagnosis and treatment of spinal dysraphism in children and adolescents. This standalone guideline has replaced the previous chapter in this guideline on neurogenic bladder in children. Detailed information can be found: <http://www.uroweb.org/guidelines>.

| Recommendations | Strength rating |
|--|-----------------|
| <p>Urodynamic studies should be performed in every patient with spinal dysraphism as well as in every child with a high suspicion of a neurogenic bladder to estimate the risk for the upper urinary tract and to evaluate the function of the detrusor and the sphincter.</p> | Strong |
| <p>In all newborns, intermittent catheterisation (IC) should be started soon after birth. In those with a clear underactive sphincter and no overactivity, starting IC may be delayed. If IC is delayed, closely monitor babies for urinary tract infections, upper tract changes (US) and the lower tract (UDS).</p> | Strong |
| <p>Start early anticholinergic medication in newborns with a suspicion of an overactive detrusor.</p> | Strong |
| <p>The use of suburothelial or intradetrusoral injection of onabotulinum toxin A is an alternative and less invasive option in children who are refractory to anticholinergics in contrast to bladder augmentation.</p> | Strong |
| <p>Treatment of bowel emptying problems is important to gain continence and independence. Treatment should be started with regular fluid intake and dietary measures as well as mild laxatives, rectal suppositories, and digital stimulation. If insufficient, transanal irrigation is recommended, and if this is not practicable or feasible, a Malone antegrade colonic enema (MACE)/Antegrade continence enema (ACE) stoma should be discussed.</p> | Strong |

| | |
|---|---------------|
| <p>Ileal or colonic bladder augmentation is recommended in patients with therapy resistant detrusor overactivity, small capacity and poor compliance, which may cause upper tract damage and incontinence. The risks of surgical and non-surgical complications and consequences outweigh the risk of permanent damage of the upper urinary tract +/- incontinence due to the detrusor.</p> | <p>Strong</p> |
| <p>In patients with a neurogenic bladder and a weak sphincter, a bladder outlet procedure should be offered. It should be done in most patients together with a bladder augmentation.</p> | <p>Weak</p> |
| <p>Creation of a continent cutaneous catheterisable channel should be offered to patients who have difficulties in performing IC through the urethra.</p> | <p>Weak</p> |
| <p>A life-long follow-up of renal function should be available and offered to every patient.</p> | <p>Strong</p> |
| <p>Addressing sexuality and fertility starting before/during puberty should be offered.</p> | <p>Weak</p> |
| <p>Urinary tract infections are common in children with neurogenic bladders, however, only symptomatic UTIs should be treated.</p> | <p>Weak</p> |
| <p>Performing and reporting of urodynamic studies should be done according to ICCS standards.</p> | <p>Strong</p> |

| | |
|---|---------------|
| <p>The QUALAS, which measures HRQoL related to bladder and bowel in patients with spinal dysraphism, should be used across childhood and adolescence in research, but also form part of routine follow-up care over time, enabling the provision of targeted interventions.</p> | <p>Weak</p> |
| <p>Special attention should be paid to monitoring HRQoL in the clinical care of children with neurogenic bladder and bowel because they are a known risk group for poor HRQoL.</p> | <p>Weak</p> |
| <p>In order to maintain or improve the health-related quality of life in children with spinal dysraphism, parent and family support should be provided as part of routine follow-up care in the families of the affected individuals.</p> | <p>Weak</p> |
| <p>At the moment the evidence is too weak to recommend prenatal intervention to improve urological outcome and should be reserved for specialised centres in properly designed studies.</p> | <p>Weak</p> |
| <p>Screen for psychological symptoms and disorders with validated, broadband behavioural questionnaires at school entry or whenever indicated clinically.</p> | <p>Strong</p> |
| <p>If the screening is positive and reveals signs and symptoms of psychological disorders, a full professional mental health assessment should follow.</p> | <p>Strong</p> |
| <p>If a psychological disorder of clinical relevance and with incapacitation is present, counselling should be offered in every case.</p> | <p>Strong</p> |

If a mental health disorder is present and counselling alone is insufficient, treatment according to evidence-based guidelines is recommended.

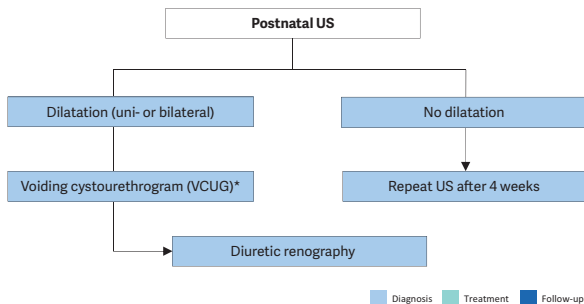
Strong

DILATATION OF THE UPPER URINARY TRACT (UPJ AND UVJ OBSTRUCTION)

Dilatation of the upper urinary tract remains a significant clinical challenge in deciding which patient will benefit from treatment. Ureteropelvic junction obstruction is the most common pathological cause of neonatal hydronephrosis.

Megaureters (obstruction at the level of the ureterovesical junction) are the second most likely cause of pathological neonatal hydronephrosis. The widespread use of US during pregnancy has resulted in a higher detection rate for antenatal hydronephrosis. The challenge in the management of dilated upper tracts is to decide which child should be observed, which managed medically, and which requires surgical intervention.

Figure 11: Diagnostic algorithm for dilatation of the upper urinary tract



* A diagnostic work-up including VCUG must be discussed with the caregivers, as it is possible that, even if reflux is detected, it may have absolutely no clinical impact. However, it should be borne in mind that reflux has been detected in up to 25% of prenatally detected cases.

US = ultrasound.

| Recommendations | Strength rating |
|---|-----------------|
| Include serial ultrasound (US) and subsequent diuretic renogram and sometimes voiding cystourethrography in post-natal investigations. | Strong |
| Offer continuous antibiotic prophylaxis to the subgroup of children with antenatal hydronephrosis who are at high risk of developing urinary tract infection like uncircumcised infants, children diagnosed with hydroureteronephrosis and high-grade hydronephrosis, respectively. | Weak |
| Decide on surgical intervention based on the time course of the hydronephrosis and the impairment of renal function. | Weak |
| Offer surgical intervention in case of an impaired split renal function due to obstruction or a decrease of split renal function in subsequent studies and increased anteroposterior diameter on the US, and grade IV dilatation as defined by the Society for Fetal Urology. | Weak |

| | |
|--|------|
| Offer pyeloplasty when ureteropelvic junction obstruction has been confirmed clinically or with serial imaging studies proving a substantially impaired or decrease in function. | Weak |
| Do not offer surgery as a standard for primary megaureters since the spontaneous remission rates are as high as 85%. | Weak |

VESICoureTERIC REFLUX IN CHILDREN

Vesicoureteric reflux (VUR) presents with a wide range of severities, and the majority of reflux patients will not develop renal scars and probably will not need any intervention. The main goal in management is the preservation of kidney function.

The diagnostic work-up should evaluate the overall health and development of the child including a detailed medical history (including family history, and screening for lower urinary tract and/or bowel dysfunction [LUTD]), physical examination together with blood pressure measurement, urinalysis (assessing proteinuria), urine culture, and serum creatinine in patients with bilateral renal parenchymal abnormalities. Voiding cystourethrography still remains the gold standard in diagnosing VUR.

| Recommendation for diagnostic evaluation | Strength rating |
|---|------------------------|
| Use voiding cystourethrography for the diagnosis of vesicoureteric reflux. Contrast-enhanced voiding urosonography is another option. | Weak |

| Recommendation for screening | Strength rating |
|--|------------------------|
| Inform parents of children with vesicoureteric reflux (VUR) that siblings and offspring have a high prevalence of VUR. | Strong |

| Recommendations for treatment | Strength rating |
|---|------------------------|
| Initially treat all symptomatic patients diagnosed within the first year of life with continuous antibiotic prophylaxis, regardless of the grade of reflux or presence of renal scars. | Weak |
| Offer immediate, parenteral antibiotic treatment for febrile breakthrough infections. | Strong |
| Initially manage all children presenting at age one to five years conservatively. | Strong |
| Offer close surveillance without antibiotic prophylaxis to children presenting with lower grades of reflux and without symptoms. | Strong |
| Ensure that a detailed investigation for the presence of lower urinary tract dysfunction (LUTD) is done in all and especially in children after toilet-training. If LUTD is found, the initial treatment should always be for LUTD. | Strong |
| Offer reimplantation or endoscopic correction to patients with frequent breakthrough infections. | Weak |

| | |
|---|--------|
| Offer reimplantation to patients with persistent high-grade reflux and endoscopic correction for lower grades of reflux. | Strong |
| Offer surgical repair to children above the age of one presenting with high-grade reflux and abnormal renal parenchyma. | Weak |
| Offer surgical correction, if parents prefer definitive therapy to conservative management. | Strong |
| Select the most appropriate management option based on: <ul style="list-style-type: none"> • the presence of renal scars; • clinical course; • the grade of reflux; • ipsilateral renal function; • bilaterality; • bladder/bowel function; • associated anomalies of the urinary tract; • age and gender; • compliance; • parental preference. | Weak |
| In high-risk patients who already have renal impairment, a more aggressive, multi-disciplinary approach is needed. | Strong |

URINARY STONE DISEASE

Paediatric stone disease is an important clinical problem in paediatric urology practice. Due to its recurrent nature, every effort should be made to discover the underlying metabolic abnormality so that it can be treated appropriately.

Presentation tends to be age-dependent, with symptoms such as flank pain and haematuria being more common in older children. Infantile urolithiasis appears to be a separate entity since the aetiology and the clinical course is different than in other age groups. Non-specific symptoms (e.g., irritability, vomiting) are common in very young children. Adequate fluid intake and restricting the use of salt within daily allowance range are the general recommendations besides the specific medical treatment against the detected metabolic abnormalities. With the advance of technology, stone management has changed from open surgical approaches to endoscopic techniques that are less invasive.

Table 1: Recommendations for interventional management in paediatric stones

| Stone size and localisation* | Primary treatment option | Alternative treatment options | Comment |
|--|--------------------------|---------------------------------------|--|
| Infant micro-lithiasis (< 3mm, any location) | Observation | Intervention and/or medical treatment | Individualised decision according to size progression, symptoms and metabolic factors. |
| Staghorn stones | PCNL | Open/SWL | Multiple sessions and accesses with PCNL may be needed. Combination with SWL may be useful. |
| Pelvis < 10 mm | SWL | RIRS/PCNL | |
| Pelvis 10-20 mm | SWL/PCNL/RIRS | | Multiple sessions with SWL may be needed. PCNL and RIRS have a similar recommendation grade. |
| Pelvis > 20 mm | PCNL | SWL/RIRS | Multiple sessions with SWL may be needed. |
| Lower pole calyx < 10mm | Observation or SWL | PCNL/RIRS | Stone clearance after SWL is lower than other locations. |

| | | | |
|-------------------------|--|----------|---|
| Lower pole calyx > 10mm | PCNL | RIRS/SWL | Anatomical variations are important for complete clearance after SWL. |
| Upper ureteric stones | SWL | URS | Flexible scopes may be needed in case of retroimpulsion. |
| Lower ureteric stones | URS | SWL | |
| Bladder stones | Endoscopic (transurethral or percutaneous) | SWL/Open | Open is easier and with less operative time with large stones. |

* Cystine and uric acid stones excluded.

PCNL = percutaneous nephrolithotomy; SWL = shockwave lithotripsy; RIRS = retrograde intrarenal surgery; URS = ureteroscopy.

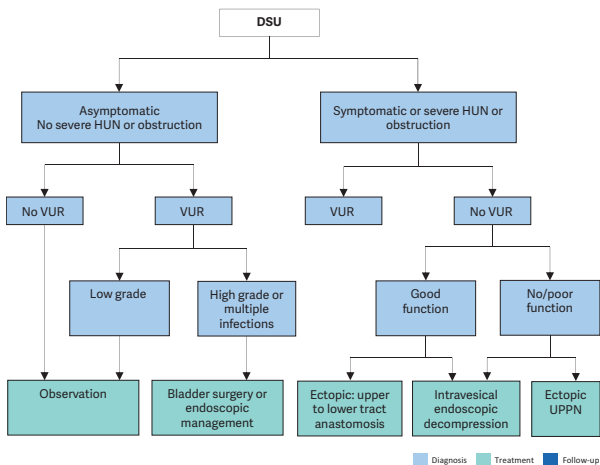
| Recommendations | Strength rating |
|---|-----------------|
| Use plain abdominal X-ray and ultrasound as the primary imaging techniques for the diagnosis and follow-up of stones. | Strong |
| Use low-dose non-contrast computed tomography in cases with a doubtful diagnosis, especially of ureteral stones or complex cases requiring surgery. | Strong |

| | |
|---|--------|
| Perform a metabolic evaluation in any child with urinary stone disease. Any kind of interventional treatment should be supported with medical treatment for the underlying metabolic abnormality, if detected. | Strong |
| Limit open surgery under circumstances in which the child is very young with large stones, in association with congenital problems requiring surgical correction and/or with severe orthopaedic deformities that limit positioning for endoscopic procedures. | Strong |
| Observe infant microlithiasis, unless symptoms occur or size increases significantly. | Strong |

OBSTRUCTIVE PATHOLOGY OF RENAL DUPLICATION: URETEROCELE AND ECTOPIC URETER

Ureterocele and ectopic ureter are the two main anomalies associated with complete renal duplication. Antenatal US detects both conditions in the majority of cases if associated with obstruction, and diagnosis is confirmed after birth. Later in life, these anomalies are revealed by clinical symptoms: UTI, pain, calculus formation, disturbances of micturition, and urinary incontinence. There is a wide variation of symptoms in patients with ureterocele (from the asymptomatic patient to urosepsis, urinary retention and upper tract dilatation after birth). Ectopic ureter is less frequent than ureterocele and more common in females with some remaining asymptomatic.

Figure 13: Algorithm for the management of duplex system ureteroceles after the first 3-6 months of life



DSU = duplex system ureterocele; HUN = hydroureteronephrosis; UPPN = upper pole partial nephrectomy; VUR = vesicoureteric reflux to the lower pole.

| Recommendations | | Strength rating |
|--------------------|---|-----------------|
| Ureterocele | | |
| Diagnosis | Use ultrasound (US), radionuclide studies (mercaptoacetyltriglycine [MAG3]/dimercaptosuccinic acid [DMSA]), voiding cystourethrography (VCUG), magnetic resonance urography, high-resolution magnetic resonance imaging (MRI), and cystoscopy to assess function, to detect reflux and rule out ipsilateral compression of the lower pole and urethral obstruction. | Weak |
| Treatment | Select treatment based on symptoms, function and reflux as well on surgical and parenteral choices: observation, endoscopic decompression, ureteral re-implantation, partial nephroureterectomy, complete primary reconstruction. Offer early endoscopic decompression to patients with an obstructing ureterocele. | Weak |

| Ectopic ureter | | |
|-----------------------|--|------|
| Diagnosis | Use US, DMSA scan, VCUG or MRI for a definitive diagnosis. | Weak |
| Treatment | In non-functioning moieties with recurrent infections, heminephro-ureterectomy is a definitive solution. Ureteral reconstruction (ureteral re-implantation/ureteroureterostomy/ ureteropyelostomy and upper-pole ureterectomy) are other therapeutic option especially in cases in which the upper pole has function worth preserving. | Weak |

DISORDERS/DIFFERENCES OF SEX DEVELOPMENT

The term 'disorders of sex development' is proposed to indicate congenital conditions with atypical development of chromosomal, gonadal or anatomical sex. Dealing with neonates with DSD requires a multi-disciplinary approach, which should include geneticists, neonatologists, paediatric and adult endocrinologists, gynaecologists, psychologists, ethicists and social workers with each team member specialised in DSD.

Table 2: Findings in a newborn suggesting the possibility of DSD (adapted from the American Academy of Pediatrics)

| Apparent male |
|---|
| Severe hypospadias associated with bifid scrotum |
| Undescended testis/testes with hypospadias |
| Bilateral non-palpable testes in a full-term apparently male infant |

| |
|---|
| Apparent female |
| Clitoral hypertrophy of any degree, non-palpable gonads |
| Vulva with single opening |
| Indeterminate |
| Ambiguous genitalia |

Table 3: Diagnostic work-up of neonates with disorders of sex development

| |
|--|
| History (family, maternal, neonatal) |
| Parental consanguinity |
| Previous DSD or genital anomalies |
| Previous neonatal deaths |
| Primary amenorrhoea or infertility in other family members |
| Maternal exposure to androgens |
| Failure to thrive, vomiting, diarrhoea of the neonate |
| Physical examination |
| Pigmentation of genital and areolar area |
| Hypospadias or urogenital sinus |
| Size of phallus |
| Palpable and/or symmetrical gonads |
| Blood pressure |
| Investigations |
| Blood analysis: 17-hydroxyprogesterone, electrolytes, LH, FSH, TST, cortisol, ACTH |
| Urine: adrenal steroids |
| Genetics: karyotype, next-generation sequencing-based molecular diagnostics, WES |
| Ultrasound |
| Genitogram |
| hCG stimulation test to confirm presence of testicular tissue |

| |
|--------------------------|
| Androgen-binding studies |
| Endoscopy |

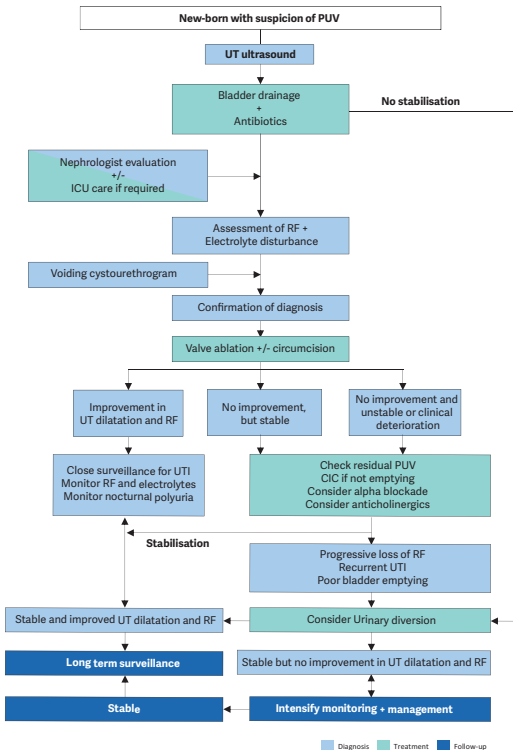
ACTH = adrenocorticotrophic hormone; FSH = follicle-stimulating hormone; hCG = human chorionic gonadotropin; LH = luteinising hormone; TST = testosterone.

| Recommendations | Strength rating |
|---|------------------------|
| Do not delay diagnosis and treatment of any neonate presenting with ambiguous genitalia since salt-loss in a 46XX CAH girl can be fatal. | Strong |
| Refer children to experienced centres where neonatology, endocrinology, (paediatric) urology, psychology and transition to adult care are guaranteed. | Strong |
| Utilise a multi-disciplinary approach and a shared decision model in patients with DSD conditions including: <ol style="list-style-type: none"> Gender assignment Genital surgery (in accordance with national regulations) Gonadectomy. | Strong |
| Do not underestimate the significant effects on psychological and psychiatric health, quality of life, personal relationships, and sexual function in individuals with DSD. | Strong |
| Ensure full disclosure to patients and caregivers that the presence of a Y-chromosome in dysgenetic gonads results in a higher malignancy risk | Strong |

CONGENITAL LOWER URINARY TRACT OBSTRUCTION

The term CLUTO is used for a foetus, which during intrauterine US screening shows a dilatation of the upper and lower urinary tract. During pregnancy the diagnosis is usually based on ultrasound examinations only. There is a broad spectrum of conditions that could cause an intra-uterine dilatation of the urinary tract. Postpartum diagnosis comprises any number of anatomical and functional disorders/anomalies/malformations causing dilatation e.g., anterior urethral valves, urethral atresia/ stenosis, prune belly syndrome, dilating VUR, cloacal malformation, prolapsing ureterocele, megacystis-microcolon-intestinal hypoperistalsis or megacystis-megaureter syndrome.

Figure 14: An algorithm on the assessment, management and follow-up of new-borns with possible PUV



CIC = clean intermittent catheterisation; OAB = overactive bladder; PUV = posterior urethral valve; RF = renal function; UT = urinary tract; UUT = upper urinary tract; VCUG = voiding cystourethrogram.

| Recommendations | Strength rating |
|--|------------------------|
| Drain the bladder in new-borns with a suspected diagnosis of infravesical obstruction and place on antibiotic prophylaxis. | Strong |
| Perform a voiding cystourethrogram in patients in whom a diagnosis of PUV is suspected. | Strong |
| Attempt endoscopic valve ablation after bladder drainage and stabilisation of the child. | Strong |
| Consider neonatal circumcision as an adjunct to antibiotic prophylaxis to decrease the risk of UTI in those with a posterior urethral valve (PUV), especially in the presence of high grade vesicoureteral reflux. | Strong |
| Offer prolonged urinary diversion (suprapubic/transurethral) for bladder drainage if the child is too small for valve ablation. | Strong |
| Use serum creatinine nadir as a prognostic marker. | Strong |
| Assess split renal function by dimercaptosuccinic acid scan or mercaptoacetyl triglycine clearance. | Strong |
| Consider high urinary diversion if bladder drainage is insufficient to drain the upper urinary tract, or in the absence of clinico-biochemical improvement. | Strong |
| Monitor and manage bladder and renal function lifelong. | Strong |

RARE CONDITIONS:

Urachal remnants

Urachal remnants originate from failure of allantois obliteration, resulting in a urachal anomaly such as urachal sinus, urachal cyst, vesico-urachal diverticulum, and patent urachus, respectively. Most often the urachal anomaly is asymptomatic, but it occasionally may become infected, may cause urinary symptoms, or may develop a urachal carcinoma in later life.

| Recommendations | Strength rating |
|---|-----------------|
| Manage asymptomatic urachal remnants (UR) conservatively. | Strong |
| Manage symptomatic URs initially conservatively with observation and/or antibiotics, and preferably with elective surgical removal if persistent. | Weak |
| Remove symptomatic URs either using an open, laparoscopic or robotic approach. | Strong |
| Do not perform a voiding cystourethrography in an asymptomatic UR. | Weak |

Papillary tumours of the bladder

Papillary tumours of the bladder in children and adolescents are extremely rare and are different from papillary tumours in adults.

| Recommendations | Strength rating |
|--|-----------------|
| Ultrasound is the first investigation of choice for the diagnosis of paediatric bladder tumours. | Strong |

| | |
|--|--------|
| Cystoscopy should be reserved if a bladder tumour is suspected on imaging for diagnosis and treatment. | Strong |
| After histological confirmation, inflammatory myofibroblastic bladder tumours should be resected locally. | Weak |
| Follow-up should be every three to six months in the first year, and thereafter at least annually with urinalysis and an ultrasound for at least five years. | Weak |
| Have a high index of suspicion of eosinophilic cystitis (EC) in protracted urinary tract symptoms unresponsive to regular treatment. | Strong |
| Remove any possible allergens as the obvious first step in managing EC. | Strong |
| Eosinophilic cystitis can be managed medically with corticosteroids, antibiotics, anticholinergics, and antihistamines, in addition to cyclosporine A. | Weak |
| Manage nephrogenic adenoma (NA) by resection either transurethraly or by open excision. | Strong |
| Regular endoscopic follow-up especially for augmented patients with NA is justified. | Weak |

Penile lesions

Paediatric lesions of the penis are uncommon but an important part of the paediatric urological practice. The most common of these lesions are cystic penile lesions followed by vascular malformations and neurogenic lesions. Soft tissue tumours of the male external genitalia are uncommon, but have been described in the paediatric age group and can be malignant.

| Recommendations | Strength rating |
|---|-----------------|
| Treatment of penile cystic lesions is by total surgical excision, it is mainly indicated for cosmetic or symptomatic (e.g., infection) reasons. | Weak |
| Propranolol is currently first-line treatment for infantile hemangiomas. | Strong |

Penile lymphedema

Paediatric lymphedema is usually primary and generally very rare. Inefficient lymphatic drainage leads to accumulation of subcutaneous lymph causing tissue swelling and inflammation and subsequently stimulates adipose deposition and fibrosis further exacerbating enlargement. With time the edematous tissue becomes vulnerable to infection, chronic cutaneous changes and disfigurement. Complications may ensue such as phimosis, haematuria, bleeding, bladder outlet obstruction, pain, dysuria, lymphorrhoea and severe psychological distress due to resultant deformity.

| Recommendations | Strength rating |
|---|-----------------|
| Conservative management is the first-line treatment for penile lymphedema. | Strong |
| In symptomatic cases or in patients with functional impairment, surgical intervention may become necessary for penile lymphedema. | Weak |

PAEDIATRIC UROLOGICAL TRAUMA/EMERGENCIES

In about 3% of children seen at paediatric hospital trauma centres, there is significant involvement of the genitourinary tract. This is caused by either blunt injuries from falls, car accidents, sports injuries, physical assault, and sexual abuse, or

penetrating injuries, usually due to falls onto sharp objects or from gunshot or knife wounds.

Paediatric renal trauma

Table 4: Renal injury classified according to the kidney injury scale of the American Association for the Surgery of Trauma

| Grade | Type of injury | Description |
|--------------|----------------------------|---|
| I | Haematoma and/or contusion | Subcapsular hematoma and/or parenchymal contusion without laceration. |
| II | Haematoma | Perirenal hematoma confined to Gerota fascia. |
| | Laceration | Renal parenchymal laceration \leq 1 cm depth without urinary extravasation. |
| III | Laceration | Renal parenchymal laceration $>$ 1 cm depth without collecting system rupture or urinary extravasation. |
| | Vascular | Any injury in the presence of a kidney vascular injury or active bleeding contained within Gerota fascia. |

| | | |
|----|------------|--|
| IV | Laceration | <ul style="list-style-type: none"> - Parenchymal laceration extending into urinary collecting system with urinary extravasation; - Renal pelvis laceration and/or complete ureteropelvic disruption. |
| | Vascular | <ul style="list-style-type: none"> - Segmental renal vein or artery injury; - Active bleeding beyond Gerota fascia into the retroperitoneum or peritoneum; - Segmental or complete kidney infarction(s) due to vessel thrombosis without active bleeding. |
| V | Laceration | Shattered kidney with loss of identifiable parenchymal renal anatomy. |
| | Vascular | <ul style="list-style-type: none"> - Main renal artery or vein laceration or avulsion of hilum; - Devascularised kidney with active bleeding. |

Vascular injury is defined as a pseudoaneurysm or arteriovenous fistula and appears as a focal collection of vascular contrast that decreases in attenuation with delayed imaging. Active bleeding from a vascular injury presents as vascular contrast, focal or diffuse, that increases in size or attenuation in delayed phase. Vascular thrombosis can lead to organ infarction. Grade based on highest grade assessment made on imaging, at operation or on pathologic specimen. More than one grade of kidney injury may be present and should be classified by the higher grade of injury. Advance one grade for bilateral injuries up to Grade III.

| Recommendations | Strength rating |
|--|------------------------|
| Use imaging in all children who have sustained a blunt or penetrating trauma with any level of haematuria, especially when the history reveals a deceleration trauma, direct flank trauma or a fall from a height. | Strong |
| Use contrast-enhanced scanning with delayed images for diagnostic and staging purposes. | Strong |
| Manage most injured kidneys conservatively. | Strong |
| Offer surgical intervention in case of haemodynamic instability and a Grade V renal injury. | Strong |

Paediatric ureteral trauma

| Recommendations | Strength rating |
|--|------------------------|
| Diagnose suspected ureteral injuries by retrograde pyelogram. | Strong |
| Manage ureteral injuries endoscopically, using internal stenting or drainage of an urinoma, either percutaneously or via a nephrostomy tube. | Weak |

Paediatric bladder injuries

| Recommendations | Strength rating |
|--|-----------------|
| Use retrograde cystography to diagnose suspected bladder injuries. | Strong |
| Ensure that the bladder has been filled to its full capacity and an additional film is taken after drainage. | Strong |
| Manage extra-peritoneal bladder ruptures conservatively with a transurethral catheter left in place for seven to ten days. | Strong |
| Perform surgical exploration in cases of intra-peritoneal bladder ruptures. | Strong |

Paediatric urethral injuries

| Recommendations | Strength rating |
|---|-----------------|
| Assess the urethra by retrograde urethrogram in case of suspected urethral trauma. | Strong |
| Perform a rectal examination to determine the position of the prostate. | Strong |
| Manage urethral injuries conservatively initially if a transurethral catheter can be placed. | Strong |
| Manage posterior urethral injuries by either: <ul style="list-style-type: none">• primary drainage with a suprapubic catheter alone and delayed repair;• primary re-alignment with a transurethral catheter. | Weak |

Priapism

Priapism is a prolonged full or partial erection of the penis unrelated to sexual stimuli lasting ≥ 4 hours. Although the prevalence of priapism in children is not well reported in literature, it is considered a rare disease. The most common cause of priapism in children is sickle cell disease (SCD), which accounts for about 65% of all cases, followed by leukemia (10%), trauma (10%), idiopathic (10%) and drugs (5%). In patients with SCD, the mean age of the first episode of priapism has been shown to be fifteen years old, with 25% presenting prepubertally.

| Recommendations | Strength rating |
|---|-----------------|
| Perform a doppler ultrasonography in all patients presenting with priapism. | Strong |
| In children with ischaemic (low-flow) priapism, perform a full blood count and haemoglobinopathy screen to exclude sickle cell disease or other haematological disorders. | Strong |
| Adopt a multidisciplinary approach when managing patients with SCD-associated priapism. | Strong |
| Use a step-wise approach starting with the least invasive therapy in patients with ischaemic (low-flow) priapism. | Strong |
| Manage neonatal and non-ischaemic (high-flow) priapism conservatively in the initial management period. | Strong |

PERI-OPERATIVE FLUID MANAGEMENT

Children have a different total body fluid distribution, renal physiology and electrolyte requirements, as well as weaker cardiovascular compensation mechanisms, compared to adults. Therefore, special child specific requirements regarding preoperative fasting and intra- as well as post-operative fluid have to be considered and close monitoring is essential. This is especially true for interventions relieving any kind of obstruction as this may result in substantial polyuria.

Table 5: Pre-operative fasting times for elective surgery

| Ingested material | Minimum fasting period (hours) |
|-----------------------------|--------------------------------|
| Clear liquids | 1 |
| Breast milk | 3 |
| Formula milk-based products | 4 |
| Light meal | 6 |

| Recommendations | Strength rating |
|---|-----------------|
| Ensure shorter pre-operative fasting periods for elective surgeries (one hour for clear liquids, three hours for breast milk, four hours for formula milk-based products and six hours for a light meal). | Strong |
| Start early post-operative oral fluid intake in all patients scheduled for minor surgical procedures. | Strong |
| Use enhanced recovery after surgery protocols for abdominal surgery in children with pre-existing normal bowel function. | Strong |

POST-OPERATIVE PAIN MANAGEMENT

The provision of adequate pain control requires proper pain evaluation, accurate choice of drug and route of administration, and consideration of age, physical condition and type of surgery and anaesthesia.

A proposed strategy for post-operative analgesia may be as follows:

1. Intra-operative regional block and/or local wound infiltration.
2. Paracetamol + NSAID.
3. Paracetamol + NSAID + weak opioid (e.g., tramadol or codeine).
4. Paracetamol + NSAID + strong opioid (e.g., morphine, fentanyl, oxycodone or pethidine).

| Recommendations | Strength rating |
|---|-----------------|
| Prevent/treat pain in children of all ages. | Strong |
| Evaluate pain using age-compatible assessment tools. | Strong |
| Use pre-emptive and balanced analgesia in order to decrease opioids requirements. | Strong |

Thromboprophylaxis management: general information

Thromboprophylaxis in children involves preventive measures aimed at reducing the risk of blood clot formation. Unlike adults, the majority of children do not require thromboprophylaxis after surgery. It is only considered in certain high-risk situations such as underlying medical conditions like malignancies, congenital heart disease etc.

| Recommendations | Strength rating |
|--|------------------------|
| Use physical methods for venous thromboembolism (VTE) risk reduction in older children and adolescents who are at increased risk of VTE. | Strong |
| Consider low molecular weight heparin VTE prophylaxis in children, particularly adolescents, with additional risk factors. | Strong |

Pre-medication management: general information

The majority of children undergoing anaesthesia and surgery develop anxiety that could lead to adverse reactions. Many factors may influence preoperative anxiety. Anxiety and distress can be prevented or relieved combining: premedication, distraction techniques and parental or caregivers presence. Non-pharmacological age-appropriate methods such as play therapy, toys, storybooks, videos, tablet, mobile phone, can all be useful. A successful plan must therefore take into account the age and temperament of the child.

| Recommendations | Strength rating |
|--|------------------------|
| Use non-pharmacological age-appropriate premedication methods to decrease anxiety levels in children before surgery. | Weak |
| Use pharmacological premedication to decrease anxiety levels in children and monitor for potential side effects. | Strong |

BASIC PRINCIPLES OF LAPAROSCOPIC SURGERY IN CHILDREN

Laparoscopy in children requires specific anaesthetic precautions. Physiological effects of CO₂ pneumoperitoneum, positioning of the patient and operative time need to be considered by the anaesthesiology team.

| Recommendations | Strength rating |
|--|-----------------|
| Use lower intra-abdominal pressure (6-8 mmHg) during laparoscopic surgery in infants and smaller children. | Strong |
| Use open access for laparoscopy in infants and smaller children. | Strong |
| Monitor for laparoscopy-related cardiac, pulmonary and diuretic responses. | Strong |

TRANSITIONAL UROLOGY

Transition in urology is the process whereby an adolescent or young adult with a congenital or acquired urogenital anomaly transitions into adult services and begins to assume increasing responsibility for their own health care, becoming the primary decision maker in their own care. The main goal of the transition process in urology is to preserve renal function, to optimise quality of life by achieving and maintaining continence, to treat and manage issues related to sexuality and infertility, and to monitor for progression of the disease process or complications related to interventions.

| Recommendations | Strength rating |
|---|------------------------|
| Develop a standardised transition-of-care program and collaborate with adult providers to facilitate safe, successful, and sustainable transition. | Strong |
| Start transition at the onset of adolescence involving both paediatric and adult urology providers in a multidisciplinary approach to ensure better transition readiness and subsequent adult clinic adherence. | Weak |
| Use a validated transition assessment tool to objectively assess for transition readiness. | Strong |

This short booklet text is based on the more comprehensive EAU Paediatric Urology Guidelines 978-94-92671-29-5, available at their website, <http://www.uroweb.org/guidelines>.