

EAU GUIDELINES ON PAEDIATRIC UROLOGY

(Text update March 2021)

C. Radmayr (Chair), G. Bogaert, H.S. Dogan, J.M. Nijman (Vice-chair), Y.F.H. Rawashdeh, M.S. Silay, R. Stein, S. Tekgul
Guidelines Associates: N. Bhatt, L.A 't Hoen, J. Quaedackers

Introduction

Due to the scope of the extended Guidelines on Paediatric Urology, only a short introduction of the individual chapter in combination with recommendations can be given in this pocket version. Additionally, some algorithms and flow charts are enclosed. For further details please refer to the full length version.

PHIMOSIS

Phimosis is either primary (physiological), with no sign of scarring, or secondary (pathological), resulting from scarring due to conditions such as balanitis xeroticaobliterans.

Childhood circumcision should not be recommended without a medical reason. An absolute indication for circumcision is secondary phimosis. Contraindications are congenital anomalies of the penis, particularly hypospadias or buried penis, as the foreskin may be required for a reconstructive procedure.

Paraphimosis is characterised by retracted foreskin with the constrictive ring localised at the level of the sulcus.

Recommendations	Strength rating
Offer corticoid ointment or cream to treat primary symptomatic phimosis.	Strong
Circumcision will also solve the problem.	Strong
Treat primary phimosis in patients with recurrent urinary tract infection and/or with urinary tract abnormalities.	Strong
Circumcise in case of lichen sclerosus or scarred phimosis.	Strong
Treat paraphimosis by manual reposition and proceed to surgery if it fails.	Strong
Avoid retraction of asymptomatic preputial adhesions.	Weak

UNDESCENDED TESTIS

Cryptorchidism or undescended testis is one of the most common congenital malformations of male neonates with an incidence of 1.0-4.6% of full-term neonates. Boys with one undescended testis have a lower fertility rate whereas boys with bilateral undescended testes suffer both, lower fertility and paternity rates. In addition, boys who are treated for an undescended testis have an increased risk of developing testicular malignancy. Therefore, screening and self-examination both during and after puberty is recommended.

Figure 1: Classification of undescended testes

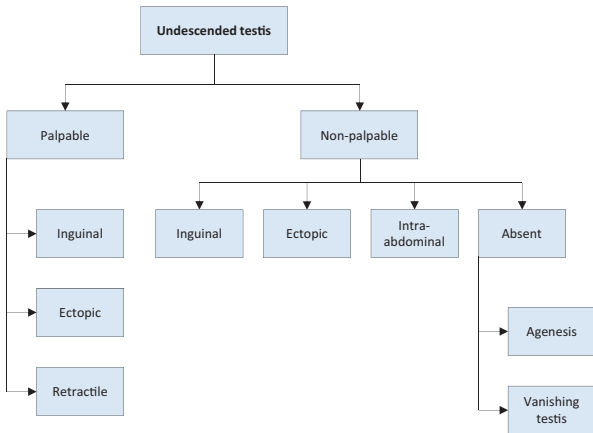
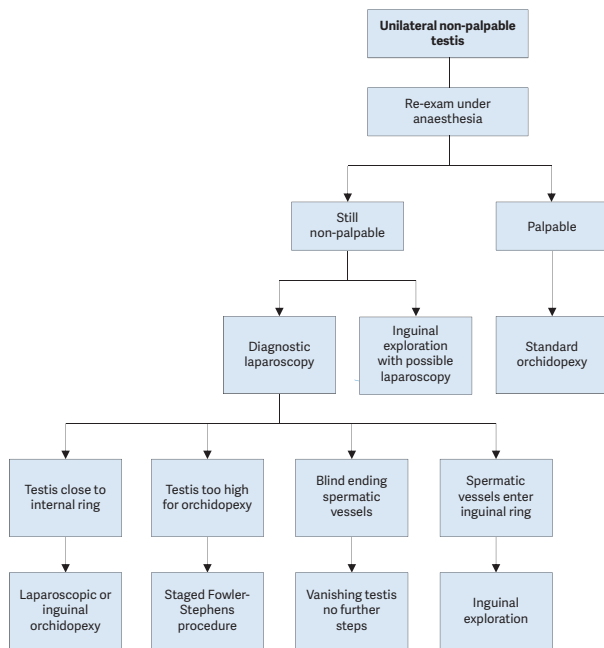


Figure 2: Treatment of unilateral non-palpable undescended testes



Recommendations	Strength rating
Do not offer medical or surgical treatment for retractile testes instead undertake close follow-up on a yearly basis until puberty.	Strong
Perform surgical orchidolysis and orchidopexy before the age of twelve months, and by eighteen months at the latest.	Strong
Evaluate male neonates with bilateral non-palpable testes for possible disorders of sex development.	Strong
Perform a diagnostic laparoscopy to locate an intra-abdominal testicle.	Strong
Hormonal therapy in unilateral undescended testes is of no benefit for future paternity.	Strong
Offer endocrine treatment in case of bilateral undescended testes.	Weak
Inform the patient/caregivers about the increased risk of a later malignancy with an undescended testis in a post-pubertal boy or older and discuss removal in case of a contralateral normal testis in a scrotal position.	Weak

TESTICULAR TUMOURS IN PREPUBERTAL BOYS

Testicular tumours account for approximately 1-2% of all paediatric solid tumours. In prepubertal boys most intratesticular tumours are benign and teratomas and yolk sac tumours more common than germ cell tumours, whereas post-puberty the tumours are most likely malignant.

Recommendations	Strength rating
High-resolution ultrasound (7.5 – 12.5 MHz), preferably a doppler ultrasound, should be performed to confirm the diagnosis.	Strong
Alpha-fetoprotein should be determined in prepubertal boys with a testicular tumour before surgery.	Strong
Surgical exploration should be done with the option for frozen section, but not as an emergency operation.	Strong
Organ-preserving surgery should be performed in all benign tumours.	Strong
Staging (MRI abdomen/CT chest) should only be performed in patients with a malignant tumour to exclude metastases.	Strong
Magnetic resonance imaging should only be performed in patients with the potential malignant Leydig or Sertoli-cell-tumours to rule out lymph node enlargement.	Weak
Patients with a non-organ confined tumour should be referred to paediatric oncologists post-operatively.	Weak

HYDROCELE

A communicating hydrocele vacillates in size, usually relative to activity. It is diagnosed by medical history and physical investigation, the swelling is translucent, and transillumination of the scrotum confirms the diagnosis. Non-communicating hydroceles are found secondary to minor trauma, testicular torsion, epididymitis, or varicocele operation, or may appear as a recurrence after primary repair of a communicating hydrocele.

Recommendations	Strength rating
In the majority of infants, observe hydrocele for twelve months prior to considering surgical treatment.	Strong
Perform early surgery if there is suspicion of a concomitant inguinal hernia or underlying testicular pathology.	Strong
Perform a scrotal ultrasound in case of doubt about the character of an intrascrotal mass.	Strong
Do not use sclerosing agents because of the risk for chemical peritonitis.	Strong

ACUTE SCROTUM

Acute scrotum is a paediatric urological emergency, most commonly caused by torsion of the testis or appendix testis, or epididymitis/epididymo-orchitis.

Recommendations	Strength rating
Testicular torsion is a paediatric urological emergency and requires immediate treatment.	Strong
In neonates with testicular torsion perform orchidopexy of the contralateral testicle. In prenatal torsion the timing of surgery is usually dictated by clinical findings.	Weak
Base the clinical decision on physical examination. The use of Doppler ultrasound to evaluate acute scrotum is useful, but this should not delay the intervention.	Strong

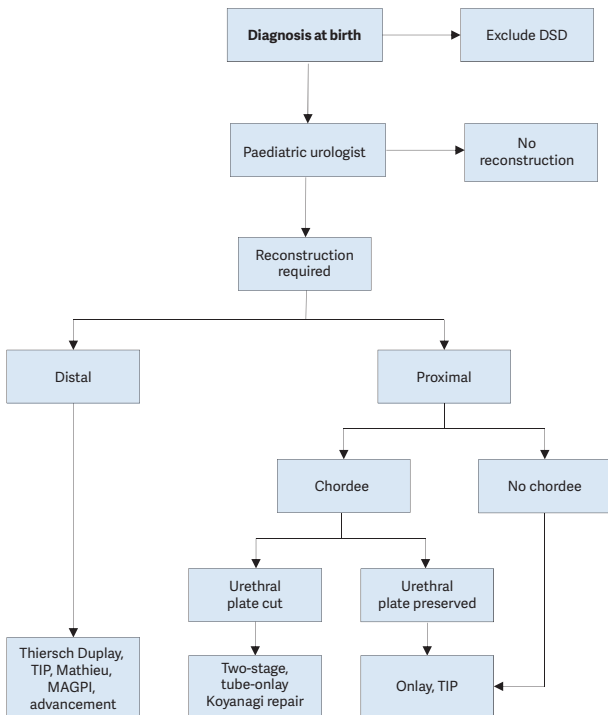
Manage torsion of the appendix testis conservatively. Perform surgical exploration in equivocal cases and in patients with persistent pain.	Strong
Perform urgent surgical exploration in all cases of testicular torsion within 24 hours of symptom onset. In prenatal torsion the timing of surgery is usually dictated by clinical findings.	Strong

HYPOSPADIAS

Hypospadias are usually classified according to the anatomical location of the proximally displaced urethral orifice.

Patients with hypospadias should be diagnosed at birth. The diagnostic evaluation also includes an assessment of associated anomalies, which include cryptorchidism and open processus vaginalis or inguinal hernia. Severe hypospadias with unilaterally or bilaterally impalpable testis, or with ambiguous genitalia, require a complete genetic and endocrine work-up immediately after birth to exclude disorders of sex development, especially congenital adrenal hyperplasia.

Figure 3: Algorithm for the management of hypospadias



DSD = disorders of sex development; TIP = tubularised incised plate urethroplasty; MAGPI = meatal advancement and granuloplasty incorporated.

Recommendations	Strength rating
At birth, differentiate isolated hypospadias from disorders of sex development which are mostly associated with cryptorchidism or micropenis.	Strong
Counsel caregivers on functional indications for surgery, aesthetically feasible operative procedures (psychological, cosmetic indications) and possible complications.	Strong
In children diagnosed with proximal hypospadias and a small appearing penis, reduced glans circumference or reduced urethral plate, pre-operative hormonal androgen stimulation treatment is an option but the body of evidence to accentuate its harms and benefits is inadequate.	Weak
For distal hypospadias, offer Duplay-Thiersch urethroplasty, original and modified tubularised incised plate urethroplasty; use the onlay urethroplasty or two-stage procedures in more severe hypospadias. A treatment algorithm is presented (Figure 3). Correct significant (> 30°) curvature of the penis.	Weak
Ensure long-term follow-up to detect urethral stricture, voiding dysfunctions and recurrent penile curvature, ejaculation disorder, and to evaluate patient's satisfaction.	Strong
Use validated objective scoring systems to assist in evaluating the functional and cosmetic outcome.	Strong

CONGENITAL PENILE CURVATURE

Congenital penile curvature presents penile bending of a normally formed penis due to corporal disproportion. Most of the cases are ventral deviations. Curvature $> 30^\circ$ is considered clinically significant; curvature $> 60^\circ$ may interfere with satisfactory sexual intercourse in adulthood. The treatment is surgical.

Recommendations	Strength rating
Ensure that a thorough medical history is taken and a full clinical examination done to rule out associated anomalies in boys presenting with congenital curvature.	Strong
Provide photo documentation of the erect penis from different angles as a prerequisite in the pre-operative evaluation.	Strong
Perform surgery after weighing aesthetic as well as functional implications of the curvature.	Weak
At the beginning as well as at the end of surgery, perform artificial erection tests.	Strong

VARICOCELE IN CHILDREN AND ADOLESCENTS

Varicocele is unusual in boys under ten years of age, but becomes more frequent at the beginning of puberty. Fertility problems will arise in about 20% of adolescents with varicocele. Testicular catch-up growth and improvement in sperm parameters after varicocelectomy has been reported in adolescents. Varicocele is mostly asymptomatic, rarely causing pain at this age. Diagnosis and classification depends upon the clinical finding and US investigation.

Figure 4: Algorithm for the diagnosis of varicocele in children and adolescents

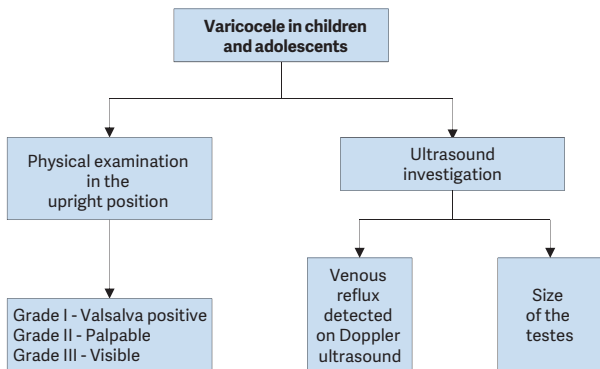
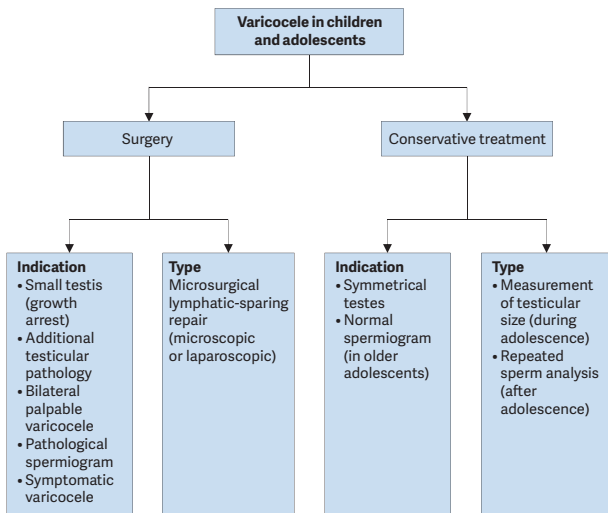


Figure 5: Algorithm for the management of varicocele in children and adolescents

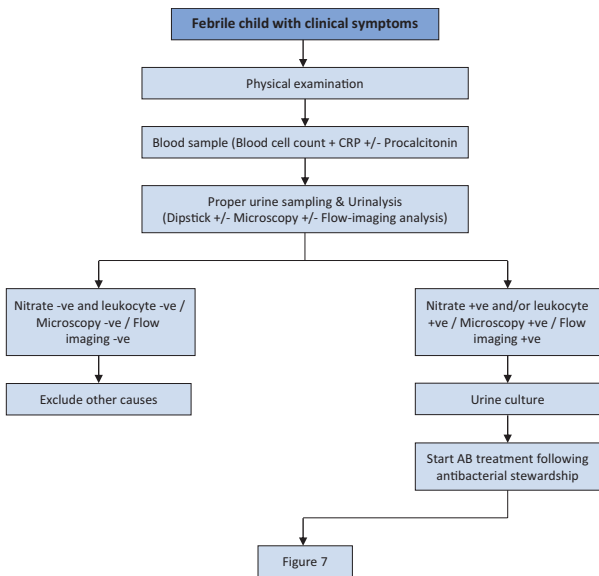


Recommendations	Strength rating
Examine varicocele in the standing position and classify into three grades.	Strong
Use scrotal ultrasound to detect venous reflux without Valsalva manoeuvre in the supine and upright position and to discriminate testicular hypoplasia.	Strong
In all pre-pubertal boys with a varicocele and in all isolated right varicoceles perform standard renal ultrasound to exclude a retroperitoneal mass.	Strong

<p>Inform caregivers and patients and offer surgery for:</p> <ul style="list-style-type: none"> • varicocele associated with a persistent small testis (size difference of > 2 mL or 20%); • varicocele associated with additional testicular condition affecting fertility (cryptorchidism, history of torsion, trauma); • varicocele associated with pathological sperm quality (in older adolescents); • symptomatic varicocele. 	Weak
<p>Use some form of optical magnification (microscopic or laparoscopic magnification) for surgical ligation.</p>	Strong
<p>Use lymphatic-sparing varicocelectomy to prevent hydrocele formation and testicular hypertrophy.</p>	Strong

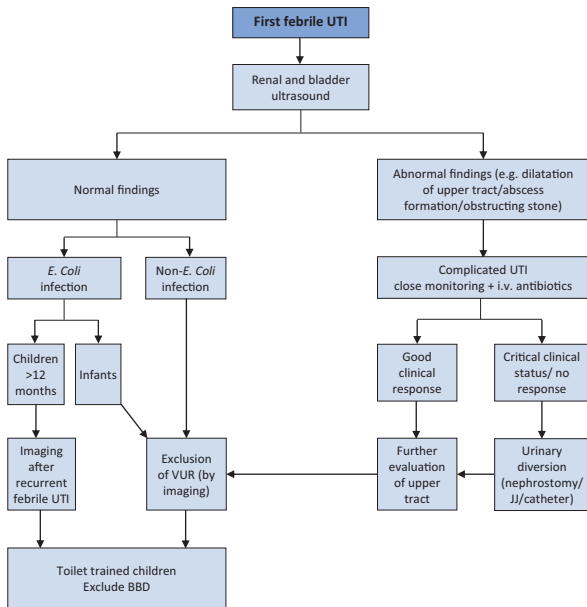
URINARY TRACT INFECTIONS IN CHILDREN

Figure 6: Algorithm for the management of a first febrile UTI



CRP = C-reactive protein; AB = antibiotic

Figure 7: Diagnosis strategy for first febrile UTI



BBD = bladder and bowel dysfunction; VUR = vesicoureteral reflux; i.v. = intravenous.

Recommendations	Strength rating
Take a medical history, assess clinical signs and symptoms and perform a physical examination to diagnose children suspected of having a urinary tract infection (UTI).	Strong

Exclude bladder- and bowel dysfunction in any toilet-trained child with febrile and/or recurrent UTI.	Strong
Clean catch urine can be used for screening for UTI. Bladder catheterisation and suprapubic bladder aspiration to collect urine can be used for urine cultures.	Strong
Do not use plastic bags for urine sampling in non-toilet-trained children since it has a high risk of false-positive results.	Strong
Midstream urine is an acceptable technique for toilet-trained children.	Strong
The choice between oral and parenteral therapy should be based on patient age; clinical suspicion of urosepsis; illness severity; refusal of fluids, food and/or oral medication; vomiting; diarrhoea; non-compliance; complicated pyelonephritis.	Strong
Treat febrile UTIs with four to seven day courses of oral or parenteral therapy.	Strong
Treat complicated febrile UTI with broad-spectrum antibiotics.	Strong
Offer long-term antibacterial prophylaxis in case of high susceptibility to UTI and risk of acquired renal damage and lower urinary tract symptoms.	Strong
In selected cases consider dietary supplements as an alternative or add-on preventive measure.	Strong
In infants with febrile UTI use renal and bladder ultrasound to exclude obstruction of the upper and lower urinary tract within 24 hours.	Strong

In infants, exclude vesicoureteral reflux after first episode of febrile UTI with a non- <i>E. Coli</i> infection. In children more than one year of age with an <i>E. Coli</i> infection, exclude VUR after the second febrile UTI.	Strong
--	--------

DAY-TIME LOWER URINARY TRACT DYSFUNCTION

Urinary incontinence in children may be caused by congenital or neurologic abnormalities, however, many children have functional bladder problems for which the term day-time lower urinary tract (LUT) conditions is used. Day-time LUTD has a high prevalence ranging between 1%-20%. Symptoms can be classified as filling-phase (storage) dysfunctions and voiding-phase (emptying) dysfunctions.

Table 1: Management algorithm

Children above 5 years of age applying with LUTS
DIAGNOSTIC WORK-UP
Voiding diary 2-3 full days minimum
Bristol Stool scale
Physical exam - To exclude neurogenic pathology or anatomic problems (meatal stenosis, labial fusion)
Urinalysis - To exclude presence of UTO or any other pathology (DM, DI)
Uroflowmetry and PVR determination (USG or bladder scan) - To evaluate urine flow and emptying efficacy
Questionnaires (optional) - To evaluate voiding and bowel habits, wetting severity/frequency, fluid intake, quality of life

<p>Ultrasonography (optional)</p> <ul style="list-style-type: none"> - To determine bladder wall thickness, upper tract changes, signs of constipation
<p>Urodynamic studies (not required unless refractory to management)</p>
<p>VCUG (only required if recurrent febrile UTI is present)</p>
<p>MANAGEMENT</p>
<ul style="list-style-type: none"> - If UTI is present, treat UTI first - If constipated, treat bowel first with dietary changes and laxatives - Urotherapy is initial therapy in all cases to maintain controlled fluid intake, regular and efficient bladder emptying - Medical treatment (anticholinergics); if OAB symptoms dominate and persist despite urotherapy - Antibiotic prophylaxis: in case of recurrent UTI - Biofeedback is optional as first line therapy as part of urotherapy program; otherwise it is recommended if refractory to urotherapy - Neural stimulation or Botulinum Toxin A injection in detrusor is suggested if refractory to urotherapy and medical treatment but is still experimental

Recommendations	Strength rating
Use two day voiding diaries and/or structured questionnaires for objective evaluation of symptoms, voiding drinking habits and response to treatment.	Strong
Use a stepwise approach, starting with the least invasive treatment in managing day-time lower urinary tract dysfunction in children.	Weak

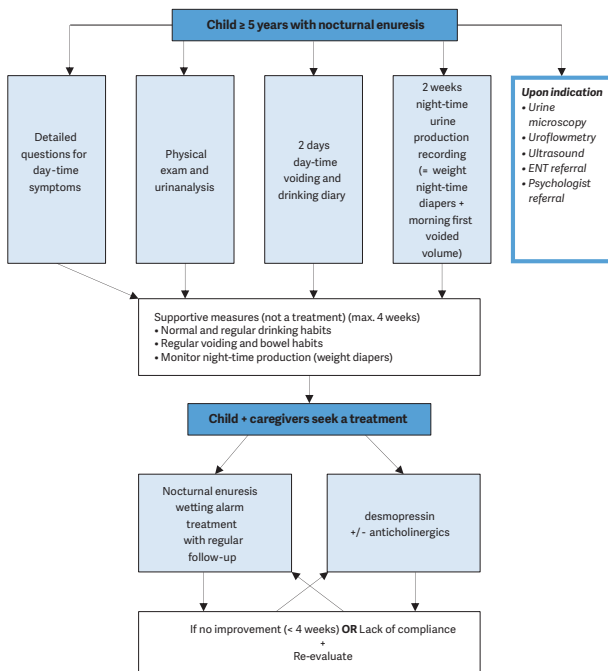
Initially offer urotherapy involving bladder rehabilitation and bowel management.	Weak
If bladder bowel dysfunction is present, treat bowel dysfunction first, before treating the lower urinary tract condition.	Weak
Use pharmacotherapy (mainly antispasmodics and anticholinergics) as second-line therapy in overactive bladder.	Strong
Use antibiotic prophylaxis if there are recurrent infections.	Weak
Re-evaluate in case of treatment failure; this may consist of (video) urodynamics MRI of lumbosacral spine and other diagnostic modalities, guiding to off-label treatment which should only be offered in highly experienced centres.	Weak

MONOSYMPTOMATIC NOCTURNAL ENURESIS - BEDWETTING

Monosymptomatic nocturnal enuresis is incontinence during the night without daytime symptoms above the age of five years. Due to an imbalance between night-time urine output and night-time bladder capacity, the bladder can easily become full at night, and the child will either wake-up to empty the bladder or will void during sleep.

A voiding diary, registering the day-time bladder function and the night-time urine output will help guide the treatment.

Figure 8: A stepwise assessment and management options for nocturnal enuresis



ENT = ear, nose, throat

Recommendations	Strength rating
Do not treat children less than five years of age in whom spontaneous cure is likely, but inform the family about the involuntary nature, the high incidence of spontaneous resolution and the fact that punishment will not help to improve the condition.	Strong
Use voiding diaries or questionnaires to exclude day-time symptoms.	Strong
Perform a urine test to exclude the presence of infection or potential causes such as diabetes insipidus.	Strong
Offer supportive measures in conjunction with other treatment modalities, of which pharmacological and alarm treatment are the two most important.	Strong
Offer desmopressin in proven night-time polyuria.	Strong
Offer alarm treatment in motivated and compliant families.	Strong

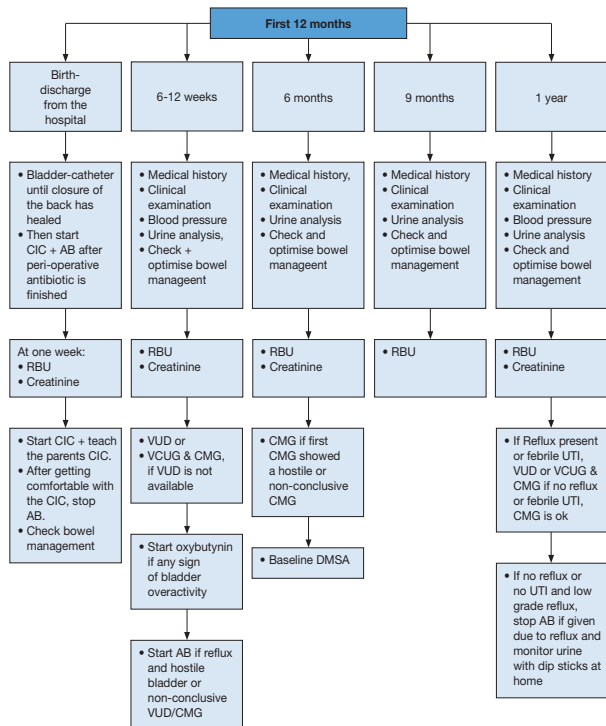
MANAGEMENT OF NEUROGENIC BLADDER

Neurogenic detrusor-sphincter dysfunction may result in different forms of lower urinary tract dysfunctions and in incontinence, urinary tract infections, vesico-ureteral reflux, renal scarring and renal insufficiency. The most common cause in children is myelodysplasia. Bladder and bowel dysfunction correlates poorly with the type and level of the spinal cord lesion. Therefore, urodynamic and functional classifications are required to define the extent of the pathology and in guiding treatment planning. Children with neurogenic bladder can also have disturbances of bowel and sexual function. The main goals of treatment are prevention of

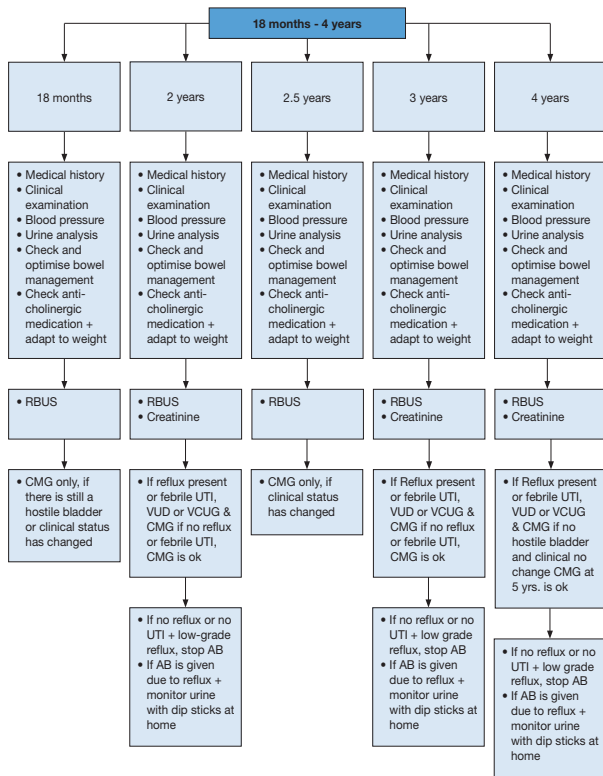
urinary tract deterioration, achievement of continence at an appropriate age and also improving quality of life.

Figure 9: Management of children with myelodysplasia with a neurogenic bladder

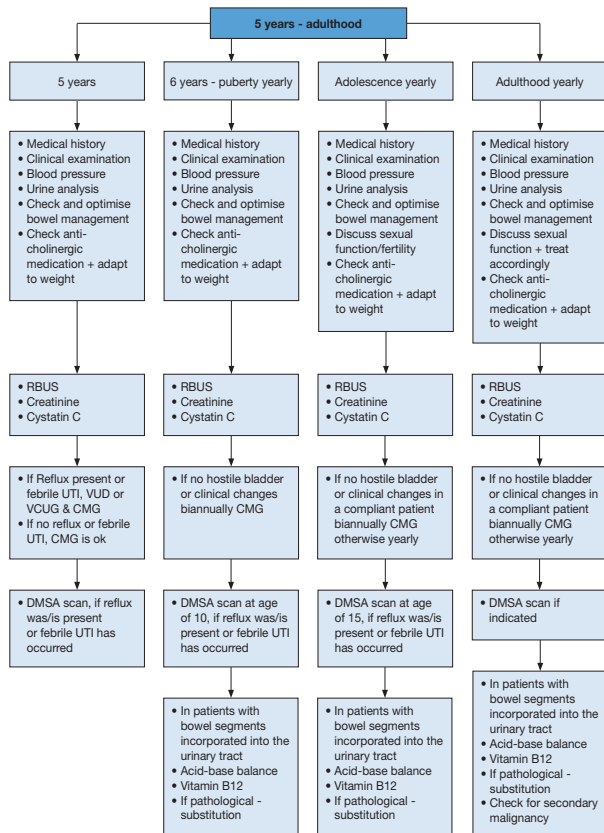
Flowchart - First year of life



Flowchart - 18 months – 4 years of age

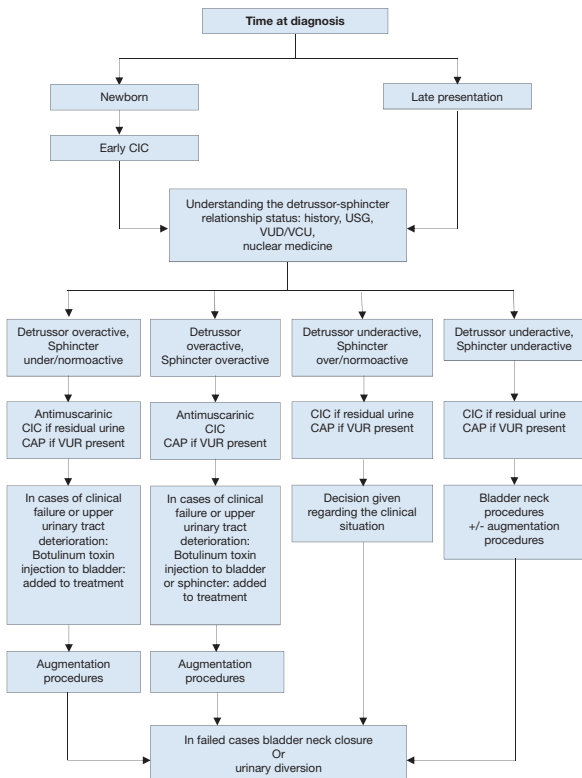


Flowchart - 5 years to adulthood



RBUS = Renal bladder ultrasound; UTI = urinary tract infection; VUD = videourodynamic; VCUG = voiding cystourethrography; CMG = cystometrogram; DMSA = dimercaptosuccinic acid.

Figure 10: Algorithm for the management of children with myelodysplasia with a neurogenic bladder



*CAP = continuous antibiotic prophylaxis;
CIC = clean intermittent catheterisation; US = ultrasound;
VCUG = voiding cystourethrography; VUD = videourodynamic;
VUR = vesicoureteric reflux.*

Recommendations	Strength rating
Urodynamic studies should be performed in every patient with spina bifida as well as in every child with high suspicion of a neurogenic bladder to estimate the risk for the upper urinary tract and to evaluate the function of the detrusor and the sphincter.	Strong
In all newborns, intermittent catheterisation (IC) should be started soon after birth. In those with a clear underactive sphincter and no overactivity starting IC may be delayed. If IC is delayed, closely monitor babies for urinary tract infections, upper tract changes (US) and lower tract (UD).	Strong
Start early anticholinergic medication in the newborns with suspicion of an overactive detrusor.	Strong
The use of suburothelial or intradetrusorial injection of onabotulinum toxin A is an alternative and a less invasive option in children who are refractory to anticholinergics in contrast to bladder augmentation.	Strong
Treatment of faecal incontinence is important to gain continence and independence. Treatment should be started with mild laxatives, rectal suppositories as well as digital. If not sufficient transanal irrigation is recommended, if not practicable or feasible, a Malone antegrade colonic enema (MACE)/Antegrade continence enema (ACE) stoma should be discussed.	Strong

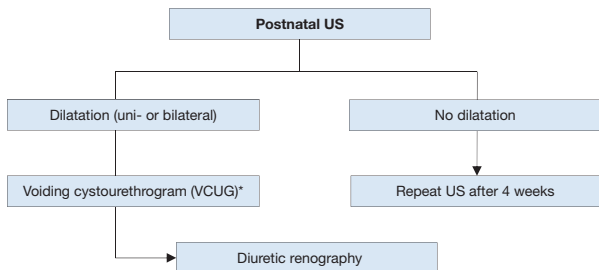
Ileal or colonic bladder augmentation is recommended in patients with therapy-resistant overactivity of the detrusor, small capacity and poor compliance, which may cause upper tract damage and incontinence. The risk of surgical and non-surgical complications and consequences outweigh the risk of permanent damage of the upper urinary tract +/- incontinence due to the detrusor.	Strong
In patients with a neurogenic bladder and a weak sphincter, a bladder outlet procedure should be offered. It should be done in most patients together with a bladder augmentation.	Weak
Creation of a continent cutaneous catheterisable channel should be offered to patients who have difficulties in performing an IC through the urethra.	Weak
A life-long follow-up of renal and reservoir function should be available and offered to every patient. Addressing sexuality and fertility starting before/during puberty should be offered.	Weak
Urinary tract infections are common in children with neurogenic bladders, however, only symptomatic UTIs should be treated.	Weak

DILATATION OF THE UPPER URINARY TRACT (UPJ AND UVJ OBSTRUCTION)

Dilatation of the upper urinary tract remains a significant clinical challenge in deciding which patient will benefit from treatment. Ureteropelvic junction obstruction is the most common pathological cause of neonatal hydronephrosis.

Megaureters (obstruction at the level of the ureterovesical junction) are the second most likely cause of pathological neonatal hydronephrosis. The widespread use of US during pregnancy has resulted in a higher detection rate for antenatal hydronephrosis. The challenge in the management of dilated upper tracts is to decide which child should be observed, which managed medically, and which requires surgical intervention.

Figure 11: Diagnostic algorithm for dilatation of the upper urinary tract



* A diagnostic work-up including VCUG must be discussed with the caregivers, as it is possible that, even if reflux is detected, it may have absolutely no clinical impact. However, it should be borne in mind that reflux has been detected in up to 25% of prenatally detected cases.

US = ultrasound.

Recommendations	Strength rating
Include serial ultrasound (US) and subsequent diuretic renogram and sometimes voiding cystourethrography in post-natal investigations.	Strong

Offer continuous antibiotic prophylaxis to the subgroup of children with antenatal hydronephrosis who are at high risk of developing urinary tract infection like uncircumcised infants, children diagnosed with hydroureteronephrosis and highgrade hydronephrosis, respectively.	Weak
Decide on surgical intervention based on the time course of the hydronephrosis and the impairment of renal function.	Weak
Offer surgical intervention in case of an impaired split renal function due to obstruction or a decrease of split renal function in subsequent studies and increased anteroposterior diameter on the US, and grade IV dilatation as defined by the Society for Fetal Urology.	Weak
Offer pyeloplasty when ureteropelvic junction obstruction has been confirmed clinically or with serial imaging studies proving a substantially impaired or decrease in function.	Weak
Do not offer surgery as a standard for primary megaureters since the spontaneous remission rates are as high as 85%.	Weak

VESICoureTERIC REFLUX IN CHILDREN

Vesicoureteric reflux presents with a wide range of severities, and the majority of reflux (VUR) patients will not develop renal scars and probably will not need any intervention. The main goal in management is the preservation of kidney function.

The diagnostic work-up should evaluate the overall health and development of the child including a detailed medical history

(including family history, and screening for lower urinary tract dysfunction [LUTD]), physical examination together with blood pressure measurement, urinalysis (assessing proteinuria), urine culture, and serum creatinine in patients with bilateral renal parenchymal abnormalities. Voiding cystourethrography still remains the gold standard in diagnosing VUR.

Recommendations	Strength rating
Inform parents of children with vesicoureteric reflux (VUR) that siblings and offspring have a high prevalence of VUR.	Strong
Use renal ultrasound (US) for screening of sibling(s).	Strong
Use voiding cystourethrography if there is evidence of renal scarring on US or a history of urinary tract infection.	Weak
Do not screen older toilet-trained children since there is no added value in screening for VUR.	Weak

Recommendations	Strength rating
Initially treat all patients diagnosed within the first year of life with continuous antibiotic prophylaxis, regardless of the grade of reflux or presence of renal scars.	Weak
Offer immediate, parenteral antibiotic treatment for febrile breakthrough infections.	Strong
Offer definitive surgical or endoscopic correction to patients with frequent breakthrough infections.	Weak

Offer open surgical correction to patients with persistent high-grade reflux and endoscopic correction for lower grades of reflux.	Strong
Initially manage all children presenting at age one to five years conservatively.	Strong
Offer surgical repair to children above the age of one presenting with high-grade reflux and abnormal renal parenchyma.	Weak
Offer close surveillance without antibiotic prophylaxis to children presenting with lower grades of reflux and without symptoms.	Strong
Ensure that a detailed investigation for the presence of lower urinary tract dysfunction (LUTD) is done in all and especially in children after toilet-training. If LUTD is found, the initial treatment should always be for LUTD.	Strong
Offer surgical correction, if parents prefer definitive therapy to conservative management.	Strong

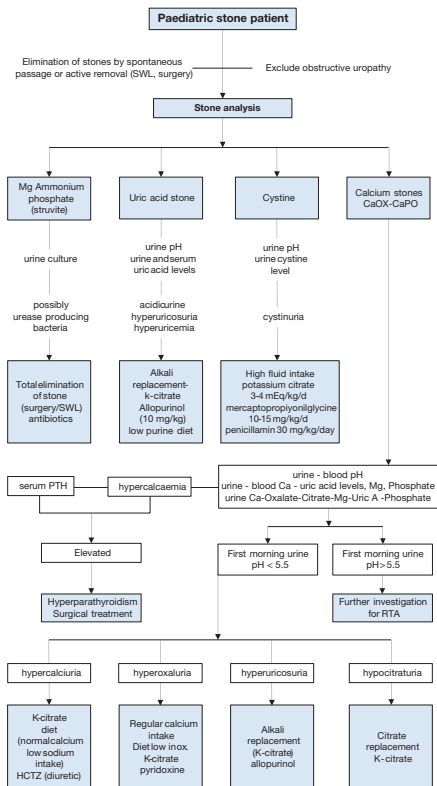
<p>Select the most appropriate management option based on:</p> <ul style="list-style-type: none"> • the presence of renal scars; • clinical course; • the grade of reflux; • ipsilateral renal function; • bilaterality; • bladder function; • associated anomalies of the urinary tract; • age and gender; • compliance; • parental preference. <p>Refer to full guideline for risk factors and follow-up.</p>	Weak
<p>In high-risk patients who already have renal impairment, a more aggressive, multidisciplinary approach is needed.</p>	Strong

URINARY STONE DISEASE

Paediatric stone disease is an important clinical problem in paediatric urology practice. Due to its recurrent nature, every effort should be made to discover the underlying metabolic abnormality so that it can be treated appropriately.

Presentation tends to be age-dependent, with symptoms such as flank pain and haematuria being more common in older children. Non-specific symptoms (e.g. irritability, vomiting) are common in very young children. Adequate fluid intake and restricting the use of salt within daily allowance range are the general recommendations besides the specific medical treatment against the detected metabolic abnormalities.

Figure 12: Algorithm for metabolic investigations in urinary stone disease in children



Ca = calcium; HCTZ = hydrochlorothiazide; Mg = magnesium; Ox = oxalate; PTH = parathyroid hormone; SWL = extracorporeal shockwave lithotripsy; RTA = renal tubular acidosis; Uric A = uric acid.

Table 2: Recommendations for interventional management in paediatric stones

Stone size and localisation*	Primary treatment option	Secondary treatment options	Comment
Staghorn stones	PCNL	Open/SWL	Multiple sessions and accesses with PCNL may be needed. Combination with SWL may be useful.
Pelvis < 10 mm	SWL	RIRS/PCNL/ MicroPerc	
Pelvis 10-20 mm	SWL	PCNL/RIRS/ MicroPerc/ Open	Multiple sessions with SWL may be needed. PCNL has similar recommendation grade.
Pelvis > 20 mm	PCNL	SWL/Open	Multiple sessions with SWL may be needed.
Lower pole calyx	PCNL	SWL/Open	Multiple sessions with SWL may be needed.
< 10 mm	SWL	RIRS/PCNL/ MicroPerc	Anatomical variations are important for complete clearance after SWL.

Lower pole calyx	SWL	RIRS/PCNL/ MicroPerc	Anatomical variations are important for complete clearance after SWL.
> 10 mm	PCNL	SWL/ MicroPerc	Anatomical variations are important for complete clearance after SWL.
Upper ureteric stones	SWL	PCNL/URS/ Open	
Upper ureteric stones	URS	SWL/Open	Additional intervention need is high with SWL.
Bladder stones	Endoscopic		Open is easier and with less operative time with large stones.
Bladder stones	Endoscopic		Open is easier and with less operative time with large stones.

* Cystine and uric acid stones excluded.

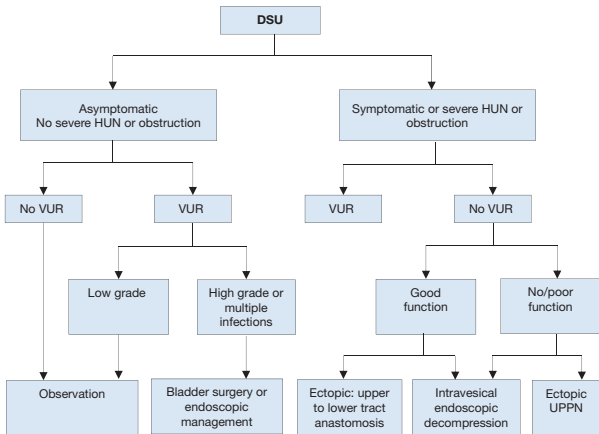
PCNL = percutaneous nephrolithostomy; SWL = shockwave lithotripsy; RIRS = retrograde intrarenal surgery; URS = ureteroscopy.

Recommendations	Strength rating
Use plain abdominal X-ray and ultrasound as the primary imaging techniques for the diagnosis and follow-up of stones.	Strong
Use low-dose non-contrast computed tomography in cases with a doubtful diagnosis, especially of ureteral stones or complex cases requiring surgery.	Strong
Perform a metabolic evaluation in any child with urinary stone disease. Any kind of interventional treatment should be supported with medical treatment for the underlying metabolic abnormality, if detected.	Strong
Limit open surgery under circumstances in which the child is very young with large stones, in association with congenital problems requiring surgical correction and/or with severe orthopaedic deformities that limit positioning for endoscopic procedures.	Strong

OBSTRUCTIVE PATHOLOGY OF RENAL DUPLICATION: URETEROCELE AND ECTOPIC URETER

Ureterocele and ectopic ureter are the two main anomalies associated with complete renal duplication. Antenatal US detects both conditions in the majority of cases if associated with obstruction, and diagnosis is confirmed after birth. Later in life, these anomalies are revealed by clinical symptoms: UTI, pain, calculus formation, disturbances of micturition, and urinary incontinence. There is a wide variation of symptoms in patients with ureterocele (from the asymptomatic patient to urosepsis, urinary retention and upper tract dilatation after birth). Ectopic ureter is less frequent than ureterocele and more common in females with some remaining asymptomatic.

Figure 13: Algorithm for the management of duplex system ureterocele after the first 3-6 months of life



DSU = duplex system ureterocele; HUN = hydroureteronephrosis; UPPN = upper pole partial nephrectomy; VUR = vesicoureteric reflux to the lower pole.

Recommendations			Strength rating
Ureterocele	Diagnosis	Use ultrasound (US), radionuclide studies (mercaptoacetyltriglycine (MAG3)/ dimercaptosuccinic acid (DMSA)), voiding cystourethrography (VCUG), magnetic resonance urography, high-resolution magnetic resonance imaging (MRI), and cystoscopy to assess function, to detect reflux and rule out ipsilateral compression of the lower pole and urethral obstruction.	Weak
	Treatment	Select treatment based on symptoms, function and reflux as well on surgical and parenteral choices: observation, endoscopic decompression, ureteral re-implantation, partial nephroureterectomy, complete primary reconstruction. Offer, early endoscopic decompression to patients with an obstructing ureterocele.	Weak

Ectopic ureter	Diagnosis	Use US, DMSA scan, VCUG or MRI for a definitive diagnosis.	Weak
	Treatment	In non-functioning moieties with recurrent infections, heminephroureterectomy is a definitive solution. Ureteral reconstruction (ureteral re-implantation/ ureteroureterostomy/ ureteropyelostomy and upper-pole ureterectomy) are other therapeutic option especially in cases in which the upper pole has function worth preserving.	Weak

DISORDERS OF SEX DEVELOPMENT

The term 'disorders of sex development' is proposed to indicate congenital conditions with atypical development of chromosomal, gonadal or anatomical sex. Dealing with neonates with DSD requires a multidisciplinary approach, which should include geneticists, neonatologists, paediatric and adult endocrinologists, gynaecologists, psychologists, ethicists and social workers with each team member specialised in DSD.

Table 3: Findings in a newborn suggesting the possibility of DSD

Apparent male
Severe hypospadias associated with bifid scrotum
Undescended testis/testes with hypospadias
Bilateral non-palpable testes in a full-term apparently male infant
Apparent female
Clitoral hypertrophy of any degree, non-palpable gonads
Vulva with single opening
Indeterminate
Ambiguous genitalia

Table 4: Diagnostic work-up of neonates with disorders of sex development

History (family, maternal, neonatal)
Parental consanguinity
Previous DSD or genital anomalies
Previous neonatal deaths
Primary amenorrhoea or infertility in other family members
Maternal exposure to androgens
Failure to thrive, vomiting, diarrhoea of the neonate
Physical examination
Pigmentation of genital and areolar area
Hypospadias or urogenital sinus
Size of phallus
Palpable and/or symmetrical gonads
Blood pressure

Investigations
Blood analysis: 17-hydroxyprogesterone, electrolytes, LH, FSH, TST, cortisol, ACTH
Urine: adrenal steroids
Karyotype
Ultrasound
Genitogram
hCG stimulation test to confirm presence of testicular tissue
Androgen-binding studies
Endoscopy

ACTH = adrenocorticotrophic hormone; FSH = follicle-stimulating hormone; hCG = human chorionic gonadotropin; LH = luteinising hormone; TST = testosterone.

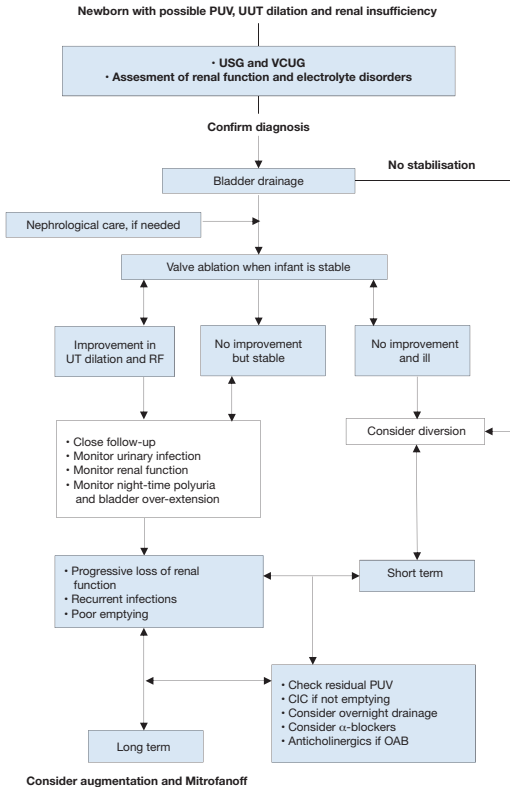
Recommendations	Strength rating
Newborns with DSD conditions warrant a multidisciplinary team approach.	Strong
Refer children to experienced centres where neonatology, paediatric endocrinology, paediatric urology, child psychology and transition to adult care are guaranteed.	Strong
Do not delay diagnosis and treatment of any neonate presenting with ambiguous genitalia since salt-loss in a 46XX CAH girl can be fatal.	Strong

CONGENITAL LOWER URINARY TRACT OBSTRUCTION (CLUTO)

The term congenital lower urinary tract obstruction (CLUTO) is used for a foetus, which during intrauterine US screening shows a dilatation of the upper and lower urinary tract. During pregnancy the diagnosis is usually based on US examinations

only. There is a broad spectrum of conditions causing such a condition. Postpartum diagnosis comprises any anatomical and functional disorder, anomaly, and malformation causing a dilatation such as posterior and anterior urethral valves, urethral atresia, dysplasia and stenosis, Prune Belly syndrome, and dilating reflux. Moreover cloacal malformation, ureterocele, a Megacystis-Microcolon-intestinal hypoperistalsis or Megacystis-Megaureter syndrome belong to the CLUTO spectrum as well.

Figure 14: Algorithm the assessment, management and follow-up of newborns with possible PUV



CIC = clean intermittent catheterisation; OAB = overactive bladder; PUV = posterior urethral valve; RF = renal function; UT = urinary tract; UUT = upper urinary tract; VCUG = voiding cystourethrogram.

Recommendations	Strength rating
Diagnose posterior urethral valves (PUV) initially by ultrasound but a voiding cystourethrogram (VCUG) is required to confirm the diagnosis.	Strong
Assess split renal function by dimercaptosuccinic acid scan or mercaptoacetyltriglycine (MAG3) clearance. Use serum creatinine as a prognostic marker.	Strong
Vesico-amniotic shunt antenatally is not recommended to improve renal outcome.	Weak
Offer endoscopic valve ablation after bladder drainage and stabilisation of the child.	Strong
Offer suprapubic diversion for bladder drainage if the child is too small for valve ablation.	Strong
Offer a high urinary diversion if bladder drainage is insufficient to drain the upper urinary tract and the child remains unstable.	Strong
Monitor bladder and renal function lifelong, in all patients.	Strong

RARE CONDITIONS:

Urachal remnants

Urachal remnants originate from failure of the obliteration of the allantois, resulting in a urachal anomaly such as urachal sinus, urachal cyst, vesico-urachal diverticulum, and patent urachus, respectively. Most often the urachal anomaly is asymptomatic, but it occasionally may become infected, may cause urinary symptoms, or may develop a urachal carcinoma in later life.

Recommendations	Strength rating
Urachal remnants with no epithelial tissue carry little risk of malignant transformation.	Strong
Asymptomatic and non-specific atretic urachal remnants can safely be managed non-operatively.	Strong
Urachal remnants incidentally identified during diagnostic imaging for non-specific symptoms should also be observed non-operatively since they tend to resolve spontaneously.	Strong
A small urachal remnant, especially at birth, may be viewed as physiological.	Strong
Urachal remnants in patients younger than six months are likely to resolve with non-operative management.	Strong
Follow-up is necessary only when symptomatic for six to twelve months.	Strong
Surgical excision of urachal remnants solely as a preventive measure against later malignancy appears to have minimal support in the literature.	Strong
Only symptomatic urachal remnants should be safely removed by open or laparoscopic approach.	Strong
A VCUG is only recommended when presenting with febrile urinary tract infections.	Strong

Papillary tumours of the bladder

Papillary tumours of the bladder in children and adolescents are extremely rare and are different from papillary tumours in adults.

Recommendations	Strength rating
Ultrasound is the first investigation of choice for the diagnosis of paediatric bladder tumours.	Strong
Cystoscopy should be reserved if a bladder tumor is suspected on imaging for diagnosis and treatment.	Strong
After histological confirmation, inflammatory myofibroblastic bladder tumours should be resected locally.	Weak
Follow-up should be every 3-6 months in the first year, and thereafter at least annually with urinalysis and an ultrasound for at least 5 years.	Weak

Penile lesions

Paediatric lesions of the penis are uncommon but an important part of the paediatric urological practice. The commonest of these lesions are cystic penile lesions followed by vascular malformations and neurogenic lesions. Soft tissue tumours of the male external genitalia are uncommon, but have been described in the paediatric age group and can be malignant.

Recommendations	Strength rating
Treatment of penile cystic lesions is by total surgical excision, it is mainly indicated for cosmetic or symptomatic (e.g. infection) reasons.	Weak
Propranolol is currently first-line treatment for infantile haemangiomas.	Strong

Penile lymphedema

Paediatric lymphedema is usually primary and generally very rare. Inefficient lymphatic drainage leads to accumulation of subcutaneous lymph causing tissue swelling and inflammation and subsequently stimulates adipose deposition and fibrosis further exacerbating enlargement. With time the edematous tissue becomes vulnerable to infection, chronic cutaneous changes and disfigurement. Complications may ensue such as phimosis, haematuria, bleeding, bladder outlet obstruction, pain, dysuria, lymphorrhea and severe psychological distress due to resultant deformity.

Recommendations	Strength rating
Conservative management is the first-line treatment for penile lymphedema.	Weak
In symptomatic cases or in patients with functional impairment, surgical intervention may become necessary for penile lymphedema.	Weak

PAEDIATRIC UROLOGICAL TRAUMA

In about 3% of children seen at paediatric hospital trauma centres, there is significant involvement of the genitourinary tract. This is caused by either blunt injuries from falls, car accidents, sports injuries, physical assault, and sexual abuse, or penetrating injuries, usually due to falls onto sharp objects or from gunshot or knife wounds.

Paediatric renal trauma

Table 5: Renal injury classified according to the kidney injury scale of the American Association for the Surgery of Trauma

Grade	Type of injury	Description
I	Contusion	Non-visible or visible haematuria
	Haematoma	Normal urological studies
II	Haematoma	Non-expanding subcapsular haematoma
	Laceration	Laceration of the cortex of < 1.0 cm
III	Laceration	Laceration > 1.0 cm without rupture of collecting system
IV	Laceration	Through the cortex, medulla and collecting system
	Vascular	Vascular injury
V	Laceration	Completely shattered kidney
	Vascular	Avulsion of the renal hilum

Recommendations	Strength rating
Use imaging in all children who have sustained a blunt or penetrating trauma with any level of haematuria, especially when the history reveals a deceleration trauma, direct flank trauma or a fall from a height.	Strong
Use rapid spiral computed tomography with delayed images scanning for diagnostic and staging purposes.	Strong
Manage most injured kidneys conservatively.	Strong
Offer surgical intervention in case of haemodynamic instability and a Grade V renal injury.	Strong

Paediatric ureteral trauma

Recommendations	Strength rating
Diagnose suspected ureteral injuries by retrograde pyelogram.	Strong
Manage ureteral injuries endoscopically, using internal stenting or drainage of an urinoma, either percutaneously or via a nephrostomy tube.	Weak

Paediatric bladder injuries

Recommendations	Strength rating
Use retrograde cystography to diagnose suspected bladder injuries.	Strong
Ensure that the bladder has been filled to its full capacity and an additional film is taken after drainage.	Strong
Manage extra-peritoneal bladder ruptures conservatively with a transurethral catheter left in place for seven to ten days.	Strong
Do not delay treatment of intra-peritoneal bladder ruptures by surgical exploration and repair as well as post-operative drainage for seven to ten days.	Strong

Paediatric urethral injuries

Recommendations	Strength rating
Assess the urethra by retrograde urethrogram in case of suspected urethral trauma.	Strong

Perform a rectal examination to determine the position of the prostate.	Strong
Manage bulbous urethral injuries conservatively with a transurethral catheter.	Strong
Manage posterior urethral disruption by either: <ul style="list-style-type: none"> • primary reconstruction; • primary drainage with a suprapubic catheter alone and delayed repair; • primary re-alignment with a transurethral catheter. 	Weak

PERI-OPERATIVE FLUID MANAGEMENT

Children have a different total body fluid distribution, renal physiology and electrolyte requirements, as well as weaker cardiovascular compensation mechanisms, compared to adults. Therefore special child specific requirements regarding preoperative fasting and intra- as well as post-operative fluid have to be considered and close monitoring is essential. This is especially true for interventions relieving any kind of obstruction as this may result in substantial polyuria.

Table 6: Pre-operative fasting times for elective surgery

Ingested material	Minimum fasting period (hours)
Clear liquids	1
Breast milk	4
Light meal	6

Table 7: Intra-operative fluid management

	Solution for infusion	Initial/repeated dose
Background infusion	Balanced isotonic solution + 1-2% glucose	10mL/kg/h
Fluid therapy	Balanced isotonic solution	X 10-20 mL/kg
Volume therapy	Albumin, Gelatine, HES	X 5-10 mL/kg
Transfusion	Red blood cells, fresh frozen plasma, platelets	X 10 mL/kg

Recommendations	Strength rating
Ensure shorter pre-operative fasting periods for elective surgeries (up to one hour for clear liquids).	Strong
Use ERAS protocols for abdominal surgery in children with normal bowel movement.	Strong
Use isotonic solutions in hospitalised children because they are at high risk of developing hyponatraemia.	Strong
Assess the baseline and daily levels of serum electrolytes, glucose, urea and/or creatinine in every child who receives intravenous fluids, especially in intestinal surgery (e.g. ileal augmentation), regardless of the type of solution chosen since there is an increased risk of electrolyte abnormalities in children undergoing such surgery.	Strong
Start early oral fluid intake in all patients scheduled for minor surgical procedures.	Strong

POST-OPERATIVE PAIN MANAGEMENT

The provision of adequate pain control requires proper pain evaluation, accurate choice of drug and route of administration, and consideration of age, physical condition and type of surgery and anaesthesia.

A proposed strategy for post-operative analgesia may be as follows:

1. Intra-operative regional or caudal block.
2. Paracetamol + NSAID.
3. Paracetamol + NSAID + weak opioid (e.g. tramadol or codeine).
4. Paracetamol + NSAID + strong opioid (e.g. morphine, fentanyl, oxycodone or pethidine).

Recommendations	Strength rating
Prevent/treat pain in children of all ages.	Strong
Evaluate pain using age-compatible assessment tools.	Strong
Inform patients and caregivers accurately.	Strong
Use pre-emptive and balanced analgesia in order to decrease the side effects of opioids.	Strong

BASIC PRINCIPLES OF LAPAROSCOPIC SURGERY IN CHILDREN

Laparoscopy in children requires specific anaesthetic precautions. Physiological effects of CO₂ pneumoperitoneum, positioning of the patient and operative time need to be considered by the anaesthesiology team.

Recommendations	Strength rating
Use lower intra-abdominal pressure (6-8 mmHg) during laparoscopic surgery in infants and smaller children.	Strong
Use open access for laparoscopy in infants and smaller children.	Strong
Monitor for laparoscopy-related cardiac, pulmonary and diuretic responses.	Strong

This short booklet text is based on the more comprehensive EAU Paediatric Urology Guidelines (978-94-92671-13-4), available at their website, <http://www.uroweb.org/guidelines>.