EAU Guidelines on Urethral Strictures

N. Lumen (Chair), F. Campos-Juanatey,
K. Dimitropoulos, T. Greenwell, F.E. Martins, N. Osman,
A. Ploumidis, S. Riechardt, M. Waterloos
Guidelines Associates: R. Barratt, G. Chan,
F. Esperto, W. Verla
Guidelines Office: R. Shepherd

© European Association of Urology 2025

European Association of Urology

TABLE OF CONTENTS PAGE

1. INTRODUCTION 7
   1.1 Aims and scope 7
   1.2 Panel composition 7
   1.3 Available publications 7
   1.4 Publication history 7
   1.5 Summary of changes 7

2. METHODOLOGY 7
   2.1 Methods 7
   2.2 Review 8

3. DEFINITION, EPIDEMIOLOGY, AETIOLOGY AND PREVENTION 8
   3.1 Definitions 8
   3.2 Epidemiology 9
   3.3 Aetiology and prevention 9
      3.3.1 Aetiology and prevention in males 9
      3.3.2 Aetiology in females 14

4. CLASSIFICATIONS 14
   4.1 According to stricture location 14
      4.1.1 In males 14
         4.1.1.1 Anterior urethra 14
         4.1.1.2 Posterior urethra 14
      4.1.2 In females 15
   4.2 According to stricture tightness 15
   4.3 Strictures in transgender men and woman 15
      4.3.1 Trans women 15
      4.3.2 Trans men 15

5. DIAGNOSTIC EVALUATION 15
   5.1 Patient history 15
   5.2 Physical examination 16
      5.2.1 Further diagnostic evaluation 16
         5.2.1.1 Patient reported outcome measure (PROM) 16
         5.2.1.2 Urinalysis and urine culture 17
         5.2.1.3 Uroflowmetry and post-void residual estimation 17
         5.2.1.4 Urethrography 17
         5.2.1.5 Cystourethroscopy 18
         5.2.1.6 Ultrasound 18
         5.2.1.7 Magnetic resonance imaging 19

6. DISEASE MANAGEMENT IN MALES 21
   6.1 Conservative options 21
      6.1.1 Observation 21
      6.1.2 Suprapubic catheter 22
   6.2 Endoluminal treatment of anterior urethral strictures in males 22
      6.2.1 Direct vision internal urethrotomy 22
         6.2.1.1 Indications of “cold knife” direct vision internal urethrotomy 23
            6.2.1.1.1 Direct vision internal urethrotomy for primary stricture treatment 23
            6.2.1.1.2 Direct vision internal urethrotomy for recurrent strictures and as salvage treatment after failed urethroplasty 24
            6.2.1.1.3 Predictors of failure of “cold knife” direct vision internal urethrotomy 24
         6.2.1.2 Indications of “hot-knife” direct vision internal urethrotomy 25
            6.2.1.2.1 Laser urethrotomy 25
            6.2.1.2.2 Plasmakinetic (bipolar) urethrotomy 26

6.2.1.3 Complications of direct vision internal urethrotomy 26
6.2.1.3.1 Complications of “cold knife” direct vision internal urethrotomy 26
6.2.1.3.2 Complications of “hot knife” direct vision internal urethrotomy 26
6.2.1.3.3 Complications of “cold knife” vs. “hot knife” direct vision internal urethrotomy 26
6.2.1.3.4 Complications of direct vision internal urethrotomy vs. dilatation 27
6.2.1.3.5 Complications of “cold knife” direct vision internal urethrotomy vs. urethroplasty 27
6.2.2 Single dilatation 28
6.2.2.1 Modalities of dilatation and results 28
6.2.2.2 Effectiveness of dilatation compared with direct vision internal urethrotomy 28
6.2.3 Post-dilatation/direct vision internal urethrotomy strategies 29
6.2.3.1 Intermittent self-dilatation 29
6.2.3.1.1 Results 29
6.2.3.1.2 Complications 29
6.2.3.1.3 Intermittent self-dilatation combined with intra-urethral corticosteroids 29
6.2.3.2 Intralesional injections 30
6.2.3.2.1 Steroids 30
6.2.3.2.2 Mitomycin C 30
6.2.3.2.3 Platelet rich plasma 31
6.2.3.3 Urethral stents 31
6.2.3.3.1 Results 31
6.2.3.4 Drug-coated balloon dilatation 31
6.2.3.4.1 Treatment of stent failure 32
6.3 Open repairs (urethroplasty): site and aetiology (clinical scenario) treatment options 34
6.3.1 The role of urethroplasty in the management of penile urethral strictures 34
6.3.1.1 Staged augmentation urethroplasty 34
6.3.1.2 Single-stage augmentation urethroplasty 34
6.3.1.3 Anastomotic urethroplasty in men with penile urethral strictures 35
6.3.1.4 Specific considerations for failed hypospadias repair-related strictures 35
6.3.1.5 Specific considerations for lichen sclerosus-related penile urethral strictures 37
6.3.1.6 Distal urethral strictures (meatal stenosis, fossa navicularis strictures) 37
6.3.2 Urethroplasty for bulbar strictures 38
6.3.2.1 “Short” bulbar strictures 38
6.3.2.1.1 Excision and primary anastomosis 38
6.3.2.1.1.1 Excision and primary anastomosis with transection of corpus spongiosum (transecting EPA) 38
6.3.2.1.1.1.1 Patency rates 38
6.3.2.1.1.1.2 Complications 38
6.3.2.1.1.2 Non-transecting excision and primary anastomosis 39
6.3.2.1.1.2.1 Patency rates 39
6.3.2.1.1.2.2 Complications 39
6.3.2.1.2 Free graft urethroplasty 39
6.3.2.2 “Longer” bulbar strictures 40
6.3.2.2.1 Free graft urethroplasty 40
6.3.2.2.2 Augmented anastomotic repair 40
6.3.2.2.3 Location of the graft during urethroplasty for bulbar strictures 40
6.3.2.3 Staged urethroplasty for bulbar urethral strictures 41
6.3.2.3.1 Indications 41
6.3.2.3.2 Outcomes 41

6.3.2.3.3 Risk factors 42
6.3.2.3.4 Risk factors for adverse outcomes 42
6.3.2.4 Management of recurrence after bulbar urethroplasty 43
6.3.3 Urethroplasty for penobulbar or panurethral strictures 43
6.3.4 Perineal urethrostomy 44
6.3.4.1 Indications 44
6.3.4.2 Types of perineal urethrostomy 44
6.3.4.3 Outcomes 45
6.3.4.3.1 Patency rates 45
6.3.4.3.2 Complications 45
6.3.4.3.3 Patient reported outcomes 45
6.3.4.3.4 Risk factors for patency failure of the perineal urethrostomy 46
6.3.5 Posterior urethra 46
6.3.5.1 Non-traumatic posterior urethral stenosis 46
6.3.5.1.1 Treatment of non-traumatic posterior urethral stenosis 46
6.3.5.1.2 Endoluminal management of non-traumatic posterior urethral stenosis 46
6.3.5.1.2.1 Dilatation of non-traumatic posterior urethral stenosis 46
6.3.5.1.2.2 Endoscopic incision/resection of non-traumatic posterior urethral stenosis (Table 6.8) 46
6.3.5.1.2.3 Post-dilatation/direct vision internal urethrotomy strategies for non-traumatic posterior urethral Stenosis 48
6.3.5.1.2.3.1 Intermittent self-dilatation for non-traumatic posterior urethral stenosis 48
6.3.5.1.2.3.2 Intralesional injections for non-traumatic posterior urethral stenosis 48
6.3.5.1.2.3.3 Urethral stent for non-traumatic posterior urethral stenosis 49
6.3.5.1.3 Lower urinary tract reconstruction for non-traumatic posterior urethral stenosis 49
6.3.5.1.3.1 Redo vesico-urethral anastomosis for vesico-urethral anastomotic stenosis after radical prostatectomy 50
6.3.5.1.3.2 Posterior stenosis after surgery for benign prostatic obstruction 52
6.3.5.1.3.2.1 Bladder neck reconstruction for bladder neck stenosis after surgery for benign prostatic obstruction 52
6.3.5.1.3.2.2 Bulbomembranous strictures after surgery for benign prostatic obstruction 52
6.3.5.1.3.3 Radiation/high-energy induced posterior strictures 52
6.3.5.1.3.3.1 Bulbomembranous strictures secondary to radiation/high energy sources 52
6.3.5.1.3.3.2 Prostatic strictures secondary to radiation/high energy sources 53
6.3.5.1.4 Extirpative surgery and urinary diversion for non-traumatic posterior urethral stenosis 53
6.3.5.2 Post-traumatic posterior stenosis 54

6.3.5.2.1 Endoluminal treatment for post-traumatic posterior stenosis 54
6.3.5.2.1.1 Endoluminal treatment as primary treatment for post-traumatic posterior stenosis 54
6.3.5.2.1.2 Endoluminal treatment after failed urethroplasty for post-traumatic posterior stenosis 54
6.3.5.2.2 Urethroplasty for post-traumatic posterior stenosis 55
6.3.5.2.2.1 First urethroplasty for post-traumatic posterior stenosis 55
6.3.5.2.2.1.1 Indication and technique of urethroplasty for post-traumatic posterior stenosis 55
6.3.5.2.2.1.2 Patency rate after urethroplasty for post-traumatic posterior stenosis 55
6.3.5.2.2.1.3 Sexual function, urinary continence, and rectal injury after urethroplasty for post-traumatic posterior stenosis 56
6.3.5.2.2.2 ReDo-urethroplasty for post-traumatic posterior stenosis 56

7. DISEASE MANAGEMENT IN FEMALES 58
7.1 Signs and symptoms of female urethral strictures 58
7.2 Diagnosis of female urethral strictures 58
7.3 Treatment of female urethral strictures 58
7.3.1 Minimally invasive techniques for treatment of female urethral strictures 58
7.3.1.1 Urethrotomy for treatment of female urethral strictures 58
7.3.1.2 Urethral dilatation for treatment of female urethral strictures 59
7.3.1.3 Meatoplasty for treatment of female urethral strictures 59
7.3.2 Urethroplasty for treatment of female urethral strictures 59
7.3.2.1 Vaginal graft augmentation urethroplasty for treatment of female urethral strictures 59
7.3.2.2 Vaginal flap augmentation urethroplasty for treatment of female urethral strictures 59
7.3.2.3 Labial/vestibular graft augmentation urethroplasty for treatment of female urethral strictures 60
7.3.2.4 Labial/vestibular flap urethroplasty for treatment of female urethral strictures 60
7.3.2.5 Buccal and lingual mucosal graft augmentation urethroplasty for treatment of female urethral strictures 60
7.3.2.6 Anastomotic urethroplasty 60

8. DISEASE MANAGEMENT IN TRANSGENDER PATIENTS 63
8.1 Treatment of strictures in trans men 63
8.1.1 Management of strictures early after neophallic reconstruction 63
8.1.2 Treatment of meatal stenosis in trans men 63
8.1.3 Treatment of strictures at the neophallic urethra 63
8.1.4 Treatment of strictures at the anastomosis neophallic urethra-fixed part of the urethra 63
8.1.5 Treatment of strictures at the fixed part of the urethra 63
8.1.6 Definitive perineostomy in trans men 63
8.2 Peri-operative care after treatment of strictures in trans men 64
8.3 Strictures in trans women 64

9. TISSUE TRANSFER 64
9.1 Comparison of grafts with flaps 64
9.2 Comparison of different types of flaps 65
9.3 Comparison of different types of grafts 66
9.4 Tissue engineered grafts 67
9.4.1 Cell-free tissue engineered grafts 67
9.4.2 Autologous tissue engineered oral mucosa graftss 68
9.5 Management of oral cavity after buccal mucosa harvesting 68

10. PERI-OPERATIVE CARE OF URETHRAL SURGERY 69
10.1 Urethral rest 69
10.2 Antibiotics 69
10.3 Catheter management 70

11. FOLLOW-UP 71
11.1 Rationale for follow-up after urethral surgery 71
11.2 Definition of success after urethroplasty surgery 71
11.3 Follow-up tools after urethral surgery 72
11.3.1 Diagnostic tools for follow-up after urethral surgery 72
11.3.1.1 Calibration during follow-up after urethral surgery 72
11.3.1.2 Urethrocystoscopy during follow-up after urethral surgery 73
11.3.1.3 Retrograde urethrogram and voiding cystourethrogram during follow-up after urethral surgery 73
11.3.1.4 Urethral ultrasound – Sonourethrography during follow-up after urethral surgery 73
11.3.2 Screening tools for follow-up after urethral surgery 73
11.3.2.1 Flow-rate analysis during follow-up after urethral surgery 73
11.3.2.2 Post-void residual ultrasound measure during follow-up after urethral surgery 73
11.3.2.3 Symptom questionnaires during follow-up after urethral surgery 73
11.3.3 Quality of life assessment, including disease specific questionnaires during follow-up after urethral surgery 74
11.4 Ideal follow-up interval after urethral surgery 75
11.5 Length of follow-up after urethral surgery 75
11.6 Risk-stratified proposals during follow-up after urethral surgery 75
11.7 Follow-up protocol proposal after urethroplasty 76
11.7.1 Surgeries with low risk of recurrence 76
11.7.2 Surgical management options with standard risk of recurrence 76

12. REFERENCES 78

13. CONFLICT OF INTEREST 108

14. COPYRIGHT AND TERMS OF USE 109

1. INTRODUCTION

1.1 Aims and scope

The European Association of Urology (EAU) Urethral Strictures Guidelines aim to provide a comprehensive overview of urethral strictures in male, female, and transgender patients. The Panel is aware of the geographical variations in healthcare provision.

It must be emphasised that guidelines present the best evidence available to the experts; however, following guideline recommendations will not necessarily result in the best outcome. Guidelines can never replace clinical expertise when making treatment decisions for individual patients, but rather help to focus decisions - also taking personal values and preferences/individual circumstances of patients into account. Guidelines are not mandates and do not purport to be a legal standard of care.

1.2 Panel composition

The EAU Urethral Strictures Guidelines panel consists of an international multidisciplinary group of clinicians with particular expertise in this area. All experts involved in the production of this document have submitted potential conflict of interest statements which can be viewed on the EAU website: https://uroweb.org/guidelines/urethral-strictures. A EAU Guidelines App for iOS and Android devices is also available containing the Pocket Guidelines, interactive algorithms and calculators, clinical decision support tools, guidelines cheat sheets and links to the extended guidelines.

1.3 Available publications

Alongside the full text version, a quick reference document (Pocket Guidelines) is available in print. This is an abridged version which may require consultation together with the full text version. All documents can be viewed through the EAU website: https://uroweb.org/guidelines/urethral-strictures. A list of supplementary tables supporting this text can also be found online, along with an appendix of abbreviations specific to this text: https://uroweb.org/guidelines/urethral-strictures/publications-appendices.

A EAU Guidelines App for iOS and Android devices is also available containing the Pocket Guidelines, interactive algorithms and calculators, clinical decision support tools, guidelines cheat sheets and links to the extended guidelines.

1.4 Publication history

This Guideline was first published in 2021. Additional information can be found in the general Methodology section of this print, and online at the EAU website: http://www.uroweb.org/guidelines/. A list of associations endorsing the EAU Guidelines can also be viewed online at the above address.

1.5 Summary of Changes

This guideline represents a partial update of the 2022 text. References have been updated and now refer the reader to the final versions of the Panel's summary and systematic review papers. Minor grammatical and formatting issues have also been addressed.

2. METHODOLOGY

2.1 Methods

For the 2023 Urethral Strictures Guidelines, new and relevant evidence was identified, collated, and appraised through a structured assessment of the literature. A broad and comprehensive literature search, covering all sections of the Guidelines was performed. Databases searched included Medline, EMBASE, and the Cochrane Libraries, covering a time frame between 2019 and 2022 and restricted to English language publications. The panel defined by consensus inclusion and exclusion criteria for each topic before the scope search. Detailed search strategies are available online: https://uroweb.org/guideline/urethral-strictures/.

Recommendation within the Guidelines are developed by the panels to prioritise clinically important care decisions. The strength of each recommendation is determined by the balance between desirable and undesirable consequences of alternative management strategies, the quality of the evidence (including certainty of estimates), and the nature and variability of patient values and preferences [1, 2]. This decision process, which can be reviewed in the strength rating forms which accompany each guideline statement, addresses a number of key elements:

1. the overall quality of the evidence which exists for the recommendation [3];
2. the magnitude of the effect (individual or combined effects);
3. the certainty of the results (precision, consistency, heterogeneity and other statistical or study related factors);
4. the balance between desirable and undesirable outcomes;
5. the impact of patient values and preferences on the intervention.

Strong recommendations typically indicate a high degree of evidence quality and/or a favourable balance of benefit to harm and patient preference. Weak recommendations typically indicate availability of lower quality evidence, and/or equivocal balance between benefit and harm, and uncertainty or variability of patient preference [4].

The Panel wants to highlight that "success" in urethral stricture treatment is poorly defined and subjective. "Success" is usually defined as urethral patency, either subjective by the absence of voiding symptoms or objective by imaging or urethral calibration. Despite urethral patency, the patient themselves might not consider the treatment as successful because of functional consequences (e.g., post-void dribbling, erectile/ejaculatory dysfunction, altered genital appearance). In this Guideline, the Panel agreed to avoid the term "success". Instead, the term "patency rate" or "stricture recurrence rate" will be used to clarify that only stricture recurrence was taken into consideration (as assessed by the authors).

The Panel would like to stress that patency after urethral surgery is dependent on the general principles of wound healing. These principles have stood the test of time and need to be respected [5]. Some examples:

- An anastomosis should be made between healthy urethral ends and without any tension.
- A graft requires a well-vascularised graft bed with a close contact between the graft and graft bed to promote imbibition and inosculation.
- If the full circumference of the urethral mucosa is destroyed, spontaneous regeneration will not take place.
- Contraction and fibrosis in a wound only stops after it is covered by its epithelium.

The Panel conducted two systematic reviews (SR) to support guideline recommendations, which were published in 2021:

- What is the role of single-stage oral mucosa graft urethroplasty in the surgical management of Lichen Sclerosus-related stricture disease in men? A systematic review [6];
- Free Graft Augmentation Urethroplasty for Bulbar Urethral Strictures: Which Technique Is Best? A Systematic Review [7].

The results of these reviews are included in the 2023 Urethral Stricture Guidelines.

In addition, the panel drafted three summary papers of the guidelines which were published in European Urology and European Urology Focus:

- EAU guidelines on urethral stricture disease (part 1): management of male urethral stricture disease [8];
- EAU Guidelines on urethral stricture disease (part 2): diagnosis, perioperative management, and follow-up in males [9];
- EAU guidelines on urethral stricture disease (part 3): management of strictures in females and transgender patients [10].

2.2 Review

The Urethral Strictures Guidelines were peer reviewed prior to initial publication in 2021.

3. DEFINITION, EPIDEMIOLOGY, AETIOLOGY AND PREVENTION

3.1 Definitions

In males, a urethral stricture refers to a narrowed segment of the anterior urethra due to a process of fibrosis and cicatrisation of the urethral mucosa and surrounding spongiosus tissue ("spongiofibrosis") [11, 12]. In the male posterior urethra, there is no spongiosus tissue and at this location the terms stenosis is preferred [11, 12]. The definition of meatal stenosis is generally accepted as a short distal narrowing at the meatus, without involvement of the fossa navicularis [12].

There is no universal definition for what constitutes a female urethral stricture (FUS). Female urethral stricture is defined by most authors as a 'fixed anatomical narrowing' causing reduced urethral calibre [13, 14]. This reduced urethral calibre is variously defined as between < 10 Fr to < 20 Fr [15, 16] with the majority of series defining < 14 Fr as diagnostic, compared with a 'normal' urethral calibre of 18-30 Fr.

In transgender patients, the term stricture is also used to define a narrowing of the reconstructed urethra despite the absence of surrounding spongious tissue.

3.2 Epidemiology

In males, a sharp increase in incidence is observed after the age of 55 years, with a mean age of 45.1 [17, 18]. Overall, the incidence is estimated to be 229-627 per 100,000 males [17]. The anterior urethra is most frequently affected (92.2%), in particular the bulbar urethra (46.9%) [18].

In females, 2-29% of patients presenting with refractory lower urinary tract symptoms (LUTS) have bladder outflow obstruction (BOO) [19-22] of whom 4-20% will have a urethral stricture [21-23]. True FUS therefore occurs in 0.08-5.4% of women with refractory LUTS. There is a markedly increased incidence in women over 64 years of age [24].

After hypospadias repair, meatal stenosis and urethral strictures are reported in 1.3-20% of cases, depending on the severity of the hypospadias and the technique used [25]. There is a significantly higher incidence of this type of strictures in well-resourced countries due to a higher surgical repair rate [26].

Up to 18% of all urethral strictures have been reported to involve the meatus or fossa navicularis, usually due to failed hypospadias repair (FHR), lichen sclerosus (LS), trauma/instrumentation or idiopathic causes [27-30]. Meatal stenosis post-circumcision has been reported in less than 0.2% of children undergoing circumcision as neonates [17].

In female-to-male (FtM) transgender patients ("transmen"), 2-56% will suffer a urethral stricture. Strictures almost exclusively arise at the neomeatus in male-to-female (MtF) transgender patients ("transwomen") and occur in 4-40% of cases [31].

3.3 Aetiology and prevention

Stricture aetiology differs significantly throughout different regions in the world, due to differences in healthcare quality and environmental and practice patterns [26]. Regardless of geography, urethral stricture disease adversely impacts physical health and quality of life (QoL) [32, 33], notwithstanding costs associated with the treatment of primary and recurrent disease [34, 35]. The rationale for preventing urethral strictures is to avoid morbidity to the individual and costs to society. Prevention of urethral strictures encompasses reducing the causes of stricture (e.g., infection, trauma, iatrogenic injury) and where this is not possible, mitigating the risk.

3.3.1 Aetiology and prevention in males

a. Sexually transmitted infection

Urethritis due to sexually transmitted infection (STI), in particular gonorrhoea, was previously a major cause of urethral strictures in well-resourced countries accounting for 40% of all cases [36]. The wide-scale promotion of safe sexual practices and easier access to sexual health services, resulting in timely treatment with antimicrobials, is thought to have led to the considerable reduction in the problem [36]. Infective urethritis now accounts for 0.9% to 4.6% of cases in contemporary series from well-resourced countries [36, 37] but continues to be the major cause of strictures in low-resourced countries comprising 41.6% of all strictures [38].

Summary of evidence	LE
Access to investigation and treatment of STI is associated with a temporal decline in the incidence of infective urethritis-related strictures.	3

Recommendation	Strength rating
Advise safe sexual practices, recognise symptoms of sexually transmitted infection, and provide access to prompt investigation and treatment for men with urethritis.	Strong

b. Inflammation

Lichen sclerosus involves the urethra in 20% of cases [39] and is the most common cause of panurethral stricture disease (48.6%) [18]. The aetiology of LS has not been fully elucidated but is thought to have an autoimmune origin [40]. Lichen sclerosus may be associated with environmental factors and non-autoimmune comorbidities. Uncircumcised men are far more likely to suffer LS than circumcised men (age-adjusted odds ratio [OR] of 53.55; 95% confidence interval [CI]: 7.24-395.88) [41]. Lichen sclerosus is also associated with higher mean body mass index (BMI), diabetes mellitus, coronary artery disease, tobacco usage, hyperlipidaemia, and hypertension [42-44].

c. External urethral trauma

External trauma to the urethra is the second most common cause of stricture formation in adults [36]. The urethra is vulnerable to trauma during certain activities including sport, driving a vehicle, sexual intercourse and during combat. The bulbar urethra is the site most frequently affected by blunt trauma [12], usually as a result of straddle injuries or kicks to the perineum. Penile fracture is associated with a urethral injury in 15% of cases [45]. Motor vehicle accidents are the main cause of blunt injuries to the posterior urethra associated with pelvic fractures [46]. Penetrating injuries of the urethra are uncommon during non-combat situations [47].

d. Iatrogenic urethral injury

Iatrogenic injury to the urethra is one of the most common causes of strictures in well-resourced countries [18, 36] accounting for 32-79% of all strictures [36, 48]. Preventing iatrogenic urethral injury represents the main way in which urologists can prevent urethral strictures. Iatrogenic urethral injury most commonly results from urethral instrumentation (e.g., catheterisation, cystoscopy), surgery for benign prostatic obstruction (BPO), surgery for prostate cancer, or radiotherapy [37].

d.1 Urethral catheterisation

Urethral strictures are a recognised complication of urethral catheterisation accounting for 11.2-16.3% of all strictures [18, 36]. In a meta-analysis by Hollingsworth *et al.*, the pooled percentage of patients who developed urethral stricture or erosion after short-term catheterisation (< 3 weeks) in higher-quality studies was 3.4% (CI: 1-7%) [49]. In studies comprised mainly of men with spinal cord injury with indwelling urethral catheters, the pooled estimate of urethral stricture or erosion was 8.7% (CI: 0.0-18.7%) [49].

Urethral strictures following catheterisation may arise as a consequence of injury during attempts at insertion or during the period a catheter remains *in situ*. During insertion, the urethra may be injured by formation of a false passage by the catheter tip (29.7%) or inflation of the balloon within its lumen (70.3%) [50]. The rate of urethral injuries due to catheterisation was found to be 3.2 per 1,000 inpatients [51]. A six-month prospective multicentre study found that of 37 patients with catheter-related urethral trauma referred to urologists, 24% continued to perform ISD once weekly and 11% required at least one urethral dilation for urethral stricture [52]. In another follow-up study of 37 patients with catheter-related urethral trauma, 78% of patients developed urethral stricture [50]. The most common locations of trauma are the bulbar and posterior urethra [53].

Catheter-related trauma can be prevented through several measures [54]. Studies have indicated around 25% of all indwelling catheterisations in hospitals were unnecessary and inappropriate [55, 56]. Implementation of guidelines [57, 58] and specific criteria [59] have been shown to reduce catheterisation rates. Several studies have identified deficits in the knowledge of urethral catheterisation amongst resident doctors [60, 61]. This is postulated to be a factor in catheter-related trauma [61]. A targeted training program on urethral catheterisation for nursing staff was shown to be effective in reducing iatrogenic urethral injuries in a prospective single institution study [62].

In addition to guidance and education, another approach to safer catheterisation is modification of the standard Foley catheter. A novel catheter balloon pressure valve safety system was developed to prevent balloon inflation injury though this has not been assessed in comparative studies [63, 64]. Bugeja *et al.*, studied the use of urethral catheterisation device (UCD) incorporating a guidewire, in prospective observational cohort study that included 174 patients. The incidence of adverse events was 7% with standard Foley catheterisation vs. 0% with the UCD (no statistical analysis was performed) [65]. A further prospective observational study found that Seldinger technique catheterisation could be used successfully by non-urology trained doctors [66]. These technologies need to be further assessed in prospective raondomised controlled trials (RCTs), incorporating cost-benefit analysis.

Catheter diameter is suggested as a possible contributing factor to urethral stricture due to a pressure effect on the urethral wall [67]. Decreasing the catheter size from 22 Fr to 18 Fr significantly decreased the risk of

fossa navicularis strictures (6.9% vs. 0.9%, p=0.02) after radical prostatectomy (RP) [68]. Catheter material may also have an influence on the occurrence of stricture. In the 1970s/80s several comparative studies in patients undergoing cardiac surgery demonstrated that non-coated latex catheters were associated with a greater incidence of urethritis and more stricture formation than silicone catheters [69-71]. Other studies showed no difference [72-74]. Modern latex catheters have polymeric coatings [75] due to the concern with regards to stricture alongside the risk of hypersensitivity and the demonstrable *in vitro* toxicity of latex. Prolonged urethral catheterisation has also been implicated in the aetiology of stricture (e.g., poly-trauma, burns patients) [48].

Summary of evidence	**LE**
A significant proportion of catheter insertions in hospitalised patients were considered unnecessary.	2b
Education programs can reduce the incidence of catheter-related urethral injury.	2a
Larger catheter size was associated with a greater risk of navicular fossa strictures.	3
Non-coated latex catheters are associated with a greater degree of urethritis and possibly a greater risk of urethral strictures than non-latex catheters or coated latex catheters.	1a

Recommendations	**Strength rating**
Avoid unnecessary urethral catheterisation.	Strong
Implement training programmes for physicians and nurses performing urinary catheterisation.	Strong
Do not use catheters larger than 18 Fr if urinary drainage is the only purpose.	Weak
Avoid using non-coated latex catheters.	Strong

d.2 Transurethral prostate surgery

Urethral stricture following transurethral prostate surgery occurs in between 4.5-13% of patients [76], whereas bladder neck stenosis (BNS) occurs in between 0.3-9.7% [77]. Transurethral surgery is the most common cause of iatrogenic urethral stricture accounting for 41% of all causes [48]. The most common location for urethral stricture is the bulbomembranous urethra, followed by the fossa navicularis and penile urethra [78, 79]. Postulated mechanisms include friction at the penoscrotal junction, lack of adequate lubrication, repetitive 'in and out' movement of the resectoscope, breach of mucosal integrity leading to urine extravasation and monopolar current leak due to inadequate resectoscope insulation [80]. Bladder neck stenosis may be related to excessive and/or circumferential resection and the use of relatively large resection loops which may generate excessive heat in small intraurethral adenomas leading to scarring [77, 81]. Stenoses of the posterior urethra may also be due to a prolonged period of post-operative inability to void [82].

d.2.1 Risk factors for development of urethral stricture and bladder neck stenosis

Several risk factors for the development of urethral stricture and BNS following transurethral prostate surgery have been identified. Both prostatic inflammation (OR: 4.31) and operative time > 60 min (OR: 4.27) were found to be independent predictors of stricture after monopolar transurethral resection of prostate (TURP) [83]. In terms of bipolar TURP, slower resection rate (OR: 0.003), intraoperative urethral mucosa rupture (OR: 2.44) and post-operative infection were shown to be independent predictors (OR: 1.49) [84, 85]. A larger-calibre endoscopic sheath (26 Fr vs. 24 Fr) was associated with a greater risk of bulbar urethral stricture following monopolar TURP (11.4% vs. 2.9%, p=0.018) [86]. Room temperature irrigation solution was associated with a greater risk of urethral stricture following combined transurethral resection and vaporisation of the prostate compared to body temperature irrigation (21.3% vs. 6.3%, p=0.002) [87].

Bladder neck stenosis is known to occur more frequently in smaller prostate glands after both monopolar and bipolar TURP [88, 89]. Lee *et al*., found that adenoma weight was an independent risk factor for BNS after monopolar TURP [89]. Meanwhile, Tao *et al.*, found total prostate volume (< 46.2 g) (OR: 1.5), but not resected gland weight, to be an independent risk factor [84].

d.2.2 Incidence of urethral stricture and bladder neck stenosis with different energy modalities

A SR and meta-analysis by Cornu *et al.*, showed no significant differences in urethral stricture and BNS rates by energy modality (monopolar, bipolar, holmium laser enucleation, photoselective vaporisation) [76]. In another meta-analysis assessing outcomes of thulium (Tm:Yag) laser and bipolar TURP, no difference in urethral stricture and BNS rates were found between the two modalities [90]. The presence of potentially confounding factors such as endoscopic sheath diameter, energy setting used, procedural length and length of follow-up make inter-study comparisons between energy modalities problematic. Overall, there is no strong evidence that

any single modality is associated with a clinically significant higher incidence of urethral stricture and BNS than others. Selection of modality should be based on a comprehensive evaluation of clinical safety and efficacy. A summary of incidences of urethral stricture and BNS with different modalities is presented in Table 3.1.

A systematic review analysing different techniques used for BPH surgery, showed the lowest incidence of urethral strictures in enucleation procedures, followed by B-TURP and ablation, and M-TURP. However, after twelve months of follow-up there were no significant differences in stricture rate [91].

Table 3.1: Incidence of urethral stricture and bladder neck stenosis by transurethral modality
(adapted from Chen et al. 2016 [77])

Modality	Urethral stricture	Bladder neck stenosis
Transurethral resection of prostate (TURP) - monopolar and bipolar	1.7 to 11.7%	2.4 to 9.7%
Holmium enucleation of the prostate (HoLEP)	1.4 to 4.4%	0 to 5.4%
Photo-selective vaporisation (PVP)	0 to 4.4%	1.4 to 3.6%

d.2.3 Interventions to prevent urethral stricture and bladder neck stenosis
Sciarra and colleagues conducted a single-blind RCT (n=96) to assess the use of rofecoxib for stricture prevention following TURP. At twelve months follow-up, a urethral stricture was found in 17% and 0% of cases in the placebo and rofecoxib groups, respectively (p=0.0039) [92]. Chung *et al.*, conducted a single blinded RCT (n=180) evaluating the effect of urethral instillation of hyaluronic acid (HA) and carboxymethylcellulose (CMC). Urethral stricture on urethrography was diagnosed in 1.25% and 8.64% of patients in the treatment and placebo group respectively (p=0.031). Further RCTs are needed to confirm these findings and the safety of the pharmacological interventions.

Several earlier comparative studies assessed whether routine preliminary urethrotomy with an Otis urethrotome prevented the incidence of stricture following TURP [93-96]. Only one of these reported at least twelve month follow-up, finding no significant difference in stricture rate in patients undergoing TURP alone vs. Otis urethrotomy followed by TURP (21% vs. 14%) [97]. Others have suggested performing internal urethrotomy where there are pre-existent meatal or urethral strictures [98].

Adjunctive transurethral incision of the prostate (TUIP) at the end of TURP to reduce the rates of BNS was studied by Lee *et al*. [89]. A total of 1,135 patients of whom 667 underwent TURP and 468 underwent TURP plus TUIP were retrospectively studied. At median follow-up of 38 months, the incidence of BNS was 12.3% for the TURP group vs. 6.0% for the TURP plus TUIP group ($p < 0.001$). In glands < 30 g, the incidence of BNS in the TURP vs. the TURP plus TUIP group was 19.3% and 7.7%, respectively ($p < 0.05$). The clinical efficacy and safety of additional surgical interventions to prevent urethral stricture and BNS need to be confirmed in larger prospective RCTs before their use can be recommended.

Summary of evidence	LE
An RCT with more than twelve months follow-up failed to demonstrate a significant reduction in stricture rate using routine urethrotomy prior to TURP.	1b

Recommendation	Strength rating
Do not routinely perform urethrotomy when there is no pre-existent urethral stricture.	Strong

d.3 Radical prostatectomy
Radical prostatectomy has been associated with vesico-urethral anastomosis stricture (VUAS) in 0.5-30% of patients [77], though most modern series report it in the range of 1-3% [99]. The risk of stricture formation after salvage RP is notably higher (22-40%) [100]. Most VUAS develop within the first two years [100, 101]. A 2012 meta-analysis by Tewari *et al.*, showed no significant difference in VUAS between open-, laparoscopic and robotic RP [102]. In contrast, a more recent analysis of a national cohort in the UK found that VUAS rate after robotic RP was 3.3%, which is significantly lower than following laparoscopic (5.7%) or open RP (6.9%) [103]. These findings are consistent with an earlier similar study conducted in the USA [104]. The difference in VUAS rates may be explained by the level of experience and surgical volume of surgeons [105]. The cohort studies

represent "real world" data, including all levels of surgical experience and surgical volumes whereas the meta-analysis is based on clinical studies. Thus, the better outcomes for robotic RP in the population studies may be related to the shorter learning curve [106].

d.3.1 Risk factors for development of vesicourethral anastomosis strictures

These include higher grade cancer, more advanced stage, higher prostate volume, coronary artery disease, obesity, hypertension, diabetes mellitus, previous bladder outlet surgery and older age [99, 107, 108]. Surgical factors include the use of non-nerve-sparing technique, anastomotic urine leak, increased operative time and increased estimated blood loss [99, 107, 108]. In addition, low-volume surgeons (< 40/year) were shown to have higher VUAS rates, 27.7%, compared to high-volume surgeons (> 40/year), 22% [109].

d.3.2 Interventions to prevent vesicourethral anastomosis strictures

Srougi *et al*., studied bladder neck mucosal eversion in a prospective RCT of 95 patients. No significant difference was found in rates of VUAS at twelve months follow-up [110]. A meta-analysis by Kowelewski *et al*., comparing interrupted vs. continuous vesico-urethral anastomosis suturing found no difference in VUAS rates [111]. Another SR by Bai *et al*., compared barbed sutures to conventional sutures, and although heterogeneity across studies precluded meta-analysis, no patients developed VUAS with either approach [112].

d.4 Prostate radiation and ablative treatments

Urethral strictures occur in 1.5% of patients undergoing external beam radiation therapy (EBRT), 1.9% having brachytherapy (BT) and 4.9% who receive combination EBRT-BT at around four years follow-up [113]. These strictures typically occur in the bulbomembranous urethra [114]. As opposed to RP, stricture incidence after irradiation increases with time [100, 113]. For the ablative treatments, the stricture incidence after cryotherapy and high-intensity focused ultrasound (HIFU) is 1.1-3.3% and 10.3%, respectively [100, 115]. The use of these modalities in the salvage setting is associated with increased risk of stricture formation: 3-10% after salvage EBRT, 5-12% after salvage cryotherapy and 15-30% after salvage HIFU [100]. Due to the increasing utilisation of prostate irradiation (EBRT, BT) and ablative treatments (cryotherapy, HIFU), an increasing number of respectively radiation-induced and ablative treatment-induced strictures are expected [116].

d.4.1 Risk factors for the development of radiation strictures

Awad *et al*., performed a multivariate meta-regression analysis including 46 studies, finding combining ERBT + BT and length of follow-up to be significant predictors of urethral stricture following prostate radiation [113]. Factors not shown to predict urethral stricture included biochemical equivalent dose, age, and androgen deprivation therapy [113]. Previous TURP was not included in the analysis, but has been found to be an independent predictor of stricture (HR: 2.81) in a previous multivariate analysis from a single institution [117] as well as PSA level < 10 ng/ml (HR: 0.47) [118].

d.4.2 Interventions to prevent radiation induced urethral strictures

Delaying adjuvant or salvage EBRT by nine months is associated with lower rates of urethral stricture (HR: 0.6) [119]. This has to be balanced with risk of delaying treatment in terms of cancer control [77]. In BT, it has been reported that downward movement of needle applicators occurs between fractions [120]. This may explain why strictures occur below the prostatic apex [118] in the so called "hot spot" [121]. Several measures taken together are thought to have contributed to a reduction in urethral stricture formation with BT including reduction of dose to the "hot spot", more careful needle placement, avoiding midline insertion and the introduction of plastic needles rather than steel [113].

e. Failed hypospadias repair

Although urethral strictures after hypospadias repair are sometimes considered as iatrogenic [36], they are a very specific subtype and should be considered as a separate entity. The main reasons for this are the absence of spongiosus tissue at different levels within the penile urethral segment, and the lack of high-quality local tissues for urethral reconstruction [122].

f. Congenital

The diagnosis of a congenital urethral stricture can only be made in the absence of other possible aetiology, such as iatrogenic, inflammatory, and traumatic causes [123]. Congenital strictures are thought to be consequent to incomplete or incorrect fusion of the urethra formed from the urogenital sinus with the urethra formed following closure of the urethral folds. They typically have a deep bulbar location and are usually short. In general, congenital strictures are diagnosed at a young age (Moorman's ring or Cobb's collar).

g. Idiopathic
Idiopathic strictures are seen in 34% of all penile strictures and in 63% of all bulbar strictures [124]. Unrecognised trauma is thought to be a possible aetiology of idiopathic urethral strictures [26].

3.3.2 ***Aetiology in females***
The cause of FUS was idiopathic in 48.5%, iatrogenic in 24.1%, resulting from prior urethral dilations, difficult/traumatic catheterisation with subsequent fibrosis, urethral surgeries (mainly diverticulum surgery, fistula repair and anti-incontinence procedures) and trauma (mainly following pelvic fracture) in 16.4% [125-137]. Radiation therapy and infections are rare causes of FUS [138]. The most common segment of urethra affected is the mid- or mid-to-distal (58%). Panurethral strictures are rare (4%) [15, 125, 127, 128, 130-132, 137, 139].

For further information see online supplementary Tables S3.1 and S3.2.

4. CLASSIFICATIONS

4.1 According to stricture location
Classification according to stricture location is important as this will affect further management.

4.1.1 ***In males***
4.1.1.1 Anterior urethra
The anterior urethra runs from the meatus to the urogenital diaphragm and is surrounded in its entire length by the corpus spongiosum [11, 140]. Further subdivision is made in three different areas (from distal to proximal) [12]:

Meatal strictures: these strictures are located at the external urethral meatus and may extend into the fossa navicularis of the glans.

Penile strictures: these are located in the segment between the fossa navicularis and the bulbar urethra. Externally, the penile urethra begins approximately at the balanopreputial sulcus and continues to the penoscrotal junction. The whole penile urethral segment lies in the groove ventral to corpora cavernosa and is surrounded by a thin layer of corpus spongiosum.

Bulbar strictures: the bulbar urethra starts at the penoscrotal junction and is surrounded by the bulbospongious muscle. It ends in the membranous urethra proximally at the level of the urogenital diaphragm. The bulbar urethra can be subdivided into a proximal and distal part. The proximal bulbar urethra is defined as the segment within 5 cm of the membranous urethra; the urethra lies eccentrically in this part with abundant ventral spongious tissue. The distal bulbar urethra is defined as the adjoining segment extending to the penoscrotal junction [141]. Strictures extending towards the membranous urethra are termed bulbomembranous strictures (BMS).

Penobulbar strictures: these extend from the penile urethra into the bulbar segment, compromising long segments of urethra.

The difference between penobulbar strictures and multifocal strictures should be noted. The latter are defined by two or more narrowed segments, either in the same or different subdivision of the urethra but preserving healthy lengths of urethra between them (e.g., iatrogenic strictures related to TUR procedures which typically affect the fossa navicularis and the penoscrotal junction with healthy urethra in between).

4.1.1.2 Posterior urethra
The posterior urethra is approximately 5 cm long, with three different segments [12]:
- The membranous urethra is the area of the urethra traversing the urogenital diaphragm, between the proximal bulbar and the distal verumontanum.
- The prostatic urethra runs through the prostatic gland, starting at the proximal membranous urethra and extending to the bladder neck.
- The bladder neck is surrounded by the internal urinary sphincter and is the junction between the prostatic urethra and the bladder. Stenosis (or contracture) of the bladder neck implies a prostate *in situ* (i.e., after TURP or simple prostatectomies). If the narrowing or obliteration appears at this level but after a RP, the correct term is VUAS [12].

4.1.2 *In females*

The female urethra is approximately 4 cm long and arbitrarily divided in an upper, mid, and lower part [15, 125, 127, 128, 130-132, 137, 139].

4.2 According to stricture tightness

Several classifications systems have been proposed over the years [142]. The definition of low- vs. high-grade strictures remains debatable [143-145]. A urethral plate less than 3 mm is considered a high-grade or tight stricture [146]. It has been demonstrated with a normally functioning bladder that flow rate will not diminish until the urethral lumen has a diameter below 10 Fr [144].

Table 4.1 presents a suggested classification for male patients with a normal functioning bladder. This classification was developed by the EAU Urethral Stricture Panel based on a consensus process.

Table 4.1: EAU classification according to the degree of urethral narrowing

Category	Description	Urethral lumen (French [Fr])	Degree
0	Normal urethra on imaging	-	-
1	Subclinical strictures	Urethral narrowing but ≥ 16 Fr	Low
2	Low grade strictures	11-15 Fr	
3	High grade or flow significant strictures	4-10 Fr	High
4	Nearly obliterative strictures	1-3 Fr	
5	Obliterative strictures	No urethral lumen (0 Fr)	

4.3 Strictures in transgender men and woman

4.3.1 *Trans women*

After MtF gender confirming surgery, the penile urethra has been resected. Meatal strictures are defined as strictures occurring at the neomeatus, which is formed between the junction of the distal bulbar urethra and the neovagina. The other segments (bulbar and posterior) are the same as in a biological man.

4.3.2 *Trans men*

Four different areas can be identified in the urethra after FtM gender confirming surgeries [147]:

- The native urethra is the female urethral segment which remains preserved during surgery. It goes from the bladder neck to the original external meatus.
- The fixed part (pars fixa) or perineal urethra follows the native urethra, starting at the original external meatus. This segment is reconstructed using local tissues, typically vestibular mucosa, or anterior vaginal mucosa. Its course is similar to the bulbar urethral segment in males, but without being covered by spongiosal tissue.
- The anastomotic part is the area where the pars fixa joins the neophallus.
- The phallic urethra is the segment located within the neophallus or the metoidioplasty and is usually made of a skin tube. Its course is similar to the penile urethra in males, but without being covered by spongiosal tissue.

5. DIAGNOSTIC EVALUATION

A comprehensive diagnostic evaluation of urethral stricture disease encompasses clinical history and examination, urinalysis (+/- culture), uroflowmetry and post-void residual (PVR) assessment, radiography, and endoscopy.

5.1 Patient history

The purpose of history taking is to assess symptoms including severity and duration, possible aetiology, prior treatments, complications, associated problems, and patient factors that may impact upon surgical outcome.

The clinical presentation of urethral stricture disease is varied. In a retrospective analysis of 611 patients with an endoscopically confirmed diagnosis of urethral stricture, LUTS were the most common presentation (54.3%) followed by acute urinary retention (22.3%), urinary tract infection (UTI) (6.1%) and difficult catheterisation

(4.8%) [148]. In a retrospective study of 214 patients who underwent anterior urethroplasty, weak stream was reported as the most common individual LUTS (49%) followed by incomplete emptying (27%) and urinary frequency (20%) [149]. A further retrospective series of 614 patients undergoing anterior urethroplasty found post-void dribble to be present in 73% [150].

Genitourinary pain is a common feature, affecting 22.9-71% [34, 148]. Pain may be felt in the bladder and/or urethra, is associated with more severe LUTS, is more likely to be felt by younger men and resolves in most following reconstruction [32]. Other complaints include spraying (9%), visible haematuria (3.1-5%), urethral abscess/necrotising fasciitis (2.3%), urgency (14%) and incontinence (1-4%) [148, 149].

To establish aetiology, an enquiry about a history of pelvic, genital, or perineal trauma, prior instrumentation, prior surgeries, irradiation or focal therapies and urethritis should be made. It is important to document prior surgical approaches and date of the most recent intervention (e.g., dilatation) as this may impact upon the timing of radiological evaluation or surgical treatment.

Problems of sexual function are common in patients with urethral stricture disease [151, 152] and sexual function may be impacted upon by surgical intervention [153, 154]; therefore, the status of erectile and ejaculatory function should be established and documented using validated tools.

The performance status of the patient should be determined as it may influence the choice of treatment (curative or palliative). A past medical history should assess for factors that may impact upon tissue healing including diabetes, immunosuppression, and smoking. Oral tobacco use or the chewing of betel leaves may increase the risk of morbidity at the harvest site or render oral mucosa too poor for use. Prior harvest of oral mucosa should be noted as alternative sources for tissue transfer may need to be considered [155] or alternative surgical approaches (e.g., perineal urethrostomy [PU]).

5.2 Physical examination

The abdomen should be examined for the presence of a palpable bladder. The location of any suprapubic tube should be noted to assess its potential utility for antegrade cystoscopy or the placement of a sound (to facilitate repair) [156]. Examination of the genitalia should note the presence of foreskin, the position and size of the meatus as well as any evidence of scarring suggestive of LS. Pre-operative biopsy to confirm LS may be performed if this alters management and is essential if malignancy is suspected [157].

The presence of penile or perineal fistulae should be noted. The urethra should be palpated to assess for induration suggestive of significant fibrosis. Rarely a mass may signify a urethral carcinoma. A rectal examination to assess for prostatic pathology, which may be the cause of urinary symptoms, should be undertaken. In patients with posterior urethral stenosis rectal adherence to the prostate and the mobility of the surrounding tissues should be assessed [158]. The oral cavity should be examined for the suitability of oral mucosa. Measurement of BMI will identify obese individuals who are at greater risk of leg compartment syndrome when placed in the lithotomy position for a prolonged time period [159]. Assessing hip mobility is important when considering an exaggerated lithotomy position as some patients may have limited hip flexion due to unresolved orthopaedic problems [156].

*5.2.1 **Further diagnostic evaluation***

5.2.1.1 Patient reported outcome measure (PROM)

The first validated urethral stricture surgery PROM (USS-PROM) was reported in 2011 [160]. It consists of six LUTS questions derived from the International Consultation on Incontinence Questionnaire Male LUTS (ICIQ-MLUTS) module, a LUTS-specific QoL question, the Peeling voiding chart and the EQ-5D to assess overall health-related QoL (HRQoL). The post-operative questionnaire contains an additional two questions to assess overall patient satisfaction. This PROM has been validated in several other languages (German, Spanish, Italian, Dutch, Turkish, Polish, Japanese) and is increasingly used in research studies as well as clinical practice. A further PROM is in development in North America but requires validation [161] (see section 11. Follow-up).

Summary of evidence	**LE**
A specific urethral stricture surgery patient reported outcome measure was found to have psychometric validity in the assessment of patient-derived benefit from surgical intervention for urethral stricture disease.	2a
Sexual dysfunction is prevalent in patients with urethral strictures and sexual function can be affected by surgical management of urethral stricture.	3

Recommendations	Strength rating
Use a validated patient reported outcome measure (PROM) to assess symptom severity and impact upon quality of life in men undergoing surgery for urethral stricture disease.	Strong
Use a validated tool to assess sexual function in men undergoing surgery for urethral stricture disease.	Strong

5.2.1.2 Urinalysis and urine culture

Urinalysis is an essential component of the work up of patients with LUTS. If infection is suggested, urine culture should be performed to confirm the diagnosis and identify the causative organism and sensitivity to antibiotics. Bacteriuria should be treated prior to surgical intervention to prevent peri-operative sepsis [162] (see section 10. Peri-operative care).

5.2.1.3 Uroflowmetry and post-void residual estimation

A reduced maximum flow rate with a prolonged plateau is characteristic of the constrictive obstruction caused by urethral stricture. However, interpretation of flow patterns is subjective and is not considered a reliable screening tool for the detection of stricture [163]. To overcome this, a statistical model based on uroflowmetry parameters was developed and was found to predict urethral stricture with a sensitivity of 80–81% and a specificity of 77–78% [163]. Uroflowmetry is usually combined with ultrasound (US) estimation of PVR to identify patients with urinary retention who may require emergent bladder drainage. Uroflowmetry parameters can also be used for monitoring patients and in the assessment of treatment response (see section 11. Follow-up).

Urodynamic studies are not indicated in the vast majority of patients with urethral stricture disease. In patients with suspected bladder dysfunction (e.g., severe storage LUTS, history of irradiation or neurological disease), an assessment of bladder function may help surgical decision making and patient counselling. Similarly, when there is concern that flow impairment or increased PVR are due to detrusor underactivity or an acontractile detrusor, a urodynamic study may help predict the likelihood that the patient would need to perform intermittent self-catheterisation (ISC) post-operatively. The only urodynamic parameter found to distinguish a diagnosis of urethral stricture from BPO is urethral closure pressure which is lower in the former due to the constrictive nature of the obstruction (22.07 vs. 28.4 cm H_2O, p=0.0039, r=0.61, BPO vs. stricture) [164].

Summary of evidence	LE
Uroflowmetry pattern interpretation by use of a statistical model was found to be predictive of urethral stricture disease.	3

Recommendation	Strength rating
Perform uroflowmetry and estimation of post-void residual in patients with suspected urethral stricture disease.	Strong

5.2.1.4 Urethrography

Retrograde urethrography (RUG) has widely been used as the investigation of choice for evaluating the stricture presence, location, length, and any associated anomalies (e.g., false passages, diverticula) [165].

The reported sensitivity and specificity of RUG in the diagnosis of strictures is 91% and 72%, respectively [166]. The positive predictive value (PPV) was 89% and the negative predictive value (NPV) was 76% [166]. Most reports suggest that RUG underestimates stricture length [167, 168]. Interpretation of RUG findings by urologists were found to be more accurate at predicting urethral stricture location and length as compared to evaluation by an independent physician [169].

Limitations of RUG include difficulty assessing very distal strictures and assessing the proximal extent of strictures which are too narrow to permit passage of adequate contrast. Combining a RUG with voiding cystourethrography (VCUG) can allow adequate visualisation of the urethra proximal to the stricture and a more accurate assessment of stricture length in (nearly) obliterative strictures, stenoses and gap in pelvic fracture urethral injury (PFUI) [170, 171]. In addition, urethrography provides only a two-dimensional assessment of stricture and the results may be affected by the amount of penile stretch [172], degree of pelvic rotation and patient body habitus [173]. Risks of the procedure include infection, discomfort [164], contrast reaction from intravasation of contrast [174] in addition to the risk of radiation exposure. Urethrographic clamp devices (Brodny, Knutson) are available and were found to be less painful than using the Foley catheter technique [175].

Summary of evidence	LE
Retrograde urethrography is a widely available and easy to perform method of diagnosing and assessing urethral stricture but may underestimate stricture length.	2a
Retrograde urethrography alone is not able to assess stricture length (or gap) in obliterative strictures or stenosis.	2a
Urethrographic clamp devices are less painful than using the Foley catheter technique.	2a

Recommendations	Strength rating
Perform retrograde urethrography to assess stricture location and length in men with urethral stricture disease being considered for reconstructive surgery.	Strong
Combine retrograde urethrography with voiding cystourethrography to assess (nearly)-obliterative strictures, stenoses and pelvic fracture urethral injuries.	Strong
Use clamp devices in preference to the Foley catheter technique for urethrographic evaluation to reduce pain.	Weak

5.2.1.5 Cystourethroscopy

Cystourethroscopy allows for accurate visual detection of a suspected stricture or can rule out a stricture as cause of obstructive voiding [166]. It can detect narrowing of the urethral lumen before changes in uroflowmetry and symptoms [145]. Cystourethroscopy can also assess the presence of LS or other pathology but cannot usually assess stricture length as the calibre of most cystoscopes is greater than most symptomatic strictures [176]. To overcome this, use of smaller calibre ureteroscopes (6.5 Fr and 4.5 Fr) has been reported [176]. This also allows an assessment of the bladder prior to surgery and may identify other pathology such as bladder stones. Cystourethroscopy is particularly helpful for diagnosing proximal BMS which may be missed on RUG [177] .

Retrograde urethroscopy combined with antegrade cystoscopy via the suprapubic tract may be used to evaluate PFUI and plan the surgical approach. It allows an assessment of the length of the defect, the competence of the bladder neck, the involvement of the bladder neck in scarring in addition to identifying the presence of bony spicules or other abnormalities (e.g., fistulae, stones) [178]. Combined retrograde and antegrade cystoscopy was found to provide similar estimates of length of urethral defect in patients with PFUI as combined retrograde and antegrade cystourethrography, but was more likely to detect fistulae, false passages, and calculi [178].

Summary of evidence	LE
Cystourethroscopy will reliably detect the presence of a urethral stricture.	3
Combined retrograde urethroscopy and antegrade cystoscopy is more accurate than retrograde and voiding cystourethrography at identifying associated abnormalities such as fistulae, false passages, and calculi in patients with PFUI.	3

Recommendations	Strength rating
Perform cystourethroscopy as an adjunct to imaging if further information is required.	Weak
Combine retrograde urethroscopy and antegrade cystoscopy to evaluate pelvic fracture urethral injuries as an adjunct to imaging if further information is required.	Weak

5.2.1.6 Ultrasound

Ultrasound of the urethra or sonourethrography (SUG) provides a non-invasive three-dimensional assessment of anterior urethral stricture disease; including stricture location, length, and the degree of associated spongiofibrosis [179].

Several studies have compared SUG to RUG and cystoscopic or intraoperative findings. Sonourethrograpy was found to be more accurate at diagnosing stricture presence compared to RUG [175, 180]. Sonourethrography was also found to more accurately estimate stricture length (94% correlation with intraoperative findings) than RUG (59% correlation with intraoperative findings) ($p < 0.001$) [168]. A further study showed similar findings and found that the closest correlation for stricture length at operation was for strictures in the penile urethra [167]. Intraoperative sonourethrogram findings have also been found to change the planned reconstructive approach (based on pre-operative retrograde urethrogram) in 19% of men undergoing anterior

urethral reconstruction [173]. Sonourethrography incorporating real-time elastography can provide a qualitative and quantitative assessment of spongiofibrosis [181, 182]. The clinical relevance of assessing the degree of spongiofibrosis pre-operatively remains to be established. Three-dimensional reconstruction of sonographic images is investigational at present [183].

The advantages of SUG are that it can be performed in the outpatient setting, provides information on the degree of spongiofibrosis and its relatively low cost [179]. Limitations of the technique include lower sensitivity for detection of strictures in the bulbar urethra, operator dependency, and the need for urethral distension requiring intraurethral anaesthesia. Sonourethrography requires specialised training in the use of US and is currently not in widespread usage.

Table 5.1: Diagnostic accuracy of sonourethrography compared to other modalities and surgical findings

Study	N	Segment of urethra studied	Comparator	Accuracy of SUG		
				Diagnosis	Location	Length
Berne-Mestre *et al*. 2018 [175]	113	Anterior and posterior	RUG, VCUG, surgical findings	SUG more accurate than RUG ($p < 0.05$)	-	-
Ravikumar *et al*. 2014 [180]	40	Anterior and posterior	RUG, VCUG, surgical findings	Anterior: SUG 100% sensitivity, 100% specificity Posterior: SUG 75% sensitivity, 50% specificity.	-	-
Kalabhavi *et al*. 2018 [168]	30	Anterior	RUG, surgical findings	-	-	-
Krukowski *et al*. 2018 [167]	66	Anterior	RUG, surgical findings	-	-	-

N = number of patients; RUG = retrograde urethrography; SUG = sonourethrography; VCUG = voiding cystourethrogram.

5.2.1.7 Magnetic resonance imaging

Magnetic resonance imaging (MRI) has been used to image PFUIs, posterior urethral stenoses and anterior urethral strictures.

Several studies have compared MRI urethrogram to RUG and intraoperative findings. Magnetic resonance imaging urethrogram was found to be as accurate as RUG at detecting stricture site in anterior urethral strictures [184]. In terms of stricture length both MRI urethrogram and RUG reliably correlated with intraoperative findings [184]. On the other hand, a further study of patients with anterior urethral strictures found MRI urethrogram stricture length to correlate more closely with surgical findings than RUG [185].

In a mixed group of anterior urethral strictures and posterior urethral stenoses, MRI urethrogram was as accurate (sensitivity = 100%, specificity = 91.7%) as combined RUG and sonourethrography (sensitivity = 100%, specificity = 91.7%) at diagnosing strictures [186]. There was no significant difference in the measurement of stricture length [186]. In a further study of patients with posterior urethral stenosis, MRI estimation of stenosis length correlated more closely with operative findings compared to RUG [187]. In patients with PFUI, MRI measurement of pubo-urethral stump angle (angle between long axis of pubis and line between the distal end of the proximal urethral stump and lower border of inferior pubic ramus) was predictive of an elaborated approach on multivariate analysis [188].

Magnetic resonance imaging was also found to be more accurate at diagnosing associated pathologies e.g., diverticula, tumours, fistulae, and stones [186]. In cases of fistulation between the urinary tract and pubic symphysis after irradiation for prostate cancer, the fistula tract can be clearly demonstrated on MRI [189]. Other imaging modalities, including computed tomography (CT), may fail to identify the tract and the problem may be misdiagnosed as isolated osteomyelitis of the pubic bone leading to medical management with antibiotics rather than surgical excision [189].

The main advantage of MRI is greater anatomical detail, which is countered by the expense of the procedure and the greater complexity in interpreting images. The technique is not commonly used for routine situations, but it may be helpful in diagnosing associated pathologies which may alter patient management.

Table 5.2: Diagnostic accuracy of MRI compared to other modalities and surgical findings

Study	N	Segment of urethra studied	Comparator	Accuracy of SUG		
				Diagnosis	Location	Length
Murugesan *et al*. 2018 [184]	32	Anterior	RUG, Surgical findings	MRI and RUG equivalent (100% sensitivity, 100% specificity)	-	-
Fath El-Bab *et al*. 2015 [185]	20	Anterior	RUG, Surgical findings	-	-	MRI more accurate than RUG.
El-Ghar *et al*. 2010 [186]	30	Anterior and posterior	RUG + SUG, Surgical findings	MRI and RUG equivalent (100% sensitivity, 91.7% specificity)	-	MRI and RUG equivalent.
Oh *et al*. 2010 [187]	25	Posterior	RUG + SUG, Surgical findings	-	-	MRI more accurate than RUG + VCUG.

MRI = magnetic resonance imaging; n = number of patients; RUG = retrograde urethrography; SUG = sonourethrography; VCUG = voiding cystourethrogram.

Summary of evidence	LE
Magnetic resonance imaging is more accurate than retrograde urethrography and voiding cystourethrography at determining length of posterior urethral stenoses and can detect alternative associated pathologies e.g., diverticula, fistulae.	2a

Recommendation	Strength rating
Consider magnetic resonance imaging urethrography as an ancillary test in posterior urethral stenosis.	Strong

Figure 5.1: Diagnostic flowchart of patients with suspected urethral stricture disease

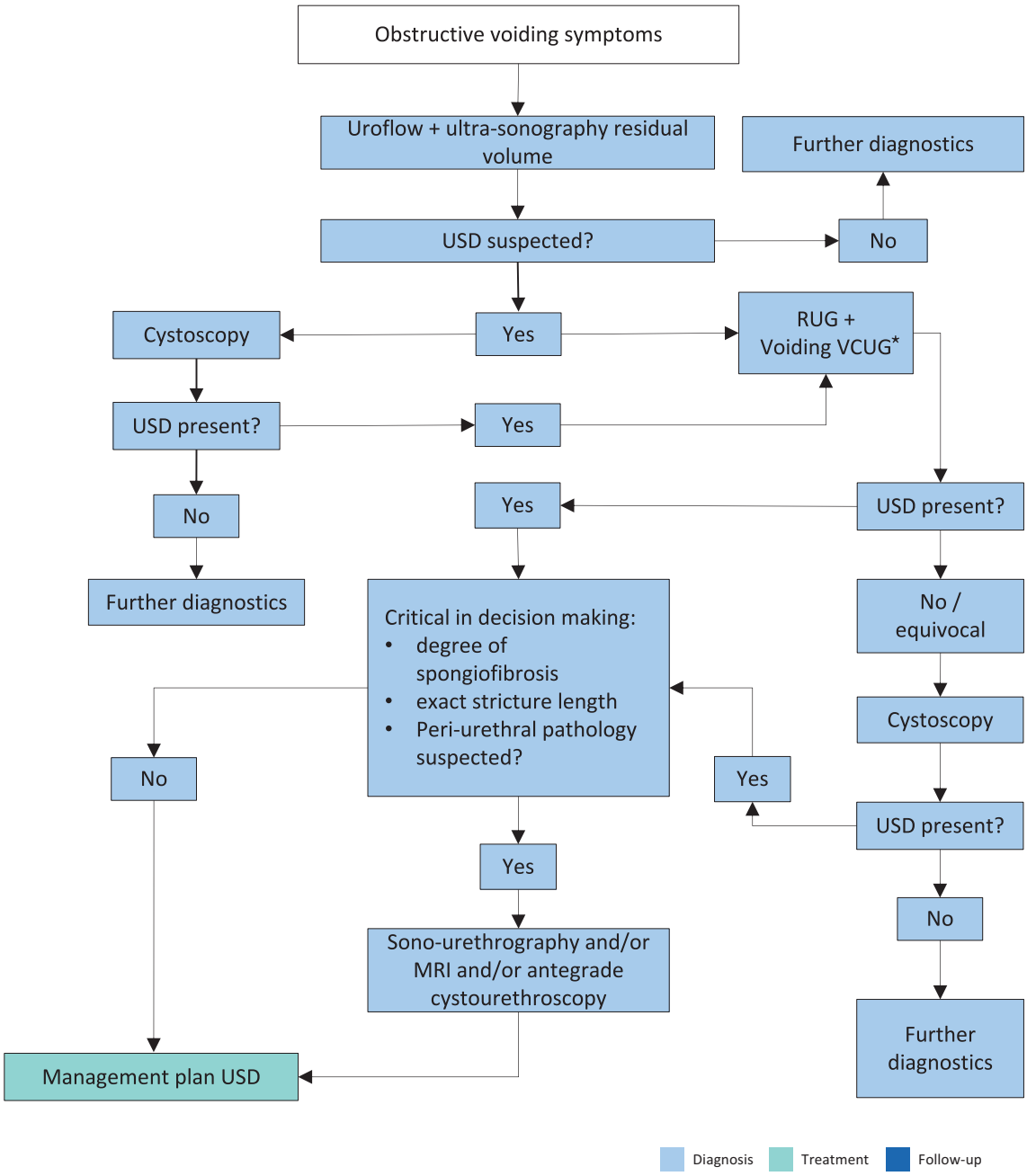

**Use VCUG in case of (nearly-) obliterative strictures or stenosis.*
MRI = Magnetic resonance imaging; RUG = retrograde urethrography, USD = urethral stricture disease; VCUG = voiding cystourethrogram.

6. DISEASE MANAGEMENT IN MALES

6.1 Conservative options

6.1.1 Observation

A stricture will usually result in diminution in flow once the calibre of the urethral lumen is < 10 Fr [144]. In other strictures (> 10 Fr), the diagnosis is often made by coincidence in asymptomatic patients because of a urologic examination for other reasons (e.g., cystoscopy, need for urethral catheterisation) [144]. Purohit *et al*., performed observation and repeated cystoscopic evaluation of 42 subclinical, incidentally encountered strictures (> 16 Fr). After a median follow-up of 23 months, only five (12%) strictures progressed to a low-grade stricture (11-15

Fr). No patient developed symptoms and none of them needed surgical intervention [144]. These patients are candidates for observation although no evidence exist on the long-term evolution of these strictures.

In a series of anatomic stricture recurrence (< 16 Fr) after urethroplasty, only 65% of patients were symptomatic [145]. Some asymptomatic patients refused further intervention because they had experienced substantial improvement after their primary urethroplasty. These patients were considered as functional "successes" [145]. A multicentric study of the Trauma and Urologic Reconstructive Network of Surgeons observed an important discrepancy between cystoscopic recurrence and need for further intervention [143]. Patients with a large calibre (> 16 Fr) recurrence had a one and two-year need for intervention rate of 4% and 12%, respectively. Of note, patients with small-calibre (< 16 Fr) recurrence had a one and two-year need for intervention rate of only 41% and 49%. Patients who needed intervention had poorer PROMs suggesting clinical symptoms and bother. There is no information on long-term complications in patients with recurrences who did not undergo intervention. In cases of an asymptomatic stricture recurrence, it might be an option not to intervene but to perform regular follow-up.

Care must be taken about the term "asymptomatic" stricture (recurrence) as patients might conceal their bother and symptoms by different means (not drinking, social avoidance) and might only search for medical help once concealment is no longer tenable [190].

6.1.2 Suprapubic catheter

Radiation-induced urethral strictures are a difficult to treat population as stricture-free rates for urethral reconstruction are lower compared to those in non-irradiated patients [191]. Fuchs *et al.*, evaluated 75 patients who were initially treated by suprapubic diversion for radiation-induced isolated BMS [192]. Only 51% eventually decided to undergo urethroplasty after a mean follow-up period of 25 months. Although there was no significant difference in overall performance status between patients with a chronic suprapubic catheter vs. those undergoing urethroplasty, all patients with a poor performance score remained with a suprapubic catheter. Patients with concomitant stress urinary incontinence (SUI) opted more often to keep their suprapubic catheter as the SUI improved in 61% of cases. On the other hand, patients who kept their suprapubic catheter suffered from catheter-related complications in 27% of cases. Urinary diversion by ileal conduit was performed in 30% of patients who remained with a suprapubic catheter while this was only the case in 8% who underwent urethroplasty. A suprapubic catheter is also an option in frail patients not able to undergo surgery or in patients who do not want (further) urethral surgery and are willing to accept the complications of a suprapubic catheter [193].

Summary of evidence	LE
Patients with asymptomatic incidental (> 16 Fr) strictures have a low risk of progression and to develop symptoms.	3
Only half of the patients initially treated with a suprapubic catheter for radiation-induced bulbomembranous strictures will proceed with urethroplasty.	3

Recommendations	Strength rating
Do not intervene in patients with asymptomatic incidental (> 16 Fr) strictures.	Weak
Consider long-term suprapubic catheter in patients with radiation-induced bulbomembranous strictures and/or poor performance status.	Weak

6.2 Endoluminal treatment of anterior urethral strictures in males

The ability to treat the majority of strictures by less invasive and time-consuming means, offers obvious benefits particularly when specialist surgical services are not available, or patients simply prefer a more pragmatic immediately available solution.

6.2.1 Direct vision internal urethrotomy

In contemporary practice, direct vision internal urethrotomy (DVIU) is commonly performed as a first-line treatment of urethral strictures [194]. It is usually performed under general or spinal anaesthesia in well-resourced countries but shown to be well tolerated under local anaesthesia with or without sedation [195].

6.2.1.1 Indications of "cold knife" direct vision internal urethrotomy

6.2.1.1.1 Direct vision internal urethrotomy for primary stricture treatment

In the only high-level evidence study, Steenkamp *et al*., randomised 210 patients with seemingly comparable non-obliterative strictures at all locations of the urethra to either filiform dilatation vs. DVIU with local anaesthesia on an outpatient basis [196]. They collected objective data with RUG performed at seven follow-up visits (3, 6, 9, 12, 24, 36 and 48 months). This unique study showed that urethral dilatation is equally effective as DVIU but both procedure modalities become less effective with increasing stricture length (see section 6.2.1.1.3.1).

A retrospective cohort series on the primary treatment of patients with iatrogenic urethral strictures reported a significantly poorer patency rate for DVIU compared to urethroplasty techniques (32.2 versus 82.4-83.5%) [197].

Patency rates vary considerably between 8% and 77% after DVIU (predominantly without prior urethroplasty) in retrospective cohort studies with minimum follow-up of one year [67, 198-204] (Table 6.1). Median time to recurrence was less than twelve months in most series [67, 198-202]. This large variation in patency rate can be in part explained by the heterogeneous nature of the strictures and various definitions of patency used by the authors in these series. Indication to perform DVIU is dependent on various stricture characteristics that are prognostic for a successful outcome.

Table 6.1: Results of DVIU in series with minimum follow-up > 12 months

Study	N	Age (years)	Follow-up (months)	Location	Length (cm)	Previous interventions	TTR (months)	Patency rate (%)
Al Taweel *et al*. [200]	301	37 (range: 17-82)	36	Bulbar: 227 (75%)	1.3 (0.4-4.2)	Primary: 47%	10	8.3
				Penile: 50 (17%)		Recurrent: 53%	-	-
				Penobulbar: 24 (8%)				
Barbagli *et al*. [199]	136	37 (IQR: 25-48)	55 (range: 36-92)	Bulbar: 100%	1-2 cm: 45%	Primary: 100%	25	57
					2-3 cm: 40%			
					3-4 cm: 15%			
Kluth *et al*. [198]	128	64 (SD: 16)	16 (IQR:6-43)	Penile: 15 (12)	NR	Primary: 66%	8	52
				Bulbar: 112 (88)		Recurrent: 34%	-	-
				Unknown: 1 (1%)				
Pal *et al*. [201]	186	39 (SD:15)	1st DVIU: 58 (SD: 15)	bulbar: 100%	NR	Primary: 69%	8.5	1st DVIU: 30
			2nd DVIU: 56 (SD: 15)			Repeat: 31%	-	2nd DVIU: 23
			3rd DVIU: 45 (SD: 15)					3rd DVIU: 13
Launonen *et al*. [202]	34	6 (range: 0-16)	79 (range: 7-209)	Bulbar: 74%	≤ 2 cm: 85%	Primary: 100%	4	26%
				Penile: 21%	> 2 cm: 15%			
				Penobubar: 6%	-			
Redon-Galvez *et al*. [203]	67	57 (range: 15-91)	40 (range: 12-120)	Penile:9%	≤ 1 cm: 82%	Primary: 90%	< 24	63%
				Bulbar: 64%	> 1 cm: 18%	Repeat: 10%	-	-
				VUA: 21%				
				Membranous: 6%				
Güler Y. [197]	234	57 (range: 22-74)	47 (range: 24-56)	Penile: 34%	2.5 (0.4-5)	Primary: 100%	-	34%
				Bulbar: 59%				30%
				Membranous: 6%				33%
Harraz *et al*. [204]	430	50 (SD: 15)	29 (range: 3-132)	Bulbar: 100%	< 2 cm	NR, prior urethroplasty excluded	NR	58%

Yürük *et al*. [67]	193	65 (SD: 13)	36 (SD: 12)	Bulbar: 100%	< 1 cm: 140 (73%)	0%	87% of recurrence ≤ 3	77%
					1-2 cm: 21 (11%)	-	100% of recurrence ≤ 6	-
					2-3 cm: 32 (17%)			

DVIU = Direct vision internal urethrotomy; IQR = interquartile range; N = number of patients; NR = not reported SD = standard deviation; TTR = time to recurrence.

6.2.1.1.2 Direct vision internal urethrotomy for recurrent strictures and as salvage treatment after failed urethroplasty

In the OPEN trial, a recurrent stricture was defined as at least one previous failed intervention (endoscopic urethrotomy, urethral dilatation, urethroplasty) [205]. The previous intervention was predominantly DVIU. Despite poor recruitment, 108 and 112 patients were randomised to urethroplasty and DVIU respectively in a 24-month study protocol. Both groups had a similar improvement in voiding score symptoms after intervention. However, patients undergoing urethroplasty had 2.6 higher odds of experiencing an improvement of > 10 ml/s in their maximum urinary flow compared to those undergoing urethrotomy (p=0.001) [205]. Need for re-intervention was observed in 13.8% vs. 25.9% of cases respectively allocated to urethroplasty and DVIU resulting in a 48% lower risk for re-intervention with urethroplasty (HR: 0.52; 95% CI: 0.31-0.89; p=0.017) [205]. Of note, self-dilatation was not considered a re-intervention [205]. Despite more re-interventions in the DVIU group, both treatments resulted in a similar improvement in quality of life but with a higher cost for urethroplasty with the limitation that the follow-up is only two years. [206]. Direct vision internal urethrotomy is also used as salvage treatment for recurrent strictures after urethroplasty. Brown *et al.*, used DVIU for stricture recurrence (mean length: 4 cm; range: 1.5-7 cm) after excision and primary anastomosis (EPA), buccal mucosa grafts (BMG) urethroplasty and penile skin graft urethroplasty [207]. Patency was obtained in thirteen out of 37 cases (35%) after a single DVIU. After free graft urethroplasty (FGU), a short, veil-like stricture (or "diaphragm") might develop at the distal or proximal end of the graft. Rosenbaum *et al.*, used DVIU to a selected cohort of 43 patients with a short (< 1 cm), veil-like stricture after BMG urethroplasty [208]. After a mean follow-up of twelve months, patency rate was 51%.

6.2.1.1.3 Predictors of failure of "cold knife" direct vision internal urethrotomy

Several groups tried to identify prognostic factors to predict which patients are most likely to fail initial treatment (Table 6.2).

In the absence of well-designed, adequately powered multi-centre trials it is difficult to answer the question as to which clinical factors are predictive of failure of DVIU in men with urethral strictures. However, based on the predictors evaluated above, one can summarise that the best candidates are previously untreated patients with a single, short (max. 2 cm) bulbar stricture. Barbagli *et al.*, reported a five-year patency rate of 71% for patients with untreated short (1-2 cm) bulbar urethral strictures [199].

Table 6.2: Predictors for urethral patency after direct vision internal urethrotomy

Author	Location	Length	Calibre	Multiplicity	Prior DVIU
Steenkamp *et al*. [196] / Heyns [209]	RR for recurrence penile vs. bulbar: 1.85 (95% CI: 0.94 to 3.67, p = 0.077)	< 2 cm: 60% (@12 months)	NR	NR	None: 50-60% (@48 months)
	-	2-4 cm: 50% (@12m)	-	-	1: 0-40% (@48 months)
	-	> 4 cm: 20% (@12 months)	-	-	2: 0% (@24 months)
Al Taweel *et al*. [200]	Bulbar: 11%	< 1 cm: 27%	NR	NR	0: 12.1%
	Penile: 0%	1-2 cm: 0%	-	-	1: 7.9%
	Penobulbar: 0%	> 2 cm: 0%	-	-	> 1: 0%

Barbagli *et al*. [199]	NA	1-2 cm: 71% (@60 months)	pQ_{max} < 5 ml/s: 31%	NA	0: 62%
	-	2-3 cm: 51% (@60 months)	pQ_{max} 5-8 ml/s: 53%	-	1: 37%
	-	3-4 cm: 39% (@60 months)	pQ_{max} > 8 ml/s: 83%	-	-
Kluth *et al*. [198]	Location no predictor	NR	pQ_{max} no predictor	NR	0: 60%
	-	-	-	-	≥ 1: 39%
Pal *et al*. [201]	NA	< 1 cm: 45%	NR	Single: 35%	0: 30%
	-	1-1.5 cm: 0%	-	Multiple: 0%	1: 23%
	-	> 1.5 cm: 0%	-	-	2: 13%
Launonen [202]	Bulbar: 76%*	< 2 cm: 83%*	NR	NR	0: 26%
	Penile: 71%*	> 2 cm: 0%*	-	-	1: 33%
	-	-	-	-	2: 26%
	-	-	-	-	3: 11%
	-	-	-	-	4: 0%
Redon-Galvez [203]	NR	≤ 1 cm: 71%	NR	NR	NR
	-	> 1 cm: 25%	-	-	-
Güler Y [197]	Bulbar: 30%	<1.85 cm: OR: 0.86 (95% CI: 0.74-0.99; p=0.042)	NR	NR	NR
	Penile: 34%				
	Membranous: 33%				

DVIU = Direct vision internal urethrotomy; NA = not applicable; NR = not reported; pQ_{max} = pre-operative maximum urinary flow; RR: relative risk; OR: Odds ratio; CI: confidentialtiy interval.
**patency rates are reported after repetitive treatments.*

6.2.1.2 Indications of "hot-knife" direct vision internal urethrotomy

6.2.1.2.1 Laser urethrotomy

Lasers available for urological applications, including Neodymium:YAG, Argon, Holmium:YAG, Potassium titanyl phosphate (KTP) and Tm:Yag, have been used for the treatment of urethral strictures. A SR identified four RCTs comparing laser urethrotomy and the "cold knife" urethrotomy. All studies were limited by short-term outcome evaluation and none of these four studies specified the results based on the location of the stricture. Two of these studies reported specific recurrence rates and meta-analysis showed a relative risk (RR) for recurrence of 0.55 (95% CI: 0.18-1.66; p=0.29), 0.39 (95% CI: 0.19-0.81; p=0.01) and 0.44 (95% CI: 0.26-0.75; p=0.003) in favour of laser urethrotomy after three, six and twelve months respectively [210]. Jin *et al.*, performed a SR including 44 case series on laser urethrotomy or "cold knife" DVIU [211]. This included nineteen articles on laser urethrotomy and 25 articles on "cold knife" DVIU. The overall weighted average stricture-free rate was 74.9% (371/495) and 68.5% (1874/2735) for laser vs. "cold knife" DVIU, respectively (p=0.004). Although statistically significant, the results must be interpreted with caution because of heterogeneity and because no details are provided on follow-up duration. Specifically looking at first DVIU, laser and "cold knife" DVIU obtained a stricture-free rate of 58.6% and 42.7%, respectively and the difference was no longer statistically significant (p=0.09). At the bulbar urethra, laser and "cold knife" DVIU yielded a stricture-free rate of 52.9% and 60%, respectively (p=0.66) [211].

After publication of this SR, the EAU Guideline Panel scope search identified three additional RCTs [212-214]. In the RCT of Yenice *et al.*, patients with a primary, bulbar stricture were randomised either to "cold knife" DVIU (n=29) or holmium:YAG laser urethrotomy (n=34). After twelve months follow-up, no significant difference in patency rate was identified (79% for "cold knife" DVIU vs. 68% for laser urethrotomy, p=0.3) [213]. In their RCT, Chen *et al.*, reported a better patency rate after one year with laser (n=24) compared to "cold knife" (n=22) DVIU (respectively 88% vs. 18%; p < 0.05). However, after two years the benefit for laser disappeared and after five years both techniques showed a low patency rate: 9% for "cold knife" DVIU vs. 12% for laser DVIU (p > 0.05) [212]. Gamal *et al.*, randomised patients between "cold knife" DVIU (n=40) and Holmium:Yag laser DVIU (n=40). At one year, they found an equally effective improvement of maximum urinary flow in both groups.

6.2.1.2.2 Plasmakinetic (bipolar) urethrotomy

Cecen *et al.*, conducted an RCT comparing plasmakinetic with "cold knife" DVIU (n=136) [215]. They reported patency rates for plasmakinetic and "cold knife" urethrotomy at nine months in respectively 86% and 70% of cases (p=0.025). At eighteen months, patency rates for plasmakinetic and "cold knife" urethrotomy were 63% and 67%, respectively (p=0.643) [215]. A prospective cohort study on primary strictures < 2 cm reported a patency rate at twelve months in 23/30 (77%) cases for plasmakinetic DVIU vs. 19/30 (63%) cases with "cold knife" DVIU (p=0.04) [216]. A retrospective case series (n=27) reported a 74% patency rate for short (1-2.5 cm) strictures after a mean follow-up of fourteen months [217]. They reported negligible blood loss during the procedure and no post-operative incontinence.

Based on the conflicting results described above and considering the heterogeneity of series and absence of long-term follow-up, overall, the available studies do not support the efficacy of one technique of DVIU over another. Given the similar complication rates between techniques (see section 6.2.1.3), no recommendation can be made in favour of one technique over another.

6.2.1.3 Complications of direct vision internal urethrotomy

6.2.1.3.1 Complications of "cold knife" direct vision internal urethrotomy

An overall complication rate of 6.5% was reported in a SR of Jin *et al.*, based on twelve articles including 1,940 patients [211] (Table 6.3).

Notably, erectile dysfunction (ED) was reported in 5.3% of cases in this review [211]. In addition, Graversen *et al.*, reported ED in eleven out of 104 (10.6%) patients [218]. This risk appears higher in strictures located in the penile urethra and, in addition to the poor patency rates, the use of DVIU in the penile urethra must be discouraged [218, 219].

6.2.1.3.2 Complications of "hot knife" direct vision internal urethrotomy

The SR of Jin *et al.*, reported a total complication rate of 11.8% (39/330) [211] (Table 6.3).

6.2.1.3.3 Complications of "cold knife" vs. "hot knife" direct vision internal urethrotomy

In a SR of RCTs comparing "cold knife" DVIU vs. laser DVIU, only 1/4 series reported complications [210].
In the laser group, an 8.9% complication rate was found due to contrast extravasation to the perineum and stricture recurrence. For the "cold knife" DVIU, a 15.5% complication rate was reported related to bleeding [210]. Two later RCT's reported similar rates of urinary extravasation [212, 213] and urinary incontinence (UI) [212] with both techniques.

The SR of retrospective case series of Jin *et al.*, found no significant differences in the incidence rates of UI, urinary extravasation and UTI between laser and "cold knife" DVIU [211]. However, urinary retention and haematuria were more frequent with laser compared to "cold knife" DVIU [211]. Conversely, In the series of Yenice *et al.*, haematuria was only reported after "cold knife" DVIU but not after laser DVIU (p=0.6) [213] (Table 6.3).

Table 6.3: Complications after "cold knife" DVIU vs. laser DVIU

Study/Complication	"Cold knife" DVIU (%)	Laser DVIU (%)	p-value
Jin *et al.* [211]			
Urinary extravasation	2.9	3.1	0.938
Urinary incontinence	4.1	2.1	0.259
Urinary tract infection	2.1	2.7	0.653
Urinary retention	0.4	9	< 0.0001
Haematuria	2	5.2	0.034
Epididymitis	0.5	NR	NA
Fever	2.3	NR	NA
Scrotal abscess	0.3	NR	NA
Erectile dysfunction	5.3	NR	NA
Urinary tract irritation	NR	11.4	NA
Urinary fistula	NR	1.5	NA

Dysuria	NR	5.1	NA
Yenice *et al*. [213]			
Urinary extravasation	0	2.9	0.6
Haematuria	10	0	
Chen *et al*. [212]			
Urinary extravasation	9.1	4.2	0.5
Urinary incontinence	4.5	4.2	

DVIU = direct vision internal urethrotomy; NA = not applicable; NR = not reported.

6.2.1.3.4 Complications of direct vision internal urethrotomy vs. dilatation

A Cochrane review found no significant differences for overall intra-operative complications (single dilatation vs. DVIU respectively 14% vs. 11%; RR: 0.75; 95 CI: 0.36-1.55) nor for individual complications (difficulty urinating, haematuria, false passage, pain, knotting/breaking/bending filiform leader) [196, 220]. The low rate of false passage for both DVIU and dilatation (respectively 0.96 and 0.94%) might be explained by the systematic use of a filiform leader in both groups which was inserted endoscopically in the dilatation group followed by coaxial dilatators [196, 220].

A small retrospective study comparing balloon dilatation (n=31) with DVIU (n=25) showed less urethral bleeding (6.5 vs. 32%; p=0.017) and UTI (3.2 vs. 24%; p=0.037) with balloon dilatation [221].

Apart from acute peri-operative complications described above, the stricture length and number of strictures were reported to increase after DVIU. Other authors mention that repeat urethral manipulations (DVIU and/or dilatation) can increase stricture complexity and delays time to urethroplasty [222].

6.2.1.3.5 Complications of "cold knife" direct vision internal urethrotomy vs. urethroplasty

The OPEN-trial reported adverse events of any type in 61% and 26.1% after urethroplasty (all types) and DVIU respectively [205]. In the urethroplasty group, mouth pain (related to oral mucosa graft [OMG] harvesting) and wound infection was noted as complication in respectively 14.6% and 4.9% of cases. Erectile dysfunction was 4.9% and 2.6% after urethroplasty and DVIU, respectively. Serious adverse events were reported in 8.5% and 8.7% after urethroplasty and DVIU respectively [205].

Summary of evidence	**LE**
Direct vision internal urethrotomy performs poorly in penile strictures. Direct vision internal urethrotomy at the penile urethra might provoke venous leakage from the corpora cavernosa with subsequent risk of erectile dysfunction.	1b
Increased stricture length is associated with higher risk of failure of direct vision internal urethrotomy (DVIU).	1b
In selected patients with a primary, single, short (< 2 cm) and non-obliterative bulbar stricture, a five-year stricture-free rate of up to 77% can be expected.	3
Direct vision internal urethrotomy has a stricture-free rate of 51% if performed for a short, veil-like recurrent stricture after prior bulbar urethroplasty.	3
There is conflicting evidence that "hot knife" (laser, plasmakinetic) DVIU would be superior compared to "cold knife" DVIU after more than one year of follow-up.	1a

Recommendations	**Strength rating**
Do not use direct vision internal urethrotomy (DVIU) for penile strictures.	Strong
Do not use DVIU/dilatation as solitary treatment for long (> 2 cm) segment strictures.	Strong
Perform DVIU/dilatation for a primary, single, short (< 2 cm) and non-obliterative stricture at the bulbar urethra.	Weak
Perform DVIU/dilatation for a short, veil-like recurrent stricture after prior bulbar urethroplasty.	Weak
Use either "hot" or "cold knife" techniques to perform DVIU depending on operator experience and resources.	Weak

6.2.2 *Single dilatation*

6.2.2.1 *Modalities of dilatation and results*

Dilatation can be done in the office, under local anaesthesia and without complex resources [223, 224]. With dilatation, the urethral mucosa at the stricture site is stretched and the scarring is disrupted. This is opposed to DVIU where the stricture is incised. However, both treatment modalities use the same principle to achieve urethral patency: a breach of the urethral mucosa at the site of the stricture in which re-epithelialisation should occur faster than wound contraction [220].

When dilators are used to dilate bulbar urethral strictures, considerable experience is required to avoid accidental perforation of the urethra at the level of the stricture. In order to reduce the risks (esp. false passage, spongiosal perforation, urethral bleeding) of "classic" blind dilatation with rigid sounds [224], other strategies have been developed and evaluated in which the dilatation is visually controlled after a guidewire has been inserted (Table 6.4).

Although no direct comparative studies of blind vs. visually controlled dilatation are available, several studies have reported a low complication rate with visually controlled modifications of dilatation. The recurrence rate largely varies between 23.5-64.5% (Table 6.4).

Table 6.4: Results of visually controlled dilatation

Study	Technique	N	FU (mo)	recurrence	Definition of failure	Complications			
						Haematuria	False passage	Procedural failure	UTI
Hosseini *et al*. [224]	Nelaton urethral catheters	333	43 (36-52)	138 (41.4%)	Need for additional intervention	12 (3.6%)	2 (0.6%)	NR	15 (4.5%)
Kallidonis *et al*. [225]	Coaxial S-curved	310	12	90 (33%)	No recurrence @1 yr with maximum one additional procedure	11 (3.5%)	0 (0%)	7 (2.2%)	33 (10.6%)
Nomikos *et al*. [226]	Amplatz + DVIU + ISD (1 yr.)	34	12	8 (23.5%)	Stricture recurrence on urethroscopy/ urethrography	2 (5.8%)	NR	NR	3 (8.8%)
Yu *et al*. [221]	Balloon	31	15 (5-36)	20 (64.5%)	Need for subsequent urethroplasty	2 (6.5%)	0 (0%)	NR	1 (3.2%)

DVIU = direct vision internal urethrotomy; FU = follow-up; ISD = intermittent self-dilatation; mo = months; N = number of patients; NA = not applicable; NR = not reported; UTI = urinary tract infection; yr = year.

6.2.2.2 *Effectiveness of dilatation compared with direct vision internal urethrotomy*

A SR identified only one prospective RCT comparing dilatation with DVIU and failed to detect any differences [196, 220]. In a small (n=56) retrospective cohort study, the three-year estimated stricture recurrence-free survival was 35.5% and 28% for respectively balloon dilatation and DVIU (p=0.21) [221].

At present, there is lack of evidence to support the claim that dilatation is superior to DVIU (or *vice versa*) and therefore, the indications for single dilatation are the same as for DVIU.

Repetitive dilatation/DVIU with curative intent (see also section 6.2.1.1.3.6 Previous interventions) should be avoided as no long-term freedom of recurrence can be expected [223] and because of the significant risk of increasing stricture length and complexity and prolonging the time to urethroplasty (which has better patency rates) [222].

Summary of evidence	LE
Visually controlled dilatation after endoscopic or fluoroscopic guidewire placement has a low complication rate.	3

Repetitive dilatations/direct vision internal urethrotomy have no long-term freedom of recurrence and increase stricture complexity.	1b

Recommendations	Strength rating
Use visually controlled dilatation in preference to blind dilatation.	Weak
Do not perform repetitive (> 2) direct vision internal urethrotomy/dilatations if urethroplasty is a viable option.	Strong

*6.2.3 **Post-dilatation/direct vision internal urethrotomy strategies***

Several strategies have been developed and evaluated to prevent wound contraction, improve the stricture-free rate and time to stricture recurrence after dilatation or DVIU.

It is noteworthy that these strategies tend to stabilise the stricture rather than to keep the patient stricture-free and the reported outcomes should be understood in this respect.

6.2.3.1 Intermittent self-dilatation

6.2.3.1.1 Results

A SR identified six randomised and quasi-randomised trials comparing intermittent self-dilatation (ISD) with no ISD with a follow-up between eight and 24 months [227]. Stricture recurrence was reduced in men performing ISD (85/197, 43%) vs. those who did not (128/207, 62%) (RR: 0.70; 95% CI: 0.48-1.00; p=0.05). There was significant heterogeneity, and the quality of included studies were very low, which led the authors to conclude there is uncertainty about the estimate [227]. This review found no significant difference in adverse events between ISD and no ISD (RR: 0.60; 95% CI: 0.11-3.26; p=0.56) [227]. One trial containing 48 patients found no significant difference in six vs. twelve months duration of ISD (RR: 0.67; 95% CI: 0.12-3.64) and another trial (n=59) found no significant difference from using a low-friction hydrophylic vs. a polyvinyl chloride catheter (RR: 0.32; 95% CI: 0.07-1.40) [227]. Other studies have been published after this SR of 2014. Chhabra *et al*., reported that patients complying with ISD after dilatation had a lower need for re-intervention than those who did not, 12.3% vs. 20.5% respectively (p=0.2) [228]. After a mean follow-up of 25 months, Greenwell *et al*., found a need for subsequent intervention in 13/31 (42%) men performing ISD vs. 47/95 (49%) who did not (p=0.46). The number of re-operations in patients with need for subsequent intervention was lower in the group performing ISD vs. those who did not (2.6 vs. 3.4). No major complications were reported in both groups [229].

6.2.3.1.2 Complications

The potential benefit of ISD in stabilising the stricture must be balanced against the drawbacks. Commonly reported complications are urethral bleeding (7.1%) [230] and UTI/epididymitis (4.7-18.1%) [231, 232]. A multicentric prospective study (n=85) reported that respectively 35% and 26% of patients had moderate to severe difficulties in catheterisation and respectively 32% and 17% of patients suffered moderate to severe pain while performing ISD. This had a serious impact on QoL which was rated moderate and poor in 32% and 55% of patients, respectively [33]. Younger age was identified as predictor for poor QoL, and QoL was more impaired in proximal stricture location (posterior and bulbar) [33]. In a study of 286 patients (mainly > 60 years old) performing ISD, 20% experienced problems with ISD and 33% had at least one infection annually. After a mean follow-up of 58 months 67% still continued with ISD [233]. Khan *et al*., reported eight “drop-outs” of 30 (26.7%) men randomised to ISD [232]. Of these eight “drop-outs”, two were unable to perform ISD and one stopped because of pain.

As mentioned above, repetitive dilatation (including ISD) increases stricture complexity and delays time to urethroplasty [222, 234].

6.2.3.1.3 Intermittent self-dilatation combined with intra-urethral corticosteroids

To delay wound contraction at the stricture site, intra-urethral corticosteroids (as a catheter lubricant) have been used to improve the results of ISD. In 2014, a SR identified three prospective RCTs comparing ISD and local steroid (triamcinolone) ointment vs. ISD without local steroid ointment [235]. These three studies included a total 67 and 68 patients randomised to local steroid, or not, with a follow-up ranging between twelve and 36 months. There were fifteen (22.4%) recurrences in the steroid group and 25 (36.7%) in the control group (OR: 0.51; 95% CI: 0.24-1.10; p=0.09) [235]. Time to recurrence was longer in the steroid group vs. the control group (weighted mean difference = 0.29; 95% CI: 0.08-1.00; p=0.05). There was no difference in adverse events between groups [235].

Since 2014, two additional RCTs have been published. Ergun *et al*., evaluated patients after DVIU for primary short (< 2 cm), bulbar (82%) or posterior (18%) strictures that were further randomised between ISD (n=30) and ISD + triamcinolone ointment (n=30) for six weeks. Stricture recurrence rate after 24 months was not significantly different between ISD and ISD + triamcinolone (respectively 33.3 and 30%) [236]. On the other hand, Regmi *et al*., found a lower stricture recurrence rate (22% vs. 46%, p=0.04) in patients performing ISD + triamcinolone (n=27) vs. ISD alone (n=28) [237]. In this study, median time to recurrence was 7.4 ± 4.5 months vs. 11.9 ± 3 months in, respectively, ISD alone and ISD + triamcinolone (p=0.16). Both studies reported no complications related to triamcinolone ointment [236, 237].

In a small (n=28) cohort with LS-related strictures, an intra-urethral steroid regimen was successful (no need for subsequent escalation of therapy) in 25 (89%) patients after a mean follow-up of 25 months [157]. This regimen consisted of applying clobetasol cream 0.05% as lubricant on a calibration device (10-16 Fr catheter or dilator) twice a day during a minimum of two months. As most of these patients further continued with instillation of steroids on a calibration device, this high "success" rate must be viewed with caution and should be considered as a stabilisation of the stricture rather than a cure. Eventually, twelve (42.8%) patients could reduce the interval of instillation/dilatation and three (10.7%) of them could finally stop the treatment [157].

Summary of evidence	**LE**
Stricture recurrence was reduced in men performing intermittent self-dilatation (ISD) versus those who did not.	1a
Intra-urethral corticosteroids in addition to ISD delays the time to recurrence.	1a

Recommendations	**Strength rating**
Perform intermittent self-dilatation (ISD) to stabilise the stricture after dilatation/direct vision internal urethrotomy if urethroplasty is not a viable option.	Weak
Use intra-urethral corticosteroids in addition to ISD to stabilise the urethral stricture.	Weak

6.2.3.2 Intralesional injections

The rationale of adjuvant intralesional injections is to reduce fibroblast proliferation and excessive urethral scaring [238].

6.2.3.2.1 Steroids

A 2014 SR identified five studies comparing intra-urethral submucosal steroid injection vs. no intra-urethral submucosal steroid injection after DVIU, of which two were RCTs [235]. Meta-analysis of these two RCTs with 57 and 58 patients in, respectively, the steroid and control group showed no statistical difference in recurrence rate (OR: 0.53; 95% CI: 0.25-1.13; p=0.10). Time to recurrence was significantly longer in the steroid group (weighted mean difference = 4.43; 95% CI: 2.77–6.09, p < 0.00001). There were no significant differences regarding adverse events (infection, bleeding, extravasation) between both groups (weighted mean difference = 1.59; 95% CI: 0.71–3.58, p=0.26).

6.2.3.2.2 Mitomycin C

In 2021 a SR and meta-analysis of different adjuncts to minimally invasive treatment of urethral stricture in men, mitomycin C (MMC) was associated with the lowest rate of urethral stricture recurrence (intralesional injection: OR: 0.23, 95% CI: 0.11-0.48; p=<0.001; intraluminal injection: OR: 0.11, 95% CI: 0.02-0.61; p=0.01) [239]. Another SR and meta-analysis in 2021 from Xu *et al*., on the efficacy of MMC combined with direct vision internal urethrotomy, revealed that the effect of MMC was significant in short (≤ 2cm), anterior urethral strictures, in the longer (>12 months) follow-up group [240].

In the absence of well-conducted and adequately powered RCTs along with the lack of standardisation (dose, technique, volume, etc.) in the current literatue, careful clinical review and prospective data collection as part of a clinical trial is advised.

6.2.3.2.3 Platelet rich plasma

Rezaei *et al*., conducted an RCT comparing DVIU + platelet rich plasma (PRP) (n=44) vs. DVIU + saline (n=43) in primary, bulbar strictures < 1.5 cm in length [241]. The two-year stricture-free rate was 78% vs. 56% after DVIU with or without PRP, respectively (p=0.034). Complications were frequent but not significantly different between both groups (DVIU + PRP: 70%; DVIU + saline: 79%). All complications (urethral bleeding, haematuria, urethral pain, pelvic pain, urinary leakage and genitoperineal swelling) were classified as grade 1 according to the Clavien-Dindo system. Further validation of this treatment is needed before general clinical implementation.

Summary of evidence	**LE**
Intralesional injections after direct vision internal urethrotomy (DVIU) might improve stricture-free rates on the short-term compared to DVIU alone. Experience is limited and the use of these drugs are off-label. Significant uncertainty exists about drug, dose, volume and technique.	1a

Recommendation	**Strength rating**
Use intralesional injections only in the confines of a clinical trial.	Weak

6.2.3.3 Urethral stents

Urethral stents are designed with the aim to oppose wound contraction after dilatation or DVIU [242, 243]. Stent insertion is a short procedure (< 60 minutes) that can be done under local or spinal anaesthesia as a "one-day" surgery [242, 244, 245]. Urethral stents are classified as permanent or temporary (removable, after six to twelve months).

6.2.3.3.1 Results

Permanent stainless-steel mesh stents are no longer commercially available. An RCT comparing dilatation/DVIU only vs. dilatation/DVIU followed by temporary stent insertion for bulbar strictures reported a significantly longer stricture-free survival time in favour of dilation/DVIU followed by stent (median 292 vs. 84 days; p < 0.001) [246]. Only 20.6% of patients treated with a stent developed a recurrent stricture within one year vs. 82.8% in the control group. These results are corroborated by a prospective series of Wong *et al*., who found a median stricture-free survival of two months after DVIU alone vs. 23 months after DVIU followed by temporary (three months) stent for bulbar strictures [243].

Failure and need for re-intervention are frequent (30-53%) and are usually because of stricture recurrence, stent encrustation, stent migration and urethral hyperplasia. Other complications include recurrent UTI, recurrent haematuria and genito-perineal pain (Table 6.5). Although stents are mainly used to treat bulbar strictures, they have been used for posterior stenoses as well. Stents used in the posterior urethra have a high risk (82-100%) of causing UI and this is most pronounced in patients with previous irradiation and/or strictures extending into the membranous or bulbar urethra [247]. In the bulbar urethra, the risk of UI is higher if stent placement is adjacent to the external sphincter [248]. The use of stents in the penile urethra is anecdotal. Jung *et al*., reported stent failure in 4/7 (57%) patients with a penile stricture after a mean follow-up of eight months. Of those patients who failed, no patient with distal or pan-penile strictures was rendered stricture-free [249]. In their series, stricture recurrence after stenting of the penile urethra was significantly higher when compared to the bulbar urethra [249]. Although no direct comparison is available, temporary stents tend to have fewer and less severe complications compared to permanent stents (Table 6.7).

6.2.3.4 Drug-coated balloon dilatation

Drug (paclitaxel)-coated balloon dilatation (DCBD) after standard dilatation or DVIU aims to reduce scar formation based on its antimitotic action. The ROBUST-3 trial prospectively randomised patients with predominantly bulbar strictures (< 3cm length) and at least two prior failed endoscopic treatments to DCBD (n=79) or standard dilatation/DVIU (n=48) [250]. Anatomic patency (assessed by cystoscopy) at six months was 75% for DCBD versus 27% after standard dilatation/DVIU (p <0.001). Estimated one year-retreatment free survival was 83% versus 22% for respectively DCBD and standard dilatation/DVIU (p <0.001). There were no serious adverse events related to DCBD although patients undergoing DCBD had a higher rate of hematuria and dysuria compared to controls (11.4% versus 2.1%). Paclitaxel was detected in semen up to six months after treatment which urges for contraception if the partner has child-bearing potential. If used, careful clinical review and prospective data collection ideally part of a post marketing registry or clinical trial is advised.

Summary of evidence	LE
Drug (paclitaxel)-coated balloon dilatation is associated with higher anatomic patency rates (at six months) and lower risk of retreatment (at one year) as compared to standard dilatation/DVIU in patients with short (< 3 cm), bulbar strictures that underwent at least two prior failed endoscopic treatments.	1b

Recommendation	Strength rating
Offer drug (paclitaxel)-coated balloon dilatation for a short (< 3 cm) bulbar stricture recurring after at least two prior endoscopic treatments, but only in patients for whom urethroplasty is not an option.	Weak

6.2.3.4.1 Treatment of stent failure

In the case of stent failure, subsequent urethroplasty (usually with stent removal) is possible, but this urethroplasty is very likely to be more complex than it would have been had it been performed initially [251-253]. Due to the fact that the stainless-steel wires are fully embedded into the urethral wall, over time the urethral spongiosum is severely damaged. Horiguchi *et al*., found that a history of urethral stenting was an independent significant predictor of increased stricture complexity (OR: 13.7; 95% CI: 1.7-318.3; p=0.01) and need for more complex urethroplasty (OR: 6.9; 95% CI: 1.1-64.5; p=0.04) [234]. The majority (62%) of patients in this study had a permanent stent which tend to be difficult to remove because they are epithelialised, usually within six months [234]. The type of urethroplasty required depends on the length of the stricture and quality of local tissues [252]. In the majority of cases, it is possible to preserve the urethral plate and to perform a one-stage substitution urethroplasty [251, 252, 254]. The patency rates after different types of urethroplasty vary greatly between 16.7-100% [251-254] and this variation probably reflects variation in complexity of the stricture, rather than that the superiority of one technique of urethroplasty over another (for further information see supplementary Table S6.2). Due to these limitations, the use of stents should be avoided if subsequent urethroplasty is considered [242, 253]. Urethral stents are not a first-line treatment for urethral strictures but can be considered in co-morbid patients who have a recurrent stricture after DVIU/dilatation and are unable to have more complex urethroplasty or who refuse urethroplasty [242, 246, 247].

Summary of evidence	LE
Permanent urethral stents have a high complications and failure rate and make subsequent urethroplasty more challenging if they fail.	3
Stents have a higher failure rate in the penile urethra.	3
Temporary stents after DVIU (direct vision internal urethrotomy)/dilatation at the bulbar urethra prolong time to next recurrence compared to DVIU/dilatation alone.	1b

Recommendations	Strength rating
Do not use permanent urethral stents.	Strong
Do not use urethral stents for penile strictures.	Strong
Use a temporary stent for recurrent bulbar strictures after direct vision internal urethrotomy to prolong time to next recurrence only if urethroplasty is not a viable option.	Weak

Table 6.5: Failure rate and complications associated with urethral stents

Study	Type of stent	Duration	N	FU (months)	Stricture length (cm)	Stricture location	Previous interventions	Failure rate	Defintion failure	Complications						
										UTI	Haematuria	Stent encrustation/ stone formation	Stent migration	Urethral hyper-plasia	Local pain	UI
Abdallah *et al*. [242]	Thermo-expandable nitinol	Temporary	23	17 (6)	3.6 (1.2)	Bulbar	DVIU/ urethroplasty: all	12 (52%)	Need for re-intervention	4 (17%)	3 (13%)	3 (13%)	5 (22%)	2 (8%)	6 (26%)	NR
Jordan *et al*. [246]	Thermo-expandable nitinol	Temporary	63	12	2.7 (1.6)	Bulbar	DVIU only: all	28 (44%)	Inability to pass 16 Fr cystoscope	31 (49%)	10 (16%)	3 (4.7%)	8 (13%)	NR	19 (30%)	12 (19%)
Temeltas *et al*. [245]	Polymer-coated	Temporary	28	29 (7-46)	1.9 (0.5-3.5)	Bulbar	DVIU only: all	10 (36%)	Stricture recurrence on urethroscopy/ graphy, Q_{max} < 15 ml/s, UTI	NR	NR	1 (3.6%)	3 (11%)	NR	0 (0%)	NR
Wong *et al*. [243]	Thermo-expandable nitinol	Temporary	22	23 (9-31)	2.4 (1-4.5)	Bulbar	DVIU only: all	7 (32%)	Inability to pass 17 Fr cystoscope, Q_{max} < 10 ml/s or recurrent obstructive symptoms	0 (0%)	NR	0 (0%)	1 (4.5%)	0 (0%)	0 (0%)	NR
Atesci *et al*. [244]	Thermo-expandable nitinol	Permanent	20	144 (120 -192)	2.5 (0.5-5.5)	Bulbar	DVIU/ urethroplasty: all	6 (30%)	Need for re-intervention	NR	NR	4 (20%)	2 (10%)	0 (0%)	8 (40%)	1 (5%)
Sertcelik *et al*. [248]	Thermo-expandable nitinol	Permanent	47	101 (84-125)	2 (0.5-5)	Bulbar (45), bulbomem-branous (2)	urethroplasty (19%)/ DVIU (64%)/ railroading (17%)	22 (47%)	Need for re-intervention	NR	NR	12 (26%)	2 (4%)	7 (15%)	20 (43%)	9 (19%)
Erickson *et al*. [247]	Self-expandable super alloy mesh	Permanent	38	28 (30)	3 (1.7)	Posterior (prostate cancer related); VAUS 24; prostatic urethra (irradition) 14	DVIU only: all	20 (53%)	Need for re-intervention	7 (18%)	3 (8%)	6 (16%)	NR	NR	6 (16%)	31 (82%)

DVIU = direct vision internal urethrotomy; FU = follow-up; NR = not reported; UI = urinary incontinence; UTI = urinary tract infection; VUAS = vesico-urethral anastomotic stricture; Q_{max}= maximum flow rate.

6.3 Open repairs (urethroplasty): site and aetiology (clinical scenario) treatment options

6.3.1 The role of urethroplasty in the management of penile urethral strictures

Due to the specific aetiology and the associated problems, strictures related to failed hypospadias repair and LS will be discussed separately. However, many series reporting on the outcome of penile strictures have a mixed aetiology also including failed hypospadias repair and/or LS [255, 256]. Due to their specific location, distal penile strictures will be discussed separately.

6.3.1.1 Staged augmentation urethroplasty

Classically called "two-stage" urethroplasty, this approach may become a multi-stage urethroplasty as revision (usually due to graft contracture) after the first stage has been reported in 0-20% of cases [256-259]. Therefore, the term "staged" should be used instead [260]. Revision rates before second stage were 0-20%, stressing that a two-stage urethroplasty might become a multi-stage urethroplasty. In general, reconstructive urologists tend to follow this approach in men with more complex urethral stricture disease (multiple interventions in the past, unfavourable clinical findings such as significant spongiofibrosis or scarring that requires excision, poor quality of the urethral plate). An interval of at least four to six months has been proposed before proceeding to the tubularisation of the urethra, provided that the graft has healed uneventfully [261-263].

A SR by Mangera *et al*., has shown an average patency rate of 90.5% with the use of all types of grafts for staged penile urethroplasties with an average follow-up of 22.2 months [264]. Patency rates of staged oral mucosa graft (OMG) urethroplasty in specific locations vary between 73.3 and 100% [255, 256, 258, 259, 265, 266]. Post-operative urethrocutaneous fistula (UCF) rates were 17.2% and 2.6% in the studies of Ekerhult *et al*., and Joshi *et al*., respectively, and either not reported or unclear in the remaining studies [255, 256].

6.3.1.2 Single-stage augmentation urethroplasty

Single-stage urethroplasty offers the option for reconstruction of the stricture without the need for multiple operations, the associated peri-procedural risks, and the cosmetic and functional implications that by definition follow the first part of staged urethroplasties [267-269]. There is some evidence to suggest a considerable number of patients (50% or more in some studies) who were offered first stage urethroplasty never returned for the second stage because they were either satisfied with their functional status after the first stage (this particularly applied to older men or patients with multiple failed procedures in the past) or they were disappointed with the need for another operation [267, 268].

In the SR of Mangera *et al*., overall patency rate for all types of single-staged graft urethroplasties is 75.7% with an average follow-up of 32.8 months [264].

The patency rate for different one-stage techniques in particular are:

- dorsal OMG (n=320): 63-100% [265, 266, 259, 270-276];
- ventral OMG (n=54): 55-92.6% [265, 277, 278];
- double (dorsal + ventral) onlay with penile/scrotal skin graft /OMG (n=14/8/4): 88.5% [272];
- dorsal penile skin graft (n=44): 62-78% [272, 273];
- penile skin flap (n=367): 67-100% [265, 266, 272-274, 279].

No high-level evidence exists to state that one technique is superior to another, but it seems that the dorsal graft location is more commonly used compared to the ventral one. Mangera *et al*., reported that the patency rate was better with OMG compared to other grafts (mainly penile skin) [264]. Jiang *et al*., showed that combined (dorsal + ventral) BMG onlay had significantly better stricture-free rates for penoscrotal strictures (patency rate 88.9% vs. 60.9% with single-onlay approach); however, follow-up was significantly shorter in the double-onlay group [280]. Few studies have reported dedicated results on sexual function parameters that do not appear to be significantly impaired post-operatively [258, 281].

A critical factor with respect to single-staged procedures is the careful selection of patients, as men with long and complex strictures might not be good candidates for single-stage reconstruction and attempts to offer single-staged operations in these patients might lead to higher recurrence rates. Sometimes, this selection can only be done based on intra-operative findings. Therefore, any scheduled single-staged procedure might be converted into a staged one [267, 282]. Palminteri *et al*., highlighted the fact that single-stage augmentation urethroplasties in men with LS-related strictures enlarge rather than remove the diseased segment of the urethra; therefore, there is always a risk of recurrence in the future [283]. The role of previous interventions (especially multiple urethrotomies or history of previous urethroplasties) remains unclear as several studies on single-staged operations do not provide information on previous procedures, or excluded patients with operations in the past [274, 281]. Although favourable outcomes in patients with previous history

of urethrotomies/urethroplasties were reported by Barbagli and Kulkarni, in the study by Pfalzgraf *et al*., all recurrences post-previous urethroplasty took place in the single-stage group while Ekerhult *et al*., identified prior history of urethral operations as a risk factor for recurrence in the group of single-stage procedures [255, 258, 259, 272]. In addition to previous urethral surgery, high BMI has also been identified as a poor prognostic factor after single-stage penile urethroplasty [255].

6.3.1.3 Anastomotic urethroplasty in men with penile urethral strictures

Historically, the use of anastomotic urethroplasty in the management of urethral stricture disease has been discouraged due to the risk of chordee post-operatively [263, 284]. Nevertheless, it has been performed in selected patients with very short strictures (usually < 1 cm) with 80-93% patency rate, with satisfactory QoL and sexual function and without any case of chordee [285], and with results comparable to augmentation urethroplasty [286].

Summary of evidence	**LE**
Stricture-free rates for single-stage penile augmentation urethroplasties range from 70-100% for dorsal OMG augmentation, 67-100% for penile skin flap (PSF) augmentation, 55-92.6% for ventral OMG augmentation and 62-78% for dorsal SG augmentation. Overall stricture-free rates for staged OMG penile augmentation urethroplasties range from 70-100%.	2b
In staged urethroplasties, an interval of at least four to six months has been proposed before proceeding to the tubularisation of the urethra, provided that the graft has healed uneventfully.	4
The use of anastomotic urethroplasty in the management of urethral stricture disease has been discouraged due to the risk of chordee post-operatively. Anastomotic urethroplasty can be offered in selected cases of very short (< 1 cm), injury-associated penile strictures.	3
In case of adverse intra-operative findings, a single-stage approach might not be feasible and must be converted into a staged approach.	3

Recommendations	**Strength rating**
Offer men with penile urethral stricture disease augmentation urethroplasty by either a single-stage or staged approach taking into consideration previous interventions and stricture characteristics.	Strong
Offer an interval of at least four to six months before proceeding to the second stage of the procedure provided that outcome of the first stage is satisfactory.	Weak
Do not offer anastomotic urethroplasty to patients with penile strictures > 1 cm due to the risk of penile chordee post-operatively.	Strong
Counsel patients with penile strictures that single-stage procedures might be converted to staged ones in the face of adverse intra-operative findings.	Strong

6.3.1.4 Specific considerations for failed hypospadias repair-related strictures

The term "failed hypospadias repair" (FHR) includes a wide range of abnormalities after previous attempts for reconstruction, such as glans deformity, recurrent urethral stricture, glans/urethral dehiscence, UCF and penile chordee [287-289]. The management of FHR is challenging as the urethral plate, penile skin and dartos fascia are often deficient/non-existent. Management of these patients is often made more difficult due to incomplete health records and a lack of critical information (original meatal site, number, and type of previous repairs) [261, 290]. In addition, multiple operations might need to be offered to reach satisfactory outcomes [287]. As a result, FHR should always be considered as a complex condition and it is advised that FHR management takes place in high-volume centres [288, 289, 291, 292].

"Hypospadias cripples" is a term widely used to describe the group of men with multiple previous failed attempts to correct the condition resulting in unfavourable results such as severe scarring, penile deformity and shortening, hair or stones in the urethra, UCF, chordee and functional disorders (e.g., urinary, or sexual dysfunction). This term should be avoided and a more neutral one should replace it as it further stigmatises men with hypospadias who have been shown to have reduced self-esteem and confidence due to unsatisfactory cosmesis, and problematic urinary and sexual function. Moreover, it has been reported that FHR patients experience high rates of disappointment after failure of attempted repair and a sense of helplessness as they are frequently advised that their failed hypospadias is too complex to correct and they should not pursue further repair [288-290, 293, 294].

Two main approaches are applicable: single-stage or staged procedures. In general, it is advised that staged procedures should be followed when the urethral plate is inadequate for a single-stage operation. Surgeons should gain the consent of patients for both types of urethroplasty as the surgical approach might need to be modified intra-operatively, depending on favourable/unfavourable intra-operative findings. Besides poor-quality of the urethral plate, these unfavourable findings include high degree of scarring and presence of concomitant LS, UCF and/or chordee. It is not uncommon for men with FHR to have scarred skin or concurrent LS; thus, skin grafts or flaps should be avoided as the risk of recurrence due to LS is very high (90% in long-term follow-up as reported by Depasquale *et al*.) [39, 295, 296].

Staged repairs (using mainly BMG) reported patency rates ranging from 71-95% [293, 295, 257, 297, 298], while single-stage repairs had patency rates from 80-100% [295, 297, 299-302]. It needs to be highlighted that, as FHR is an umbrella term that covers various clinical conditions apart from urethral stricture disease only (such as UCF, chordee, penile deformity), "success" rates as reported by the authors in their studies do not represent urethral patency rates only. Unfortunately, the number of previous operations is either not reported or refers to the whole FHR study group collectively rather than to the subgroups of staged/single-staged procedures.

A comparative analysis is reported by Barbagli *et al*., in 345 FHR patients at five-year follow-up. Overall failure-free survival rate was 48% for all urethroplasties, and in sub-analysis, staged techniques had significantly lower treatment failure-free survival rates compared to single-stage techniques [303]. However, it is unclear whether these groups were comparable in terms of baseline characteristics such as age, length of stricture, number of procedures, comorbidities etc. [303]. If the patients in the staged group had a more unfavourable background, this on its own could explain the final outcome rather than the surgical approach itself.

Kozinn *et al*., reported a 16% and 14% revision rate after the first and second stage, respectively, and observed that these revision rates were higher in the FHR group compared to non-FHR patients with penile strictures [257]. There is conflicting evidence whether FHR as aetiology is a poor prognostic factor in the outcome of urethroplasty for penile strictures [255, 304-306]. Concomitant UCF can be successfully managed at the same time of urethroplasty [303].

Saavendra *et al*., reported 89.3% stricture-free rate in 56 FHR patients with penile urethral strictures at a median of 21 months follow-up using mainly staged urethroplasty and perineal urethrostomy. Verla *et al*., presented departmental experience with the use of various urethroplasty techniques in a total of 76 FHR patients with penile strictures. Follow-up was long, at a median of 89 months and stricture-free rates ranged from 29% (anastomotic repair) to 90% first stage only of multistage urethroplasty).

For further information see supplementary Table S6.3.

Summary of evidence	**LE**
Men with failed hypospadias repair (FHR) have history of multiple interventions, and poor-quality tissues, and might require complex procedures for a satisfactory functional and cosmetic outcome.	4
Men with FHR may have low self-esteem due to urinary and sexual dysfunction and unsatisfactory cosmesis.	2b
Men with FHR can have scarred penile skin or concurrent lichen sclerosus and outcomes with skin grafts or flaps can be unsatisfactory.	3

Recommendations	**Strength rating**
Men with failed hypospadias repair (FHR) should be considered complex patients and referred to specialist centres for further management.	Weak
Propose psychological and/or psychosexual counselling to men with unsatisfactory cosmesis and sexual or urinary dysfunction related to FHR.	Weak
Do not use penile skin grafts or flaps in failed FHR patients with lichen sclerosus or scarred skin.	Strong

6.3.1.5 Specific considerations for lichen sclerosus-related penile urethral strictures

Given the fact that LS affects the skin, the use of genital skin as a flap or graft is not advised as the risk of disease recurrence has been reported to be high (50-100%) and while most recurrences tend to occur within the first two to three post-operative years, late recurrences have been reported [307].

Main strategies are single-stage or staged oral mucosa graft urethroplasty.

The EAU Urethral Strictures Guidelines Panel conducted a SR [6] to explore the role of single-stage oral mucosa graft urethroplasty in the management of LS-related urethral strictures and to compare its outcomes with alternative management options (surgical dilatations +/- ISD; surgical dilatations + local steroids +/- ISD; staged oral mucosa urethroplasty; penile skin urethroplasty; meatotomy/meatoplasty; urethrotomy [Otis, DVIU]; perineal urethrostomy; urinary diversion [e.g., suprapubic catheterisation]).

In total, fifteen studies met the inclusion criteria, recruiting a total of 649 patients (366 from five non-randomised comparative studies and 283 from ten, single-arm retrospective observational studies). Single-stage OMG urethroplasty resulted in success rates ranging from 65-100% after twelve to 67 months mean or median follow-up. For staged OMG urethroplasty, the most commonly reported comparator, the success rates were somewhat lower and varied between 60-79%. Methodological issues (mainly selection bias) could explain the difference in success rates rather than the intervention itself. Complications were uncommon (0-12%) and mainly comprised Grade 1-3 events.

Due to the overall very poor quality of evidence, the SR did not provide a clear answer as to whether single-stage OMG urethroplasty is superior to other management options, although careful patient selection is highlighted. In the absence of adverse local tissue conditions, a single-stage approach could lead to high success rates with an improvement in voiding symptoms and QoL.

Summary of evidence	**LE**
Lichen sclerosus is a skin condition that can lead to scarring, and recurrence rates after skin graft/flap augmentation urethroplasties have been reported to be high (50-100%).	4
Single-stage oral mucosa graft (OMG) urethroplasty provides patency rates between 65 and 100% and is not inferior to staged OMG urethroplasty.	3

Recommendations	**Strength rating**
Do not use genital skin in augmentation penile urethroplasty in men with lichen sclerosus (LS) related strictures.	Strong
Perform single-stage oral mucosa graft urethroplasty in the absence of adverse local conditions in men with LS related strictures.	Weak

6.3.1.6 Distal urethral strictures (meatal stenosis, fossa navicularis strictures)

Open repair of distal urethral strictures can be in the form of Malone meatoplasty, skin flap meatoplasty or graft (skin [SG]/OMG) urethroplasty.

For short distal meatal strictures, the Malone meatoplasty (dorsal + ventral meatotomy) provides a technique with patency rates up to 100%, while 83% of patients reported satisfaction with the cosmetic results [308].

Skin flap meatoplasty showed excellent patency rates ranging from 90-96% based on three studies comprising 67 patients [309-311]. In addition, based on their results, patient satisfaction with post-operative outcomes and cosmesis was high, there were no cases of ED and functional complaints were minimal (mainly spraying of the urine flow).

Patency rates with the use of grafts (OMG or SG) ranged from 69-91% in 106 patients overall [312, 313, 300]. Where reported, patients were satisfied with cosmesis, and mild spraying of the urine flow self-resolved. Although tubularised grafts in a single-stage procedures are not routinely recommended (see also section 9. Tissue transfer), one series reported an 89.9% patency rate for this approach ("two-in one approach") in selected patients with mainly distal penile strictures [314].

Finally, Daneshvar *et al*., presented a novel transurethral ventral inlay OMG technique and showed excellent stricture-free rates (96%) at short follow-up though (median 16 months).

For further information see supplementary Table S6.4.

Summary of evidence	LE
Post-meatoplasty/urethroplasty patency rates in men with meatal stenosis or fossa navicularis/distal urethral strictures range between 57-100% depending on type of surgical intervention with high patient satisfaction and minimal complications.	3

Recommendation	Strength rating
Offer open meatoplasty or distal urethroplasty to patients with meatal stenosis or fossa navicularis/distal urethral strictures.	Weak

*6.3.2 **Urethroplasty for bulbar strictures***

6.3.2.1 "Short" bulbar strictures

The length of a "short" bulbar stricture is poorly defined. In general, "short bulbar strictures" are those amenable to stricture excision and subsequent tension-free anastomotic repair. The limit is usually around 2 cm [315].

In fit patients, the choice of urethroplasty is between EPA (transecting or non-transecting) and FGU.

6.3.2.1.1 Excision and primary anastomosis

6.3.2.1.1.1 Excision and primary anastomosis with transection of corpus spongiosum (transecting EPA)

Transecting EPA (tEPA) is based on the full thickness resection of the segment of the bulbar urethra where the stricture and surrounding spongiofibrosis is located. Reconstruction is performed by a tension-free spatulated anastomosis.

6.3.2.1.1.1.1 Patency rates

The International Consultation on Urological Diseases (ICUD) performed an extensive review of the literature and reported a composite patency rate of 93.8% for tEPA [316]. Based on this, they endorsed tEPA as treatment of choice for short bulbar strictures if other techniques have an expected patency rate below 90%. However, penile complications were not taken into account for this advice and as discussed below, these are a concern with tEPA.

Prospective data report a patency rate of 88% at twelve months follow-up [315].

Usually, no need for further intervention is used to evidence that the urethra is patent. In the few studies using an anatomic definition for failure (an inability to pass a 16 Fr endoscope) tEPA urethroplasty achieves a similar patency rate, ranging between 85.5-97% [145, 317-319] (Table 6.12). The median time for recurrence after tEPA is between 3.5 and thirteen months [145, 320, 321].

Several authors suggested that tEPA is the technique of choice for short post-traumatic bulbar strictures with complete obliteration of the urethral lumen and full thickness spongiofibrosis [319, 322]. These strictures are a specific entity and usually the result of a straddle injury with complete or nearly complete rupture of the bulbar urethra. These obliterations are predominantly short and can be treated with tEPA yielding a patency rate of 98.5% as reported in the series of Horiguchi *et al*., [323]. They also reported an improvement in erectile function after urethroplasty measured one year post-operatively. Straddle injury (and perineal trauma) are a common aetiology in papers published about tEPA; however, separate data on the outcomes for this specific aetiology is usually lacking.

6.3.2.1.1.1.2 Complications

Nilsen *et al*., conducted an RCT comparing tEPA with FGU for short (< 2 cm) bulbar strictures [315]. Compared to FGU, penile complications were more frequent with tEPA. After three months, worse ejaculation (26%), reduced glans filling (26%), penile shortening (16%) and penile chordee (10%) were significantly more reported with tEPA. After twelve months, reduced glans filling (19%) and penile shortening (26%) remained significantly more reported with tEPA. A scrotoperineal hematoma was significantly more frequent with tEPA compared to FGU (resp. 24 versus 4%). Despite these complications IIEF-5 was not significantly different between both groups at three and twelve months.

These latter complications (as well as ED) might be attributed to complete transection of the corpus spongiosum at the level of the stricture, thereby disrupting the antegrade blood flow of the urethra and corpus spongiosum. To spare this, the non-transecting EPA (ntEPA) has been described [324] and later modified [325].

6.3.2.1.1.2 Non-transecting excision and primary anastomosis

6.3.2.1.1.2.1 Patency rates

Except for straddle injuries that are usually associated with complete obliteration of the lumen and full thickness scarring of the corpus spongiosum [319, 326], ntEPA is a good alternative for short bulbar strictures of all other aetiologies. With median follow-ups ranging between 17.6 and 37.1 months, the patency rates reported are 93.2-99%; with the lack of further intervention as success criteria [322, 327, 328]. Even with the anatomic criteria (16 Fr cystoscopy passage) the success rate achieved was 97.9% at twelve months [319] (see supplementary Table S6.7).

Two comparative analyses evaluated tEPA vs. ntEPA. Waterloos *et al*., reported patency rates of 88.4% and 93.2%, respectively, for tEPA and ntEPA (p=0.33) but with significantly longer follow-up for tEPA (118 vs. 32 months, p < 0.001). Of patients scheduled for ntEPA, 11.1% were converted to tEPA, highlighting that ntEPA is not always possible. Chapman *et al*., using anatomic success criteria (16 Fr cystoscope passage), reported patency in 93.8% of tEPA vs. 97.9% of ntEPA. Follow-up was also significantly shorter at 74.1 (SD: 45.4) months for tEPA vs. 37.1 (SD: 20.5) months for ntEPA (p < 0.001) [319].

6.3.2.1.1.2.2 Complications

When erectile function after urethroplasty was assessed (at six months), ntEPA had significantly lower ED rates (a decrease of > 5 points on the sexual health inventory for men [SHIM] scale) compared to tEPA (4.3 vs. 14.3%, respectively) [319]. Urethral transection performed during tEPA was the only factor associated with sexual dysfunction in a multivariate analysis [319]. Other series reported ED lasting for more than six months in 2-6% of cases after ntEPA [322, 328, 329]. Grade > 2 Clavian-Dindo complications were 3.6-8.1% vs. 4.3-6.8%, respectively, for tEPA and ntEPA, without reaching statistical significance [319, 327].

To date, no trials comparing ntEPA with FGU have been published to report on comparative patency outcomes and complications.

6.3.2.1.2 Free graft urethroplasty

Despite the very high patency rates of EPA, FGU has been performed for short bulbar strictures as well. This is mainly driven by reports of ED after EPA. A meta-analysis of ten papers [340] comparing tEPA with BMG FGU for short strictures, found that tEPA is better than BMG FGU in terms of patency rates (91.5% vs. 70%), whilst BMG FGU has less erectile complications (9% vs. 25%). However, the methodology of this meta-analysis must be disputed as it was performed on cohort studies without risk of bias assessment and without further specification of timing of assessment of ED. On the other hand an RCT comparing tEPA with BMG FGU, found no significantly different patency rates for EPA compared to BMG FGU (88% vs. 87% respectively) and no significant differences in erectile function for tEPA compared to BMG FGU [315]. As mentioned earlier, penile complications were more frequent with EPA.

Dogra *et al*., [283] looked prospectively at sexual function in 87 patients after different urethroplasties (EPA, penile/bulbar substitution) and found a 20% reduction in sexual function in all groups, which resolved after six months.

Details on where to place the graft during FGU are discussed below.

Summary of evidence	**LE**
For short post-traumatic strictures tEPA has good patency rates.	3
For short bulbar strictures not related to straddle injury tEPA, ntEPA and FGU have the same patency rates, but ntEPA and FGU have less erectile dysfunction or penile complications than tEPA.	1b-3*

**LE1b for comparison between tEPA and FGU and LE3 for tEPA versus ntEPA versus FGU.*

Recommendations	Strength rating
Use transecting excision and primary anastomosis (tEPA) for short post-traumatic bulbar strictures with (nearly) complete obliteration of the lumen and full thickness spongiofibrosis.	Strong
Use non-transecting excision and primary anastomosis or free graft urethroplasty instead of tEPA for short bulbar strictures not related to straddle injury.	Weak

6.3.2.2 "Longer" bulbar strictures

6.3.2.2.1 Free graft urethroplasty

For strictures not amenable to EPA, FGU is the technique of choice and buccal mucosa is, at the moment, the most widely used graft. Other grafts (and flaps) are possible and discussed in the tissue transfer chapter. Patency rates of FGU of the bulbar urethra are 88-91% with twelve to 40 months follow-up [264, 330]. There is a suggestion that patency rates deteriorate with time [331].

During bulbar urethroplasty, the bulbospongiosus muscle is usually separated at the midline which may cause damage to the muscle and perineal nerves. This might subsequently provoke post-void dribbling and ejaculation disorders. In order to reduce this, the muscle and nerve-sparing perineal approach has been introduced [332]. Although it is mostly used in graft urethroplasty, this approach is also possible for EPA [333]. Elkady *et al*., [329] randomised 50 patients between a muscle and nerve-sparing perineal approach vs. a classic perineal approach and found no difference in operative time (100 vs. 105 min), but significantly less dribbling (4% vs. 36%, p=0.01), and significantly less ejaculatory changes (8% vs. 40%, p=0.02) in the nerve and muscle-sparing group. Fredrick *et al*., [333] did the same in 50 patients in a multicentric study with bulbar urethroplasty but could not find a statistical difference regarding post-void dribbling and ejaculatory changes. Due to the limited and conflicting evidence, no recommendation can be made about the routine use of nerve and muscle-sparing modification during bulbar urethroplasty.

See supplementary Table S6.8 for further information.

6.3.2.2.2 Augmented anastomotic repair

Augmented anastomotic repair has been described for these strictures. It has been mainly performed in cases where the stricture was just too long (+/- 2-4 cm) for tension-free EPA [334]. It can also be performed for longer strictures with a shorter (nearly) obliterative segment [335]. In this case, only the most obliterative segment is excised, the urethral plate is anastomosed, and the urethra is further reconstructed with an onlay graft [335]. Patency rates after AAR vary between 91.1-91.9% with twelve to 28 months follow-up [334]. The use of this technique has been challenged by Redmond *et al*., who found a 4.8 higher risk of recurrence when AAR was used compared to (dorsal) free graft urethroplasty [336] (see supplementary Table S6.9).

A non-transecting alternative has also been described to overcome the previously mentioned inconveniences related to spongiosal transection (augmented non-transecting anastomotic bulbar urethroplasty [ANTABU]). With this technique, Bugeja *et al*., [337] reported a 100% patency rate in sixteen patients after a median follow-up of thirteen months. One patient (6.7%) suffered permanent ED.

Summary of evidence	LE
For strictures not amenable to EPA, FGU provides an 88-91% patency rate at short to medium follow-up.	1b
Augmented anastomotic repair provides good (88-92%) patency rates for bulbar strictures with a nearly obliterative segment, despite deterioration with time.	3

Recommendations	Strength rating
Use free graft urethroplasty for bulbar strictures not amendable to excision and primary anastomosis (EPA).	Strong
Use augmented anastomotic repair for bulbar strictures not amenable to EPA but with a short, nearly obliterative segment within the whole strictured segment.	Weak

6.3.2.2.3 Location of the graft during urethroplasty for bulbar strictures

The best location for graft positioning into the bulbar urethra remains to be determined. There are many techniques described with ventral, lateral, dorsolateral, or dorsal graft as an onlay or an inlay. Onlay means from the outside onto the urethra, inlay means from the inside after opening the urethra.

Regarding the site of graft placement, the Panel has conducted a SR assessing the literature from 1996 onwards, including studies with at least 20 patients and a minimum of twelve months follow-up [7]. This yielded one RCT, four non-randomised comparative series and 36 case series comprising 3,683 patients. The RCT of Vasudeva *et al*., compared ventral (n=40) with dorsal (n=40) onlay BMG urethroplasty and reported a patency rate of 90-92.5%, respectively at twelve months follow-up (p=0.51) [330]. The non-randomised comparative studies could not identify any significant differences in patency rates for dorsal onlay vs. ventral onlay, dorsal inlay vs. ventral onlay, or dorsal onlay vs. ventral onlay vs. dorsolateral onlay. Case series reported a patency rate of 62.1-98.3% for dorsal onlay, 74.3-94.4% for ventral onlay and 78.4-92% for dorsal inlay. There are no arguments to assume a higher risk of ED with one of the four techniques. Post-void-dribbling was reported in 0-28.1% with dorsal onlay and in 20-21% with ventral onlay. Other complications were also similar in incidence between techniques. Urethrocutaneous fistula and urethral diverticulum were only reported with the ventral onlay technique although this consisted of only two and one cases, respectively.

Double ventral-dorsal onlay, proposed for high-grade/nearly obliterative strictures, yielded a patency rate of 90-91% after 22-33 months follow-up [146, 338].

Summary of evidence	**LE**
Location of the graft has no impact on patency rates.	1b

Recommendation	**Strength rating**
Use dorsal, dorsal-lateral, or ventral approach according to surgical practice, expertise, and intra-operative findings.	Strong

6.3.2.3 Staged urethroplasty for bulbar urethral strictures

6.3.2.3.1 Indications

Staged urethroplasty may be considered when:

- there are locally adverse conditions such as fistula, false passage, abscess, cancer [282, 339, 340];
- there has been a previously unsuccessful complex urethroplasty including failed hypospadias repair [257, 339];
- there is a lack of certainty on behalf of the surgeon regarding the most appropriate form of urethroplasty for the patient [339];
- the stricture is radiotherapy induced [257];
- the stricture is consequent to LS [257] (this is controversial and for some groups LS is a contraindication for a staged urethroplasty [305]; Kozinn *et al*., recommend leaving at least ten months between 1st stage and 2nd stage re-tubularisation in patients with LS to allow graft complication to develop) [257];
- there is severe spongiofibrosis [341].

6.3.2.3.2 Outcomes

Patency rates of 33.3-94.6% at mean follow-up of 11.2-50 months have been described for staged urethroplasty in series which include men with bulbar urethral stricture disease [257, 305, 318, 341-343]. Grafts (mesh graft, preputial skin, oral mucosa) can be used in staged augmentation as well as marsupialisation [318, 341]. In patients affected by LS, a 52.2% patency rate for staged urethroplasty was reported whereas this was 86% for single-stage buccal mucosa urethroplasty ($p < 0.01$) [305]. It is highly likely that different stricture and patient characteristics contributed to the differences reported and this should be kept in mind when interpreting the data. Of note, 19-45.5% of patients planned for staged urethroplasty declined to proceed to 2nd stage re-tubularisation [257, 342].

Early complications after staged procedures include wound dehiscence, UTI, epididymitis, scrotal abscess, and penile numbness. Specific to 2nd stage Johanson urethroplasty UCF occurs in 3-15%. The actual incidence of UCF is probably higher as many small fistulae close spontaneously with conservative management and are not formally reported [305, 318, 341].

Late complications of 1st stage urethroplasty include a need for revision in up to 19% - as a consequence of recurrence of LS in graft(s) (8.8%), graft contracture (6.6%) and stomal stenosis (3.3%) [257]. Late complications of 2nd stage urethroplasty include post-micturition dribble in 14-18%, SUI in up to 16%, penile curvature in up to 9%, ED in up to 4%, urethral diverticulum formation in 1% and cold glans [305, 341, 343]. Stress urinary incontinence, penile curvature and ED appear to be particularly associated with mesh graft stage urethroplasty [341, 343].

After their procedure, 86% and 96.6% of men with, respectively, mesh graft and buccal mucosa graft staged urethroplasty were satisfied. The patient groups included in the review were too small to detect significant differences [341]. All are retrospective series – with heterogenous indications, stricture locations (not exclusively bulbar), stricture lengths and patient groups. It is consequently difficult to draw meaningful conclusions from the little data that are available.

See supplementary Table S6.10 for more information.

Summary of evidence	LE
Staged urethroplasty for bulbar strictures and for strictures involving the bulbar urethra yields patency rates of 33.3-90% depending upon patient and stricture characteristics and patient satisfaction is high with all types of staged urethroplasty.	3
Lichen sclerosus is a relative contraindication for staged urethroplasty in the literature with lower long-term urethral patency rates of 52.2% compared to urethral patency rates of 64.3% in non-lichen sclerosis patients.	3
Up to 45.5% of men elect not to proceed to 2nd stage re-tubularisation after successful 1st stage.	3
Up to 19% of men required revision of their 1st stage urethroplasty.	3

Recommendations	Strength rating
Offer staged urethroplasty to men with complex anterior urethral stricture disease not suitable for single stage urethroplasty and who are fit for reconstruction.	Weak
Do not perform staged bulbar urethroplasty for lichen sclerosis if single stage urethroplasty is possible.	Weak
Consider staged procedure in patients unsure about perineal urethrostomy versus urethral reconstruction.	Weak
Warn men that staged urethroplasty may comprise more than two stages.	Weak

6.3.2.3.3 Risk factors

Much effort has been made in attempting to identify risk factors affecting the success rate of urethroplasties. The evidence is not clear about age, obesity, aetiology or prior radiation or prior surgery. The only clear risk factors in multivariate analysis are the length and the site of the stricture, and success rates are better in shorter or bulbar strictures and worse in longer or penile strictures [317, 344-346]. Patient should be informed about the higher risk in longer and penile strictures.

6.3.2.3.4 Risk factors for adverse outcomes

In four series specifically dedicated to risk factors for failure after urethroplasty using multivariate analysis, there is conflicting evidence about several factors (aetiology, comorbidity, stricture length, prior therapy) that might be predictive for failure after urethroplasty (Table 6.6). Advanced age does not appear to be a risk factor for urethroplasty failure in the majority of studies, with the exception of Viers *et al*., 2017 [347] retrospective case series which found that the risk for recurrence was significantly higher beyond the age of 60 (< 50 yrs 94%, > 70 yrs 74%) in 184 patients having a wide variety of urethroplasties. Previous radiation therapy was also found to be a risk factor for stricture recurrence in both Viers' [347] retrospective case series and Ahyai's 2015 series [348] – with only a 71% patency rate at a median follow-up of 29 months in those with previous radiotherapy. Based on these data, a clear and evidence-based recommendation cannot be formulated.

Table 6.6: Risk factors for failure after urethroplasty based on multivariable Cox regression analyses

Study	N	Population	Comorbidity HR (95% CI)	Length HR (95% CI)	Aetiology HR (95% CI)	Prior stricture therapy HR (95% CI)
Breyer *et al.* 2010 [349]	443	Mixed	NS	NS	NS	Prior DVIU: 1.7 (1.0-3.0) Prior urethroplasty: 1.8 (1.1-3.1)

Kinnaird *et al.* 2014 [350]	604	Mixed	NS	≥ 5 cm: 2.3 (1.2-4.5)	Iatrogenic: 3.4 (1.2-10.0) LS: 5.9 (2.1-16.5) Infectious: 7.3 (2.3-23.7)	NS
Chapman *et al.* 2017 [317]	596	Isolated bulbar strictures	Overall comorbidity: 2.4 (1.1-5.3) Obesity: 2.9 (1.3-6.5)	1.2 (1.1-1.3)	Infectious: 3.7 (1.3-10.6)	NS
Verla *et al.* 2020 [351]	474	Anterior strictures	NS	NS	NS	NS

CI = confidence interval; HR = hazard ratio; LS = lichen sclerosus; N = number of patients; NR = not reported NS = not significant.

6.3.2.4 Management of recurrence after bulbar urethroplasty

Kahokehr *et al.*, [334] followed nearly 400 patients after urethroplasty and found a recurrence rate of 6% (n=25). Ninety-two percent of the failed cases were treated successfully with DVIU and only 8% needed another open reconstruction. However, they did not mention characteristics of the recurrent cases nor the duration of follow-up. Rosenbaum *et al.*, [352] and Javali *et al.*, [353] retrospectively analysed the outcomes of BMG FGU for ReDo urethroplasty in 51 and 21 patients, respectively, using the other cheek as donor side. Patency rates were 82-86%, which is in the range of primary cases.

Vetterlein *et al.*, [354] compared primary (no previous open urethroplasty) vs. ReDo (previous open urethroplasty with BMG) vs. secondary (previous open urethroplasty without use of BMG) cases in a retrospective series of 534 patients with BMG FGU. The patency rates in primary and ReDo cases were comparable (87%) whilst the outcome in secondary cases was worse (71%).

A small series (n=37) reported on the use of EPA for revision surgery after failed urethroplasty in strictures of 2.1 (range 1-3.5) cm length on average. Patency rates using EPA after failed primary EPA (51%) and after any other technique of urethroplasty (49%) were 95 and 94% respectively with a mean follow-up of 30 months [321].

Summary of evidence	**LE**
Buccal mucosa free graft urethroplasty after failed urethroplasty achieves the same patency rates as primary cases.	3

Recommendation	**Strength rating**
Use oral mucosa free graft urethroplasty for ReDo urethroplasty in case the of a long stricture.	Strong

*6.3.3 **Urethroplasty for penobulbar or panurethral strictures***

The possibilities for reconstruction are various and often include combinations of different techniques or grafts other than OMG. The patency rates are usually lower than in shorter reconstructions (Table 6.7). Hussein *et al.*, [355] performed a RCT comparing skin grafts vs. skin flaps in strictures of mean length 15 cm and found no difference in patency rates (72% vs. 79%) or complications.

Warner *et al.*, [305] performed a multi-institutional review in 2015 including 466 patients with stricture length > 8 cm and found an overall patency rate of 77.5%. As discussed previously, Kozinn *et al.*, [257] reported on the outcome of staged urethroplasty in a cohort of which 54.9% had panurethral strictures (Table 6.7).

Kulkarni *et al.*, [356] proposed a one-stage completely perineal approach with invagination of the penis and one-sided urethral dissection. After 59 months the overall patency rate was 83.7% in 117 men with a mean stricture length of 14 cm.

Another option in patients refusing or unfit for complex reconstructive surgery is PU (see section 6.3.4 Perineal urethrostomy).

Table 6.7: Study characteristics and patency rates of series on penobulbar strictures

Author	Study	Length in cm (min, mean, range)	Technique	N	FU months (mean, range)	Patency
Hussein *et al.* 2011 [355]	RCT	NR, 15, 9-21	Skin graft vs. flap	37	36, 12-60	72 vs. 79%
Hussein *et al.* 2016 [357]	Prospective	NR, 8, NR	BM vs. skin dorsal onlay	69	56, NR	90 vs. 84%
Warner *et al.* 2015 [305]	Retrospective review	> 8, 12.5, 8-24	BM/staged/skin	466	20, 12-344	77.5%
El Dahshoury *et al.* 2009 [358]	Retrospective	NR, 18, 15-20	Skin flap	30	24, NR	87%
Mathur *et al.* 2010 [359]	Retrospective	NR, 12, 8-16.5	Tunica albuginea graft	86	36, NR	89%
Meeks *et al.* 2010 [360]	Retrospective	NR, 11, 4-24	Abdominal skin graft	21	28, 11-52	81%
Kulkarni *et al.* 2012 [356]	Retrospective	NR, 14	BM dorsal onlay	117	59, NR	83.7%
Tabassi *et al.* 2014 [361]	Retrospective	NR, 14.4, NR	BM dorsal onlay	117(37)	19, NR	84%
Xu *et al.* 2017 [301]	Retrospective	> 8, 12, 8-20	BM/LM/combination	81	>12, 41, 15-86	83%
Alsagheer *et al.* 2018 [362]	Retrospective	> 8, 11.3	BM onlay vs. skin flap	50	NR, 16, NR	70 vs. 77%
Kozinn *et al.* 2013 [257]	Retrospective	NR, 9.6, 4-17	Staged urethroplasty	91	15, 12-69	90.1%

BM = buccal mucosa; LM = lingual mucosa; FU = follow-up; N = number of patients; NR = not reported; RCT = randomised controlled trial.

Summary of evidence	LE
Publications about panurethral urethroplasties generally come from high volume centres.	4
Different materials and techniques might be needed for reconstruction.	3

Recommendations	Strength rating
Offer panurethral urethroplasties in specialised centres because different techniques and materials might be needed.	Weak
Combine techniques to treat panurethral strictures if one technique is not able to treat the whole extent of the stricture.	Weak

6.3.4 Perineal urethrostomy

6.3.4.1 Indications

Perineal urethrostomy offers a permanent or temporary solution for restoration of voiding in men with complex urethral stricture disease in whom:

- there are no further options to restore urethral patency either due to multiple previous failed urethroplasties [305, 339] or multiple co-morbidities precluding a more expansive surgical undertaking after failed endoscopic management [363];
- there is a lack of certainty on behalf of the surgeon regarding the most appropriate form of urethroplasty for the patient;
- following urethrectomy and/or penectomy for cancer [364].

6.3.4.2 Types of perineal urethrostomy

Johanson described an inverted anterior scrotal funnel PU in 1953. This was later modified by Gil-Vernet and Blandy to utilise a posteriorly based scrotal flap. Both these techniques utilise an inverted U or lambda incision. The Gil-Vernet-Blandy PU has been further modified with the addition of dorsal and/or ventral free OMG augment

to allow use of PU in men with strictures consequent to radiotherapy [365] or LS [259] and/or in men with PU stenosis or stricture extending into the proximal bulbar or membranous urethra ("augmented Blandy") [363].

More recently, the '7 flap' PU utilising a unilateral posteriorly based scrotal flap has been developed for use in the very obese, or in men of all BMI with stricture extension into the proximal bulbar or membranous urethra [366]. Initially this was performed with transection of the distal bulbar urethra but latterly the technique has been modified to a non-transection technique with loop mobilisation of the bulbar urethra ("loop PU") [367]. The "7-flap" utilises a midline incision – which has been shown to have a significantly reduced side-effect profile in terms of superficial wound infection (1.9% c.f. 18.6%) and superficial wound dehiscence (11.9% c.f. 23.3%) than the inverted U or lambda incision [368, 369] and may be associated with improved urethroplasty (and by inference PU) outcomes, at least in the short term (0% failure c.f. 6.2% failure at six months) [368]. Operative time is similar for all types of PU with mean operative time varying between 97.2 minutes to 112 minutes [364, 370].

The utilisation of PU is increasing [371] – constituting 4.5% of 403 procedures for complex urethral stricture disease in a tertiary centre in 2008 and 38.7% in 2017 [372]. Perineal urethrostomy patients are generally older than those having urethroplasty with a median of 62.6 years of age for men having PU in Fuchs *et al*., 2018 series compared with a median of 53.2 years for men having anterior urethroplasty [372]. Between 18.7% and 73.4% of men having staged urethroplasty for complex anterior urethral stricture decline to proceed to 2nd stage re-tubularisation after a successful 1st stage and remain voiding from the PU of their 1st stage urethroplasty [257, 339, 342].

6.3.4.3 Outcomes

6.3.4.3.1 Patency rates

Patency rates of 70-95% at mean/median follow-up of 20–63 months have been described [305, 339, 347, 363-366, 370, 372]. All reports are retrospective series – all of which are heterogenous in terms of indications and patients. There is consequently little data available to determine which is the best technique for PU.

McKibben *et al*., reported a patency rate of 92.9% in 42 patients for "7-flap" PU at median follow-up of 53.6 months, whilst they had a 100% patency rate with loop PU in twenty patients at a median follow-up of thirteen months [367].

Lumen *et al*., in 2015 reported a 74.3% patency rate for Johanson PU compared with an 87.5% patency rate for Gil-Vernet-Blandy PU (p=0.248), but with a significantly longer follow-up after Johanson PU (median 36 vs. nine months) [364]. Barbagli *et al*., published the largest series of PU patients to date – including 173 men (all of whom had been planned to have a staged urethroplasty for their complex anterior urethral stricture disease and 127 [73.4%] of whom declined to proceed with 2nd stage re-tubularisation). The median follow-up in this series was 62 months and the patency rate was 70% - confirming that patency rates for PU (and indeed for all urethroplasty [273, 346]) reduce with time [339].

See supplementary Table S6.11 for further information.

6.3.4.3.2 Complications

Perineal urethrostomy complications occur in 2.5-11.4% of patients and include superficial wound dehiscence, scrotal abscess, UTI and urosepsis, bleeding, and transient scrotal pain and numbness [305, 364, 373]. The majority of complications are Clavien-Dindo grades 1 (2.9-18.8%) and 2 (0-2.9%). Grade 3 complications are rare and only occur in 5.7-6.2%. In the medium-term 22.2-30.8% of men with PU report post-micturition dribble [364].

6.3.4.3.3 Patient reported outcomes

Barbagli *et al*., reported that 168/173 (97.1%) of men were satisfied or very satisfied with the outcome of their Gil-Vernet-Blandy PU and would have the procedure again at median 62 months follow-up. Of these, 166/173 (95.9%) felt they had excellent or good results from their Gil-Vernet-Blandy PU, 145/173 (85%) felt it caused them no problems and 141/173 (82%) felt it caused their partner no problems [339]. The Trauma and Urologic Reconstructive Network of Surgeons (TURNS) collaborative group found no significant change in sexual function and a significant improvement in urinary symptoms following PU in a small group of patients [374], whilst Lumen *et al*., found satisfactory or acceptable International Prostate Symptom Score (IPSS) outcomes in 26/32 (81.25%) of men with Johanson or Gil-Vernet-Blandy PU at a median follow-up of 32 months and nine months, respectively.

McKibben *et al*., found a mean patient global impression of improvement (PGI-I) of 1.3 in nineteen patients with either loop PU or "7-flap" PU [367] at median 31 months follow-up.

6.3.4.3.4 Risk factors for patency failure of the perineal urethrostomy

Lichen sclerosus, trauma and infection urethral strictures have poorer outcomes from PU, with PU patency failure in 36.7-67% at a median 62 month follow-up [339, 373]. Worse outcomes were also observed in patients with previous failed urethroplasty and multiple previous endoscopic and open treatments [339, 364, 365].

Barbagli *et al*., found that stricture length was inversely related to PU patency, as was patient age [339]. Conversely Viers *et al*., found outcomes worsened with age, reporting patency rates of 100% in men < 50 years old compared with 83% in men aged 60-69 years old [347]. Lopez *et al*., found increased risk of PU failure in men with ischaemic heart disease which would be a putative explanation for the age-related worsening of outcomes noted by Viers *et al*., [373].

Failure of PU is most commonly treated with surgical revision of PU using V-Y plasty, augmentation or complete ReDo but can also be managed with periodic dilatation or urinary diversion [339, 363, 364].

For further information see supplementary Table S6.11.

Summary of evidence	**LE**
Perineal urethrostomy provides very good short- and long-term outcomes for men with complex urethral stricture disease.	1a
Perineal urethrostomy (PU) provides very good short and long-term outcomes for men who are unable to have complex reconstruction due to co-morbidities.	2b
All types of PU yield equivalent very good outcomes.	4
Augmented Gil-Vernet-Blandy or "7-flap" PU yield very good outcomes in men with extension of their urethral stricture disease into the proximal bulbar or membranous urethra.	2
"7-flap" PU yields very good results in obese men.	3

Recommendations	**Strength rating**
Offer perineal urethrostomy (PU) as a management option to men with complex anterior urethral stricture disease.	Strong
Offer PU for men with anterior urethral stricture disease who are not fit or not willing to undergo formal reconstruction.	Weak
Choose type of PU based on personal experience and patient characteristics.	Weak
Consider augmented Gil-Vernet-Blandy perineal urethrostomy or "7-flap" PU in men with proximal bulbar or membranous urethral stricture disease.	Weak
Consider "7-flap" urethroplasty in obese men.	Weak

6.3.5 ***Posterior urethra***

6.3.5.1 Non-traumatic posterior urethral stenosis

6.3.5.1.1 Treatment of non-traumatic posterior urethral stenosis

Several treatment modalities including conservative management (see section 6.1 Conservative options), endoluminal, open or minimally invasive surgical procedures are currently available, depending on patient's goals and health status.

6.3.5.1.2 Endoluminal management of non-traumatic posterior urethral stenosis

6.3.5.1.2.1 Dilatation of non-traumatic posterior urethral stenosis

This can be done under loco-regional anaesthesia [375-379]. Dilatation is used for VUAS [375-380] or radiation induced BMS [381] and in the majority of reported cases, patients were not previously treated for their stricture (see supplementary Table S6.12). Patency rates vary widely between 0-89% [117, 375-381]. The risk of *de novo* UI was low (0-11%) and no other complications were reported. It is of note that most series report on visually controlled dilatation [375-379] in VUAS without complete obliteration.

6.3.5.1.2.2 Endoscopic incision/resection of non-traumatic posterior urethral stenosis (Table 6.8)

Incisions can be performed at multiple locations according to surgeon's preference [382]. However, aggressive incisions at the six and twelve o'clock positions should be avoided because of the risk of, respectively, rectal injury and urosymphyseal fistulation [189, 383-385]. The risk of urosymphyseal fistulation is especially a concern after previous radiotherapy [386]. Result of bladder neck incision for VUAS are poorer after radiotherapy [387].

Direct vision internal urethrotomy is mainly performed in patients with primary or recalcitrant VUAS although one series performed it in a mix of patients with VUAS and BNS [388] and two series reported it for radiation-induced BMS [117, 381]. Direct vision internal urethrotomy/dilatation for non-irradiated BMS are usually included in series reporting on anterior strictures (see section 6.2 Male endoluminal treatment of anterior urethral strictures). Patency after a 1st "cold/hot knife" DVIU ranges between 25-80% [375, 376, 380, 382, 388-393]. Laser incision yields a 69-100% patency rate [376, 380, 394, 395]. In a retrospective and unbalanced series, La Bossiere *et al*., found better patency rates for laser incision as compared to dilatation, "cold knife" DVIU and transurethral resection (TUR) [376]. Redshaw *et al*., reported inferior patency rates for "cold knife" incision vs. "hot knife" incision followed by MMC for BNS (50 vs. 63%; p=0.03) [236] (see supplementary Table S6.13).

Urinary incontinence largely varies between 0 and 53% but some series have not assessed urinary continence before DVIU [389, 391]. In series where pre- DVIU continence data were available, *de novo* urinary continence after DVIU ranges between 0% and 10% [375, 380, 390, 392, 394]. Noteworthy, of 21 patients that were incontinent pre-DVIU in the series of Giannarini *et al*., eleven (52%) patients became continent, and eight (38%) patients experienced improvement after DVIU [390]. As most recurrences will occur early [390, 391], it is advised to wait for three to four months after DVIU [382, 391, 396] to proceed with incontinence surgery, if necessary, although others wait for twelve months [397]. The presence of recurrence must be ruled out by cystoscopy prior to incontinence surgery [382, 391, 396, 397].

Another option is to resect the stenosis. Popken *et al*., reported a 47% patency rate with TUR for untreated VUAS and no patient suffered *de novo* SUI [392]. Kranz *et al*., compared the results of TUR in 87 and 60 patients with, respectively, VUAS after RP and BNS after TURP. After a median follow-up of 27 (range: 1-98) months, patency rate was 40.2% for VUAS and 58.3% for BNS (p=0.031). The rate of *de novo* incontinence was significantly higher in patients treated for VUAS compared to BNS (13.8 vs. 1.7%; p=0.011) [398]. There is conflicting evidence whether resection is associated with higher incontinence rate compared to incision. [379, 399] Brodak *et al*., compared TUR by bipolar resection (n=22) with holmium laser incision and vaporisation (n=17). After a mean follow-up of 42 months, two (9.1%) and four (23.5%) patients suffered a recurrence with bipolar and laser resection respectively (p=0.37). After six months, patients treated with bipolar resection had a significant better Q_{max} compared to laser treatment (13 vs. 6.1 ml/s; $p < 0.001$) [395]. Bipolar plasma vaporisation produced an 82% patency rate at a mean 24-month follow-up in 28 patients with VUAS who previously failed endoscopic treatment [400].

Cut-to-the-light technique for a complete obliterative stricture is not advised because of the very-low likelihood of durable patency and for the risk of false passage towards the rectum [396, 401, 402].

Repeat DVIU was often able to stabilise the stricture [117, 375, 376, 381, 388-390, 398], but ultimately 6-10% required urinary diversion [391] or chronic suprapubic cystostomy [381, 388].

Transurethral resection can be performed for prostatic obstruction due to sloughing after high-energy treatments (HIFU, cryoablation) [100]. Transurethral resection for obstructive necrotic debris after radiotherapy is possible but is of limited role. Risk of recurrence is 50% and risk of *de novo* UI is 15-25% [100].

Table 6.8: Results of endoluminal incision/resection for posterior non-traumatic stenosis

Study	Modality	Type	N	Previous treatment (%)	FU (months)	Patency° (%)	Urinary incontinence (%)	Complications (%)
Merrick *et al*. [381]	Dilatation/ "Cold knife" DVIU	Radiation-induced BMS	29	0	NR	69	NR	NR
Sullivan *et al*. [117]	Dilatation (n=15) / "Cold knife" DVIU (n=20)	Radiation-induced BMS	39	0	16 (2-48)	51	11	NR
Brede *et al*. [391]	"Cold knife" DVIU	VUAS	63	Dilation: 33 Incision: 38 Both: 29	11 (1-144)	73	52*	NR
Yurkanin *et al*. [389]	"Cold knife" DVIU	VUAS	61	Dilatation: 100	31 (1-77)	87	12**	NR

Giannarini *et al.* [390]	"Cold knife" DVIU	VUAS	43	0	48 (23-80)	74	0	NR
Ramchandani *et al.* [375]	"Cold knife" DVIU	VUAS	10	0	NR	80	10	0
Hayashi *et al.* [380]	"Cold knife" DVIU	VUAS	6	Dilatation: 100	NR	50	NR	NR
	Holmium laser DVIU	VUAS	3	Dilatation + DVIU: 100	11-37	100	0	NR
Lagerveld *et al.* [394]	Holmium laser DVIU	VUAS	10	None: 40 Endoscopic (dilatation +/- DVIU +/- ISD): 60	18 (3-29)	100	0	0
Ramirez *et al.* [388]	"Hot knife" DVIU	VUAS: 74% BNS: 26%	50	None: 22	16	72	9	NR
Gousse *et al.* [393]	"Hot knife" DVIU	VUAS	15	None	15 (6-26)	80	100***	NR
Bang *et al.* [382]	"Hot knife" DVIU	VUAS	37	NR	13 (2-33)	65	100***	NR
Popken *et al.* [392]	"Cold knife" DVIU	VUAS	6	None	12-72	50	0	NR
	TUR	VUAS	15	None		47	0	NR
Kranz *et al.* [398]	TUR	VUAS	87	NR	27 (1-98)	40.2	13.8	NR
	TUR	VUAS	60	NR		58.3	1.7	NR
Brodak *et al.* [395]	TUR (bipolar)	BNS	22	DVIU: 45	42 (14-72)	91	NR	NR
	Holmium laser DVIU	VUAS	17	DVIU: 12		76	NR	NR
Ozturk *et al.* [400]	TUR (bipolar)	VUAS	28	Dilatation: 75 DVIU: 25	24 (6-66)	82	0	0
LaBossiere *et al.* [376]	Holmium laser DVIU	VUAS	70	NR	10	69	NR	NR
	"Cold knife" DVIU	VUAS	8	NR		25	NR	NR
	TUR	VUAS	36	NR		39	NR	NR

BNS = bladder neck stenosis; DVIU = direct vision internal urethrotomy; FU = follow-up;
ISD = intermittent self-dilatation; NR = not reported; TUR = transurethral resection;
VUAS = vesico-urethral anastomosis stricture.
°patency rate after 1st endoluminal treatment evaluated in the study.
** requiring incontinence surgery (artificial urinary sphincter or male sling).*
*** slightly problematic urinary incontinence by questionnaire post DVIU (no data on pre DVIU continence).*
****all incontinent pre-operatively.*

6.3.5.1.2.3 Post-dilatation/direct vision internal urethrotomy strategies for non-traumatic posterior urethral Stenosis

6.3.5.1.2.3.1 Intermittent self-dilatation for non-traumatic posterior urethral stenosis

As for anterior strictures, ISD can be offered to patients for recurrent posterior stenosis after dilation/DVIU to stabilise the stenosis. This is especially relevant for patients unfit/unwilling to undergo surgery or in patients with radiation-induced BMS [117, 376, 381, 403]. Although ISD may be acceptable to many urologists and patients, it usually is associated with a reduced QoL and poor patient compliance [33].

6.3.5.1.2.3.2 Intralesional injections for non-traumatic posterior urethral stenosis

In order to stabilise the luminal fibrosis and consequently to reduce the risk of recurrence, injection of antifibrotic agents at the time of endoluminal treatment has been proposed. The majority of patients in these studies were patients with recalcitrant/recurrent non-obliterative VUAS/BNS. Two series used corticosteroids [379, 396], whilst the others used MMC [397, 401-405]. Patency rates with corticosteroid injections range between 50-100% [379, 396]. Patency rates with MMC vary between 50-94% [397, 404-406]. No trials comparing endoluminal treatment with or without adjuvant intralesional injections were identified.

See supplementary Table S6.13 for further information.

Complications are low across most studies, but all studies were retrospective in nature. Redshaw *et al*., also reported grade 3 complications in four out of 55 (7%) patients, including osteitis pubis (n=2), bladder neck necrosis (n=1) and rectourethral fistula (n=1) in one multi-institutional study [404]. Three of these patients ultimately required urinary diversion, with additional faecal diversion in one patient [404]. Given the severity of these complications, although rare, MMC should not be used outside the framework of a clinical trial [407].

6.3.5.1.2.3.3 Urethral stent for non-traumatic posterior urethral stenosis

Stents have been used anecdotally in the posterior urethra [247, 248, 376]. Patency rates are relatively low (47-60%) [247, 248, 376] at the cost of a high-risk for UI (19-82%) [247, 248].

Summary of evidence	**LE**
For non-obliterative VUAS and radiation-induced BMS, visually controlled dilatation and DVIU yield a patency rate of respectively 0-89% and 25-100% with a low complication rate. It can be performed under loco-regional anaesthesia.	3
During DVIU, deep incision might provoke injury to the rectum at the six o' clock position and might provoke uro-symphyseal fistulation at the twelve o'clock position.	3
For BNS, TUR and "hot-knife" incision yield a patency rate of respectively 58.3 and 72% with a low complication rate.	3
Repeat endoluminal treatments in non-obliterative VUAS, radiation-induced BMS or BNS can stabilise the posterior stenosis and are easy to perform compared to reconstructive surgery.	3
Any form of endoluminal treatment might be associated with *de novo* UI (up to 25%) or worsening of existing UI (up to 15%).	3
Vesico-urethral anastomosis stricture, BMS and BNS with complete obliteration are not included in present series and endoluminal treatment is unlikely to be successful.	3
Urethral stents at the posterior urethra have a rather low patency rate (47-60%) and incontinence rate (19-82%).	3

Recommendations	**Strength rating**
Perform visually controlled dilatation or direct vision internal urethrotomy (DVIU) as 1st line-treatment for a non-obliterative vesico-urethral anastomosis stricture (VUAS) or radiation-induced bulbomembranous strictures (BMS).	Weak
Do not perform deep incisions at the six and twelve o' clock position during DVIU for VUAS or radiation-induced BMS.	Strong
Perform transurethral resection (TUR) or "hot-knife" DVIU as 1st line-treatment for patients with non-obliterative bladder neck stenosis (BNS) after surgery for benign prostatic obstruction.	Strong
Perform repeat endoluminal treatments in non-obliterative VUAS or BNS in an attempt to stabilise the stricture.	Weak
Warn patients about the risk of *de novo* urinary incontinence (UI) or exacerbation of existing UI after endoluminal treatment.	Weak
Do not perform endoluminal treatment in case of VUAS, BMS and BNS with complete obliteration.	Strong
Do not use stents for strictures at the posterior urethra.	Weak

6.3.5.1.3 Lower urinary tract reconstruction for non-traumatic posterior urethral stenosis

If endoluminal treatment (repeatedly) fails or in case of a completely obliterated posterior stenosis [401, 402, 408, 409], lower urinary tract (LUT) reconstruction may be considered in fit patients motivated to undergo surgery (Figure 6.1). The choice of LUT reconstruction will depend upon the length, location, calibre and aetiology of the stenosis, continence status, bladder function, previous radiotherapy, patient's preference, and surgeon's expertise.

Figure 6.1: Options for lower urinary tract reconstruction of non-traumatic posterior urethral obstruction (stenosis/stricture)

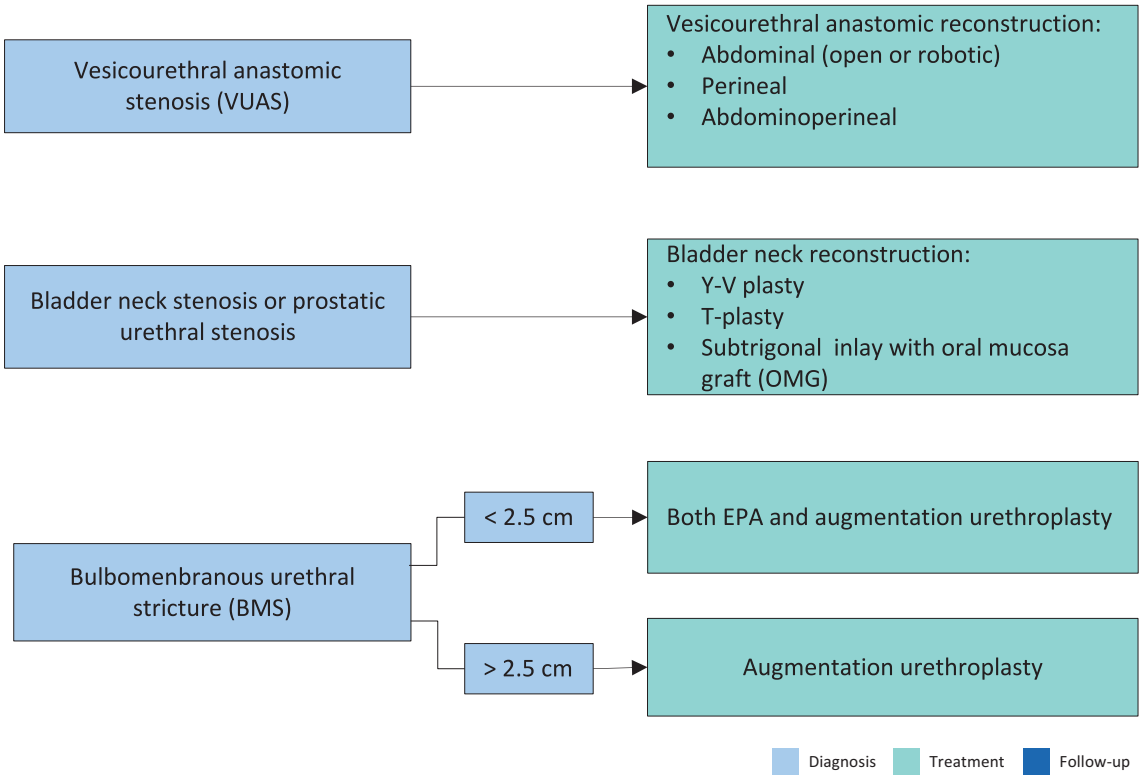

6.3.5.1.3.1 Redo vesico-urethral anastomosis for vesico-urethral anastomotic stenosis after radical prostatectomy

After excision of the stenosis, ReDo vesico-urethral anastomosis (ReDo VUA) can be performed. This may be performed via a retropubic, perineal, combined abdominoperineal or robot-assisted approach. Nikolavsky *et al*., proposes a retropubic approach for VUAS involving the bladder neck, a perineal approach for short VUAS with intact bladder neck and an abdominoperineal approach for long segment (> 3 cm) VUAS with bladder neck involvement [408]. The ReDo VUA must be performed in a tension-free fashion which can be achieved either by mobilisation of the bladder (retropubic approach), mobilisation of the bulbar urethra with corporal splitting and inferior pubectomy if necessary (perineal approach) or both (abdominoperineal approach) [408, 410]. Dinerman *et al*., reported a robot-assisted abdominoperineal approach in a case with 4.5 cm long complete obliteration [411]. Kirshenbaum *et al*., reported a pure robot-assisted abdominal approach. Regardless of the approach, the procedure is technically demanding due to the location deep under the pubic symphysis, and the proximity of the external sphincter [410]. As a consequence, surgical morbidity must be considered. As most patients with VUAS were healthy enough to undergo RP, most patients will likewise remain fit and eligible for VUAS surgical reconstruction [408, 410].

Table 6.9: Outcomes of redo vesico-urethral anastomosis

Study	N	Approach (%)	Previous RT (%)	FU (months)	Length (cm)	Patency (%)	Incontinence (%)	Complications (%)
Nikolavsky *et al*. [408]	12	Perineal: 25 Abdominal: 67 Abdominoperineal: 17	25	76 (14-120)	2.5 (1-5)	67	58	Persistent extravasation due to anastomotic dehiscence grade 3b: 8.3 (prior RT)
Mundy *et al*. [410]	17	Transperineal	0	NR	NR	88	100	NR
	6		100	NR	NR	67	100	NR
Schuettfort *et al*. [412]	22	Transperineal	0	45 (4-77)	NR	91	100*	Rectal injury: 4 Lower leg paresthesia: 4
	1		100		NR	0	100*	

Pfalzgraf *et al*. [413]	20	Retropubic	NR	63 (15-109)	NR	60	65**	UTI: 5 Fever: 5 Renal failure: 5 (all grade 2)
Giudice *et al*. [414]	10	Perineal: 5 Abdominal: 4 Combined: 1	NR	30 (4-106)	NR	80	70	NR
Dinerman *et al*. [411]	1	Robot-assisted abdominoperineal	0	12	4.5	100	0***	0
Kirshenbaum *et al*. [409]	5	Robot-assisted abdominal (±VY-plasty)	0	14 (5-30-)	NR	60	0	Pubovesical fistula: 20 grade 3b

FU = follow-up; NR = not reported; RT = radiotherapy; UTI = Urinary tract infection.
** incontinent before ReDo VUA.*
*** de novo incontinence in four out of eleven patients.*
****social continent (1 pad/day).*

ReDo VUA in non-irradiated patients yields patency rates of 60-91% (Table 6.9) [408-410, 412-414]. Prior radiotherapy is a risk factor for failure [410, 412]. In addition, radiation-induced bladder toxicity might provoke reduced bladder capacity, low bladder compliance, bladder spasms and pain, and urethral necrosis making reconstruction futile (see below) [386, 410, 415]. ReDo VUA should only be done in patients with adequate bladder function and in the absence of (peri)-urethral pathology (urethral necrosis, calcification, fistulation). Flaps (gracilis flap, peritoneal flap) to support and protect the anastomosis may be beneficial in irradiated patients [408].

With the transperineal approach, UI is inevitable, as this approach disrupts the external sphincter [409, 410, 412, 414]. With the retropubic approach, Pfalzgraf *et al*., reported *de novo* incontinence in only four out of eleven (36%) patients [413]. In the series of Nikolavsky *et al*., where a retropubic approach was predominantly used, incontinence rate was 58% [408]. Kirshenbaum *et al*., reported no incontinence in five patients treated by robot-assisted retropubic approach [409]. Giudice *et al*., reported incontinence in one out of four patients treated with the retropubic approach [414]. Therefore, some authors [100, 408, 409] have proposed a preference for the retropubic approach in patients with good pre-operative urinary continence, although both approaches have never been directly compared for UI. In addition, the lack of perineal dissection by a retropubic approach will preserve the perineal anatomy and vascularisation which makes subsequent artificial urinary sphincter (AUS) less demanding [409]. Artificial urinary sphincter implantation should be deferred because of the risk of VUAS recurrence and difficulty of treating any recurrent VUAS with the cuff of the AUS in place [391, 410]. The exact timing of AUS placement is not consensual in the literature but most advise waiting at least three to six months to ensure stability of the VUA patency [386, 407, 410, 412].

Due to the complexity of this pathology the EAU Urethral Strictures Panel advises that VUAS reconstruction should be performed only in experienced high-volume centres, particularly after prior radiotherapy or other energy ablative treatments.

Summary of evidence	**LE**
ReDo VUA has patency rates of 60-91% in non-irradiated patients and 67% in irradiated patients with obliterative VUAS or VUAS refractory to endoluminal treatment.	3
Urinary incontinence is inevitable after transperineal ReDo VUA. Artificial urinary sphincter placement can be offered after three to six months if patency of ReDo VUA is ensured.	3
De novo incontinence with retropubic ReDo VUA is 0-58%.	3

Recommendations	Strength rating
Perform ReDo vesico-urethral anastomosis (VUA) in non-irradiated patients and irradiated patients with adequate bladder function with obliterative vesico-urethral anastomosis stricture or vesico-urethral anastomosis stricture refractory to endoluminal treatment.	Weak
Warn patient that urinary incontinence (UI) is inevitable after transperineal ReDo VUA and that subsequent anti-UI surgery might be needed in a next stage, after at least three to six months.	Strong
Offer ReDo VUA by retropubic approach if the patient is pre-operatively continent.	Weak

6.3.5.1.3.2 Posterior stenosis after surgery for benign prostatic obstruction

6.3.5.1.3.2.1 Bladder neck reconstruction for bladder neck stenosis after surgery for benign prostatic obstruction

The bladder neck is augmented by advancement of local bladder flaps (Y-V or T-plasty) with or without resection of scar tissue. They are used for BNS refractory to endoscopic treatments [409, 416-418]. Patency rates vary between 83-100% with fourteen to 45 months follow-up [409, 416-418]. There is a trend to perform bladder neck reconstruction by minimally invasive approach (laparoscopic, robot-assisted) [409, 417, 418]. *De novo* incontinence rate ranges from 0-14% [409, 416-418]. Satisfaction among patient is high with 88.5% of patients stating that they are pleased with the surgery, with an improvement of QoL in 75% of patients [416, 418]. Recently, a robot-assisted augmentation technique with subtrigonal buccal mucosa inlay has been successfully reported in a case report, but this technique requires further investigation [419].

See supplementary Table S6.14 for further information.

6.3.5.1.3.2.2 Bulbomembranous strictures after surgery for benign prostatic obstruction

Bulbomembranous urethral strictures (BMS) after TURP or simple prostatectomy are managed as bulbar strictures and can be treated by EPA or augmentation urethroplasty with a graft, taking into account the length and tightness of the stricture [82]. Kulkarni *et al*. reported a similar patency rate for dorsal and ventral onlay urethroplasty (resp. 81.8% versus 84.6% after mean follow-up of 14 months) [420]. As reconstruction is in the proximity of the external sphincter and the bladder neck was already damaged during BPO surgery, the risk of incontinence (up to 25%) is present [82].

Summary of evidence	LE
Bladder neck reconstruction with Y-V or T-plasty for treatment refractory BNS has patency rates of 83-100%.	3
Incontinence occurs in up to 14% with bladder neck reconstruction and up to 25% after reconstruction of BMS after previous surgery for BPO.	3

Recommendations	Strength rating
Perform bladder neck reconstruction with Y-V or T-plasty for treatment refractory bladder neck stenosis (BNS).	Weak
Warn patients about *de novo* urinary incontinence after reconstruction for BNS or bulbomembranous urethral strictures with previous benign prostatic obstruction surgery as aetiology.	Strong

6.3.5.1.3.3 Radiation/high-energy induced posterior strictures

6.3.5.1.3.3.1 Bulbomembranous strictures secondary to radiation/high energy sources

The major challenge in treating radiation-induced strictures is the consequent tissue damage with impaired healing capacity, involving not only the stricture itself but also the adjacent proximal and distal areas of the scar [421]. Additionally, proximity of the stricture to the external sphincter can further complicate surgery [421]. Due to these challenges, patients with radiation-induced BMS have long been considered poor candidates for urethral reconstruction and have been treated with urinary diversion if endoscopic treatments failed or were not possible [421].

Most radiation-induced BMS are short and in these cases, EPA is possible avoiding the use of a graft or a local flap in an area of poor vascular health. However, EPA will not be possible for BMS with a long bulbar segment and in these cases, augmentation urethroplasty will be necessary despite the aforementioned concerns. A

systematic review reported a pooled patency rate of 80% with no significant differences between type of urethroplasty (EPA versus augmentation urethroplasty). Stress UI was reported in 19% of cases [421]. Rourke *et al*., reported no significant differences between EPA and augmentation urethroplasty regarding *de novo* UI (26 vs. 25%; p=1), new onset ED (35 vs. 0%; p=0.06) or other adverse events (30% vs. 33%; p=1) [422].

6.3.5.1.3.3.2 Prostatic strictures secondary to radiation/high energy sources

Radiotherapy and high-energy modalities (cryoablation, HIFU) might provoke prostatic necrosis, sloughing and obstruction [100]. Cases refractory to TUR and with good bladder capacity might be salvaged by prostatectomy taking into account the morbidity associated with salvage RP (rectal injury, VUAS, incontinence) [100, 423]. Mundy *et al*., treated nine patients with patency in six, (67%) and one (11%) needing an AUS for severe incontinence [410].

Cases with impaired bladder function, urethral necrosis and/or peri-urethral pathology should be considered for supravesical diversion, especially if a suprapubic catheter is not tolerated due to bladder pain or spasms [386, 407, 410, 415].

Recently, a "pull-through" procedure has been reported as an alternative to cutaneous diversion for reconstruction of the devastated posterior urethra associated with a defunctionalised bladder after radiation where tissue vascularity and quality is poor [424]. This novel technique of total LUT reconstruction combines salvage cystectomy, ileal neobladder formation and urethral pull-through. An AUS was implanted in a second stage. All eight patients maintained a patent posterior urethra after a median follow-up of 58 (range 16-84) months. Five patients experienced low-grade complications after the first stage, but no high-grade complications were reported. Four out of eight (50%) patients experienced cuff erosion with need for removal and subsequent reimplantation. After a median of two revision surgeries (range 0 to 4), all patients achieved social continence enhancing QoL [424]. This technique requires further validation before its use can be recommended.

Summary of evidence	**LE**
Patency rates of urethroplasty for radiation-induced BMS is 80% with no significant differences between EPA and augmentation urethroplasty.	3
Radiation-induced BMS longer than 2-2.5 cm are rarely amenable for EPA.	3
De novo incontinence and new onset ED after urethral surgery for radiation-induced BMS are reported in respectively 19-26% and 0-35% of cases.	3
Salvage prostatectomy can achieve patency in 67% of patients for prostatic strictures after irradiation or high-energy treatments but morbidity is substantial.	4

Recommendations	**Strength rating**
Use either excision and primary anastomosis (EPA) or augmentation urethroplasty for short (< 2.5 cm) radiation-induced bulbomembranous strictures (BMS) refractory to endoscopic treatment depending on surgeon's experience.	Weak
Perform augmentation urethroplasty for long (> 2.5 cm) radiation-induced BMS.	Weak
Warn patients about the risk of *de novo* incontinence and new onset erectile dysfunction after urethroplasty for radiation-induced BMS.	Strong
Offer salvage prostatectomy in motivated and fit patients with adequate bladder function in case of a prostatic stricture due to irradiation or high-energy treatment.	Weak

6.3.5.1.4 Extirpative surgery and urinary diversion for non-traumatic posterior urethral stenosis

In complex and/or recurrent cases [408], LUT reconstruction is not possible or not indicated due to severe necrosis, calcification and significant morbidity, especially severe pain [407]. Intractable haematuria or fistulation might be other reasons to abandon the urethral outlet. Typically, the patient has a history of pelvic irradiation or high energy prostate cancer treatment and several previous attempts to achieve cure. Moreover, and equally important, any of the options used to deal with a devastated posterior urethra are dependent upon good bladder capacity, compliance and function allowing for bladder preservation as well as healthy distal ureters [386, 407]. The last resort therapeutic option is urinary diversion (continent or incontinent) with or without cystectomy [410, 415]. Different techniques have been described and the choice between them largely

depends on the bladder capacity, presence of local symptoms, performance status and expectations of the patient. Cystectomy during urinary diversion is able to palliate symptoms of intractable bladder pain, spasms and haematuria which are especially prevalent after pelvic radiotherapy [425-428]. The satisfaction rate was reported to be 100% and the overwhelming majority of patients would have undergone this extirpative surgery an average of thirteen months sooner in a study of fifteen patients by Sack *et al*. [429]. In a report by Faris *et al*., 27% of the patients also required bowel diversion due to intractable gastrointestinal morbidity, highlighting the complexity of this pathology [415].

Summary of evidence	**LE**
Urinary diversion can improve QoL in patients with a devastated lower urinary tract with a high satisfaction rate.	3
Cystectomy is able to palliate symptoms of intractable bladder pain, spasms, and haematuria.	3

Recommendations	**Strength rating**
Perform urinary diversion in recurrent or complex cases with loss of bladder capacity and/or incapacitating local symptoms.	Weak
Perform cystectomy during urinary diversion in case of intractable bladder pain, spasms and/or haematuria.	Weak

6.3.5.2 Post-traumatic posterior stenosis

The acute and early management of PFUIs is discussed in the EAU Guidelines on Urological Trauma. A nonobliterative stenosis is the result of a partial injury at the membranous urethra or occurs after unsuccessful early realignment of a partial or complete injury. An obliterative stenosis is the consequence of a complete injury with a distraction defect between the ruptured urethral ends. The gap between these ends fills up with dense fibrotic tissue [11].

The deferred management of PFUI is at earliest three months after the trauma. After that period, the pelvic haematoma has nearly always resolved, the prostate has descended into a more normal position, the scar tissue has stabilised [430] and the patient is clinically stable and able to lie down in the lithotomy position [430].

6.3.5.2.1 Endoluminal treatment for post-traumatic posterior stenosis

6.3.5.2.1.1 Endoluminal treatment as primary treatment for post-traumatic posterior stenosis

Endoluminal treatment (dilation, DVIU) of an obliterative stenosis using the cut-to-the light principle will not be successful [46] and has a risk of creating a false passage towards the bladder base or rectum [431]. For a non-obliterative, short (< 1.5 cm) stenosis, one attempt of endoluminal treatment (endoscopic incision or dilation) can be performed. Kulkarni *et al*., reported a 92.3% and 96.5% stricture-free rate with "cold knife" and holmium laser urethrotomy, respectively (median follow-up respectively 61 and 57 months) [432]. These results are challenged by Barbagli *et al*., who reported a 51% stricture-free rate with holmium laser urethrotomy but with no data on length of follow-up available [433]. Cai *et al*., compared patient outcomes between bipolar plasma vaporisation and "cold knife" DVIU in 53 patients with posterior traumatic (80%) and iatrogenic (20%) urethral strictures with significantly different stricture-free rates of 81.5% vs. 53.8% at a mean follow-up of 13.9 months, respectively [434]. No severe complications were reported in either group. A statistically significant shorter operative time was found in the bipolar group [434]. Barratt *et al*,. calculated a composite stricture-free rate of 20% after all types of endoscopic treatments (but with a mix of obliterative and non-obliterative stenoses) [46]. *De novo* UI was reported in 4% of cases [46]. Repetitive endoluminal treatments are unlikely to be curative and must be discouraged as this delays the time to definitive cure and can lead to more complications [435, 436].

6.3.5.2.1.2 Endoluminal treatment after failed urethroplasty for post-traumatic posterior stenosis

In case of a non-obliterative and short (< 1 cm) recurrence after failed urethroplasty, endoluminal treatment can be performed [437]. Although a 1st and 2nd DVIU can be successful with a stricture-free rate of 22.9-77.3% and 0-60% respectively, three or more incisions are never successful (see supplementary Table S6.16) [437-440]. Therefore, repetitive endoluminal treatments (dilations and/or endoscopic incisions) can only be considered as a palliative option [441].

Summary of evidence	LE
Endoluminal treatment of obliterative stenoses is not successful and may create false passages towards bladder or rectum.	3
A 1st DVIU has stricture-free rates of 22.9-77.3% for a short and non-obliterative recurrence after excision and primary anastomosis.	3
Three or more endoscopic incisions are never successful for recurrence after excision and primary anastomosis.	3

Recommendations	Strength rating
Do not perform endoscopic treatment for an obliterative stenosis.	Strong
Perform one attempt at endoluminal treatment for a short, non-obliterative stenosis.	Weak
Do not perform more than two direct vision internal urethrotomies and/or dilatations for a short and non-obliterative recurrence after excision and primary anastomosis for a traumatic posterior stenosis if long-term urethral patency is the desired intent.	Weak

6.3.5.2.2 Urethroplasty for post-traumatic posterior stenosis

In view of the complexity and difficulty of urethroplasty and the fact that the best results are obtained with its first attempt, this surgery must be performed in high-volume centres [442]. It has been calculated that to achieve and maintain sufficient experience in the reconstruction of PFUI, one centre per twelve million inhabitants is sufficient (for well-resourced countries) [443].

6.3.5.2.2.1 First urethroplasty for post-traumatic posterior stenosis

6.3.5.2.2.1.1 Indication and technique of urethroplasty for post-traumatic posterior stenosis

Progressive perineal EPA is the standard treatment for an obliterative stenosis and for a non-obliterative stenosis as first attempt, or after failure of primary endoluminal treatment [46, 444].

Although both a midline and inverted U-incision are possible to gain access to the posterior urethra, a midline incision is associated with a significant reduction in trauma to the superficial perineal and posterior scrotal nerves and vessels, in the rate of surgical site infections (3.1% vs. 16.4%) and reduced length of hospitalisation [369].

A combined transpubic abdomino-perineal approach is only necessary in complicated cases such as those with associated para-urethral bladder base fistula, trauma-related recto-urethral fistula, and bladder neck injury [431]. Total pubectomy during transpubic abdomino-perineal reconstruction has a higher complication rate (bleeding, pelvic instability, dead space) compared to partial (superior or inferior) pubectomy with no gain in surgical exposure [445]. Although also considered complex situations, iatrogenic recto-urethral fistula (after misdirected endoscopic treatment), traumatic recto-urethral fistula < 5 cm from the anus, UCF and urinoma cavity can usually be corrected by a progressive perineal approach only [431, 446].

6.3.5.2.2.1.2 Patency rate after urethroplasty for post-traumatic posterior stenosis

The overall patency rate after deferred EPA is 85.7% [46]. Complete excision of scar tissue is a strong predictor for freedom of stricture whereas number (3-5 vs. 6-7) and size (3.0 vs. 4.0) of sutures are not [447]. A retrospective study showed an improved patency rate after eversion of the urethral mucosa of both urethral ends before anastomosis ("valgus urethral mucosa anastomosis") [448], but this finding has yet to be confirmed in a prospective fashion.

To preserve the antegrade arterial inflow of the bulbar urethra and reduce the surgical trauma of "classic" deferred EPA, bulbar artery sparing EPA has been described [449]. Initial patency rates vary between 88.5-100% with 20-45 months of follow-up (see supplementary Table S6.17) [449-451]. Xie *et al*., only used this technique for distraction defects less than 2.5 cm [451]. No evidence exists to date whether bulbar artery sparing EPA is superior to the "classic" EPA in terms of patency rate and potency and continence rates.

In case of a very deep location of the proximal urethral end that makes anastomotic suturing impossible, Badenoch described a pull-through technique which has a 33.3-96.5% patency rate after 43-126 months of follow-up (see supplementary Table S6.18 for further information) [432, 452, 453]. With the aim to reduce stricture recurrence, Wong *et al*., advise a 1.5 cm segment overlap of the bulbar stump within the prostatic

urethra during the pull-through technique [452]. To facilitate the suturing at the proximal part of the urethra located deep under the pubic bone, the robotic approach is under exploration but there is no evidence so far of improved outcome with this approach [454].

6.3.5.2.2.1.3 Sexual function, urinary continence, and rectal injury after urethroplasty for post-traumatic posterior stenosis

Regarding erectile function, a prospective study by Hosseini *et al*., found no significant difference before, and three or six months after EPA for posterior traumatic stenosis [455]. Another prospective study by Tang *et al*., also demonstrated no significant overall change in ED after urethroplasty. However, in the subgroup of patients with pre-operative non-vascular ED, a significant post-operative increase in ED was observed [456]. A meta-analysis of retrospective studies showed a significant decline of the rate of ED from 43.27% before to 24.01% after posterior urethroplasty ($p < 0.001$) [457]. Assessment of erectile function and its definitive treatment (e.g., penile prosthesis) should be performed two years after the trauma because of the potential return of normal erectile function within that time [458, 459].

After deferred EPA, antegrade ejaculation is present in 98.3-100% of cases [460, 461]. Decreased ejaculatory volume and/or diminished ejaculatory force were reported in 17.2-18.7% of cases but it cannot be assessed whether this is due to the trauma or due to the surgery [460, 461].

Continence after PFUI and urethroplasty is generally attributed to a competent bladder neck [46]. On the other hand, as most ruptures occur at the bulbomembranous junction just below the external sphincteric mechanism, at least a part of the external sphincter mechanism can be spared during urethroplasty [462]. Therefore, incontinence is rare with deferred EPA (6.8-8.5%) and is usually due to incompetence of the bladder neck although an incompetent bladder neck will not necessarily result in incontinence after urethroplasty [46, 462, 463].

Rectal injury is a relatively rare (0-10.2%) but severe complication after deferred EPA (see supplementary Table S6.19) [430, 438, 445, 463-467]. The risk of rectal injury tends to be higher in complicated cases or cases with previous urethral manipulations [430, 468, 469].

6.3.5.2.2.2 ReDo-urethroplasty for post-traumatic posterior stenosis

In case of a recurrent stenosis, a repeat ("ReDo") urethroplasty is possible. In the majority of cases, especially if not all consecutive length-gaining manoeuvres have been used during the 1st EPA, another EPA can be performed [463, 467, 468, 470-472]. The Badenoch pull-through technique is again an option if no adequate mucosa-to-mucosa suturing is possible (See supplementary Table S6.18) [452, 453]. In case of excessive dead space after resection of the fibrosis, gracilis muscle [469] or omental flaps (laparoscopically harvested if urethroplasty was performed using perineal approach only) [431, 465] have been advised to fill up this space and support the anastomosis. These flaps, or alternatively bulbospongious muscle or local subcutaneous dartos flaps, are also useful to separate the suture lines in case of a concomitant recto-urethral fistula [431, 442, 446, 469]. If the urethra cannot be anastomosed in a tension-free fashion, despite the aforementioned manoeuvres, or in cases of ischemic narrowing/necrosis of the bulbar urethra, options are a tubed preputial island flap, staged BMG urethroplasty with flap, staged buccal mucosa dartos flap, radial forearm free flap urethroplasty or entero-urethroplasty [442, 467, 471, 473]. In case of entero-urethroplasty, the sigmoid colon is preferred above ileum (which is in turn better than stomach) because of the proximity of the vascular pedicle to the perineum. Entero-urethroplasty should only be done in the presence of a competent bladder neck because subsequent implantation of an AUS is nearly impossible [473].

Patency rate of different types of ReDo-urethroplasty varies between 50-100% (Table 6.11) [442, 463, 467, 468, 471, 473]. An alternative is to abandon the normal urinary outlet and opt for Mitrofanoff-vesicostomy, PU (if local perineoscrotal skin is suitable) or permanent suprapubic diversion [467, 473].

Table 6.10: Outcome of different types of ReDo-urethroplasty

Study	Type	N	Follow-up (months)	Patency rate
Bhagat *et al*. [471]	Progressive perineal EPA	28	29 (12-108)	36 (83.72%)
	Transpubic EPA	12		
	Tubed preputial flap	1		
	Staged BMG + local flap	2		
Fu *et al*. [468]	Progressive perineal EPA	55	36 (18-47)	33 (60%)

Garg *et al*. [467]	Progressive perineal EPA	40	31 ± 11	30 (75%)
	Transpubic EPA	2	25	2 (100%)
	Tubed preputial flap	1	25	1 (100%)
	Staged BMG + local flap	2	17	1 (50%)
	Radial forearm free flap	1	15	1 (100%)
Sa *et al*. [463]	Progressive perineal EPA	102	35 (6-63)	93 (91.2%)
Kulkarni *et al*. [442]	Progressive perineal EPA	541	68 (12-240)	412 (79.1%)
	Tubed preputial flap	37		30 (81%)
	Staged BMG flap	10		6 (60%)
	Staged BMG + local flap	15		13 (86.6%)
	Entero-urethroplasty	2		2 (100%)
	Radial forearm free flap	3		3 (100%)
	Pedicled anterolateral thigh flap	1		1 (100%)
Mundy *et al*. [473]	Entero-urethroplasty	11	NA	7 (63.6%)

BMG = buccal mucosa graft; EPA = excision and primary anastomosis; N = number of patients; NA = not applicable.

Summary of evidence	**LE**
The best results are obtained after the 1st urethroplasty.	4
The overall stricture-free rate after EPA is 85.7%. By using the progressive perineal approach, a combined transpubic abdomino-perineal approach is usually not needed.	3
After failed endoluminal treatment, EPA is the standard treatment for a non-obliterative stenosis.	3
Both a midline and inverted U perineal incision equally gain access to the posterior urethra, but a midline incision is associated with less anatomical damage to local vessels and nerves, reduced risk of surgical site infection and hospital stay.	2b
Total pubectomy during transpubic abdomino-perineal reconstruction has a higher complication rate (bleeding, pelvic instability, dead space) compared to partial (superior or inferior) pubectomy with no gain in surgical exposure.	4
By using the progressive perineal approach, a combined transpubic abdomino-perineal approach is usually not needed except for very long distraction defects and in case of complicated situations, which include associated para-urethral bladder base fistula, trauma-related recto-urethral fistula, and bladder neck injury.	3
If the urethra cannot be anastomosed in a tension-free fashion or in case of ischaemic narrowing/ necrosis of the bulbar urethra, options are a tubed preputial island flap, staged buccal mucosa graft urethroplasty with flap, staged buccal mucosa dartos flap, radial forearm free flap urethroplasty or entero-urethroplasty.	3
In case of excessive dead space after resection of the fibrosis, local flaps have been advised to fill up this space and support the anastomosis. These flaps are also useful to separate the suture lines in case of a concomitant recto-urethral fistula.	3

Recommendations	**Strength rating**
Perform open reconstruction for post-traumatic posterior stenosis only in high-volume centres.	Weak
Perform progressive perineal excision and primary anastomosis (EPA) for obliterative stenosis.	Strong
Perform progressive perineal EPA for non-obliterative stenosis after failed endoluminal treatment.	Strong
Perform a midline perineal incision to gain access to the posterior urethra.	Strong
Do not perform total pubectomy during abdomino-perineal reconstruction.	Strong

Reserve abdomino-perineal reconstruction for complicated situations including very long distraction defect, para-urethral bladder base fistula, trauma-related recto-urethral fistula, and bladder neck injury.	Weak
Perform another urethroplasty after 1st failed urethroplasty in motivated patients not willing to accept palliative endoluminal treatments or urinary diversion.	Weak
Use a local tissue flap to fill up excessive dead space or after correction of a concomitant recto-urethral fistula.	Weak

7. DISEASE MANAGEMENT IN FEMALES

7.1 Signs and symptoms of female urethral strictures

The symptoms of female urethral strictures are non-specific and therefore generally non-diagnostic. Female urethral stricture presents with mixed filling and voiding symptoms with frequency in 63%, urgency in 55%, incomplete emptying in 36%, poor flow in 32%, urinary incontinence in 31% (stress, urge or mixed), strain void in 21.5%, UTI in 20.5%, nocturia in 20.5%, and dysuria in 20%. It very rarely presents with urethral pain (2.7%), terminal dribble (2%), haematuria (1.6%) or renal failure (0.5%) (see supplementary Table S7.1).

There is often a significant delay in diagnosis of FUS from time of development of symptoms with mean delays of 4.3-12 years described (range 1-30 years) [137].

7.2 Diagnosis of female urethral strictures

Twenty-four studies detail investigations leading to a diagnosis of FUS (see supplementary Table S7.2). In all cases a full history was taken, and a detailed pelvic examination was performed to assess for prolapse, masses, scars and vulval dermatological disorders such as LS, lichen planus or vulvo-vaginal atrophy. Flow rate and US PVR assessment was evaluated in nineteen (75%) and eighteen (71%) studies, respectively. Lateral VCUG was performed routinely in sixteen studies (63%) and as required in one study (4%). Cystourethroscopy was performed routinely in fourteen studies (54%) and as required in two studies (8%). Urodynamics (UDS) were performed routinely in four studies (17%) and as required in seven studies (30%), whilst video-urodynamics (VUDS) were performed routinely in three studies (13%), and urethral calibration in four studies (13%). Pelvic MRI was performed as required in four series (17%), whilst transrectal US (TRUS) and renal US were each performed routinely in two series (8%), and intravenous urography (IVU) in ten (4%).

Flow rate and PVR assessment make inherent sense as initial non-invasive screening tools and allow for simple monitoring of effect of treatment. Voiding cystourethrography and/or VUDS will permit diagnosis of BOO [23, 474], visualisation of ballooning above the proximal end of the FUS [135], and delineation of alternate or co-existent diagnoses such as detrusor overactivity (DO) and SUI [128], although VCUG, VUDS and UDS require the ability to insert a 6 Fr catheter and may not be possible without preliminary urethral dilatation in all cases of FUS [475]. Likewise, passage of a cystourethroscopy will require a preliminary dilation in the majority of cases even when a paediatric uretero-renoscope is utilised [126]. Cystourethroscopy will allow for formal identification of the distal end of the FUS and will also allow for exclusion of a functional cause of BOO [135]. Magnetic resonance imaging is performed mainly to exclude alternate pathology such as urethral diverticulum and urethral carcinoma and also allows assessment of the degree of urethral fibrosis associated with FUS [475]. Proponents of TRUS utilise it in lieu of MRI and also for visualisation of the dilated urethra above the proximal end of the FUS. Recent gel-infused USS has been assessed and found to more accurate means of diagnosing stricture and associated spongiofibrosis than cystoscopy and videourodynamics in a small preliminary study (n=8) [476].

7.3 Treatment of female urethral strictures

7.3.1 Minimally invasive techniques for treatment of female urethral strictures

Several minimally invasive treatments have been reported; these include urethrotomy, dilatation, meatotomy and meatoplasty. Meatotomy and meatoplasty are essentially the same procedure in the female urethra and the term 'meatoplasty' will be used, in the context of female urethral strictures, throughout this document.

7.3.1.1 Urethrotomy for treatment of female urethral strictures

No papers were found detailing the use and outcomes of urethrotomy specifically for the management of FUS. Internal urethrotomy or dilation was used by Massey and Abrams [477] to treat a variety of pathologies,

including FUS, causing symptoms of obstructed voiding, and resulted in symptomatic improvement in 80% of patients. As this study included women with a variety of complaints and did not assess urodynamic parameters, the results in the patient subset with true urethral stricture are unclear. If utilised, urethrotomy in the female urethra involves incisions at three, nine and occasionally twelve o'clock [477].

7.3.1.2 Urethral dilatation for treatment of female urethral strictures

With this treatment, the urethra is dilated to between 24 Fr and 41 Fr. Some patients will continue with ISD. Romman *et al*., 2012 [478] and Popat & Zimmern [475] also described suture plication of bleeding areas of the meatus if required post-urethral dilatation.

Four studies described the results after twelve to 59 months follow-up of, in total, 183 patients having dilatation only. Patency rates ranges from 7.5-51% (see Table 7.1) [128, 129, 475, 478]. In another four studies that included, in total, 31 patients that continued to perform ISD, stabilisation of the stricture with "patency" was obtained in 37.3-100% of cases at twelve to 21 months of follow-up (see Table 7.1) [13, 133, 136, 479].

New onset SUI (1.4%) and other complications are very rare after dilation (see supplementary Table S7.3). Due to the low complication rate, the minimally invasive nature of the technique and the reasonable success rate, it is acceptable to start with urethral dilation as a first-line treatment for an uncomplicated FUS. If the stricture recurs then repeat urethral dilatation is unlikely to be curative.

7.3.1.3 Meatoplasty for treatment of female urethral strictures

Meatal stenosis is extremely rare, with only 2/58 (3%) of females evaluated for voiding dysfunction found to have true meatal stenosis [480]. Only one meatoplasty paper contains more than five patients and has been included for analysis (see supplementary Table S7.4) The patency rate of meatoplasty in girls in this paper is excellent with 96% of the 50 girls in Heising's series having a successful outcome with no reported side effects at twelve months. Forty-eight of 50 patients experienced resolution of their recurrent UTIs and improved voiding symptoms one year after meatoplasty [481]. There was no incontinence or other acute complications reported. For short meatal strictures, meatoplasty is the first-line treatment option.

7.3.2 ***Urethroplasty for treatment of female urethral strictures***

Twenty-five papers report the outcomes of urethroplasty for FUS disease in 253 patients in total after the scope search of the Panel. The Panel have analysed the outcomes of these urethroplasty according to flap or graft type as: vaginal graft, vaginal flap, labial/vestibular graft, labial/vestibular flap and buccal or lingual graft. In female urethroplasty, a dorsal approach is via a stricturotomy at twelve o'clock, a ventral approach is via a stricturotomy at six o'clock and circumferential is a full circumference reconstruction.

7.3.2.1 Vaginal graft augmentation urethroplasty for treatment of female urethral strictures

There were five studies reporting vaginal graft urethroplasty containing 72 patients. All 72 vaginal graft urethroplasties were performed via a dorsal approach in women with a mean/median age of 47.5-60.6 years (range 28-79). At a mean/median follow-up time of 8.5-24.65 months (range 6-36) following vaginal graft urethroplasty 59 (82% range 73-94%) of patients had no recurrent stricture. No complications and no new onset urinary incontinence were reported. Mean/median flow rate (with range) improved from 6.2-8.23 mls/s (2.2-10.2) to 16.64-27.6 ml/s (12-32.7) whilst mean/median PVR (with range) reduced from mean/median 113.2-187.1 mls (44-420) to mean/median 20-90.31 mls (0-122).

See supplementary Table S7.5 for further information.

7.3.2.2 Vaginal flap augmentation urethroplasty for treatment of female urethral strictures

Vaginal flap urethroplasty was reported in 150 women and was always via a ventral approach, utilising an inverted U vaginal flap inlay in seven studies (n=96) [127, 128, 131, 482, 483], a lateral C vaginal flap in three studies (n=58) [125, 133, 137] and one vaginal island flap urethroplasty in one patient [131]. At a mean/median follow-up time of 12-80.7 months (range 3-198), patency rates of 67-100% were reported (Table 7.1). Eight (5.3%) patients had a simultaneous pubo-vaginal sling (PVS), four (2.7%) had a simultaneous Martius fat pad flap interposition, and one (0.7%) had a simultaneous excision of urethral diverticulum. Fourteen (9.3%) patients developed new onset UI, and fourteen (9.3%) developed other acute complications including UTI and intravaginal direction of the urinary stream.

See supplementary Table S7.6 for further information.

7.3.2.3 Labial/vestibular graft augmentation urethroplasty for treatment of female urethral strictures

There were four papers detailing the outcomes of 42 patients having labial or vestibular graft urethroplasty (see supplementary Table S7.7); fifteen had ventral labial minora graft [132, 139, 484] and thirteen had dorsal labia minora graft [136] and fourteen had dorsal labia majora graft. At a mean follow-up of 18 to 24 months, patency rates of 75-86% were reported with ventral grafting whilst this was 100% with dorsal grafting at twelve to nineteen month's follow-up (Table 7.1). One (2.4%) ventral graft patient developed an UTI post-surgery. There were no other complications (including UI). Post-void residual volume reduced from 141.9 +/- 44.2 mls to 24.5 +/- 2-.9 ms post dorsal onlay labial minora graft urethroplasty.

7.3.2.4 Labial/vestibular flap urethroplasty for treatment of female urethral strictures

There were two papers detailing the outcomes of twenty-one patients having labial/vestibular flap urethroplasty: seventeen had a dorsal vestibular flap [16], whilst twelve had a dorsal labia minora flap [485]. At a mean/median follow-up of 24 months the two ventral flap patients (100%) remained stricture-free whilst fifteen (88%) dorsal flap patients remained stricture-free at a mean of twelve months follow-up (Table 7.1 and supplementary Table S7.8). There were no adverse short- or long-term effects reported in either group.

7.3.2.5 Buccal and lingual mucosal graft augmentation urethroplasty for treatment of female urethral strictures

There were eleven papers detailing the outcomes of 234 patients, all treated with BMG except in the series of Sharma *et al*., who used lingual mucosa graft (LMG) in fifteen patients at the dorsal urethra [126]; 44 patients with dorsal onlay oral (buccal or lingual) mucosa graft (DOOMG) [126-128, 131, 134, 474, 486-488]; 27 with ventral-onlay BMG (VOBMG) [127, 135, 489, 490]. The outcome of circumferential BMG urethroplasty in two patients were only detailed in one paper [127]. At a mean/median follow-up of six to 33 months, 62.5-100% of DOOMG urethroplasty patients were stricture-free whilst 92-100% of VOBMG patients were stricture-free at a mean of six to 24.5 months follow-up. Both circumferential BMG patients were stricture-free at a mean of 21 months follow-up (Table 7.1). Twenty-four (10.7%) DOOMG patients suffered a low-grade short-term adverse effect and no patients in any subgroup developed new onset UI. No patients developed acute complications or new onset stress urinary incontinence following VOBMG urethroplasty or circumferential BMG urethroplasty (although this was only performed in two patients). Mean/median flow rate improved from 5.0-12.5 ml/s (range 3-11.2) to 12.1-28 ml/s (range 14-37) and mean/median PVR reduced from 101-270 mls (range 90-200) to 6.5-122.6 mls following DOBMG. Likewise, mean/median flow rate improved from 5.1-7.6 ml/s (range 3-11.2) to 18-29.2 ml/s (range 5-33.4) whilst mean/median post void residual reduced from 100-149 ml (range 0-300) to 15-59.2 ml (range 0-360 mls) following VOBMG. The flow rate and post-void residual changes following circumferential BMG urethroplasty have not been detailed as this technique was performed in two patients only and the outcomes detailed in the describing paper are not specific to this technique.

One prospective randomised trial compared VOBMG with DOBMG and found equivalent stricture-free rates and improvements in maximum flow rate, post-void residual and sexual function. However, there were only twelve patients in each group and follow-up was limited to six months [491].

For further information see supplementary Tables S7.9, S7.10 and S7.11.

7.3.2.6 Anastomotic urethroplasty

Anastomotic urethroplasty has only been described in two cases in the literature – both in women with very short mid-urethral stricture and both of whom were stricture-free at four and 24-months follow-up, respectively. None of them suffered from UI post-operatively [127, 496] (see supplementary Table S7.12).

Table 7.1: Summary of available evidence on treatment of female urethral strictures

Treatment	No. of studies	No. of patients	Patency rate (range %)	New onset UI (%)	Mean/Median FU (months)	Refs
Urethral Dilatation	6	257	40.1 (7.5-51)	1.4	12-59	[128, 129, 475, 478]
Urethral Dilatation + ISD/ planned repeat dilatation	4	109	97 (57-100)**	0	6-21	[13, 133, 136, 479]
Dorsal Vaginal graft urethroplasty	5	72	73-100	0	82 (73-94)	[15, 487, 492, 493]
Ventral Vaginal flap urethroplasty	9	150	83 (67-100)	9.3	12-80.7	[125, 127, 128, 131, 133, 137, 482, 483]
Ventral Labial/Vestibular graft urethroplasty	2	15	80 (75-86)	2.4	18-24	[132, 139, 484]
Dorsal Labial/Vestibular graft urethroplasty	2	27	100	0	12-19	[136]
Dorsal Labial/ Vestibular flap urethroplasty	21	2915	93 (88-100)	0	6-1512	[16]
Dorsal BMG urethroplasty	119	2344	81.6 (62.5-100)	2.1	6-3328	[126-128, 131, 134, 486, 474, 487, 488]
Ventral BMG urethroplasty	54	8927	93 (92-100)	0	610-24.5	[127, 135, 489, 490]

FU = follow-up; ISD = intermittent self-dilatation; N = number of patients; UI= urinary incontinence.
** Patent urethra NOT stricture free as ISC or urethral dilatation continues.*

Summary of evidence	LE
Female urethral stricture symptoms are long-standing and non-specific, the most commonly reported are frequency, urgency, poor flow, incomplete emptying, and urinary incontinence. It is important to exclude FUS in female patients with LUTS.	3
Urethral dilatation alone to 24-41 Fr provides low stricture-free rates of mean 40.1% at mean follow-up 36 (12-59) months.	3
Isolated repeat dilatation yields patency rates of 26.6%. However, urethral dilatation followed by ISD or regular planned dilatation, as palliation, provides patency rates of 97% at mean FU 6-21 months.	3
Urethroplasty provides patency rates of 62.5-100%. Ventral-onlay BMG and DOBMG reported patency rates are 92-100% and 62.5-100%, respectively.	3
Meatotomy/meatoplasty for short meatal strictures has a success rate of 97% at twelve months follow-up.	3

Recommendations	Strength rating
Perform flow rate, post-void residual and voiding cystourethrogram or video-urodynamics in all women with refractory lower urinary tract symptoms.	Strong
Perform urethral dilatation to 24-41 Fr as initial treatment of female urethral stricture (FUS).	Weak
Perform repeat urethral dilatation and start planned weekly intermittent self-dilatation (ISD) with a 16-18 Fr catheter for the 1st recurrence of FUS, or plan repeat dilatation.	Weak
Perform urethroplasty in women with a 2nd recurrence of FUS and who cannot perform ISD or wish definitive treatment. The technique for urethroplasty should be determined by the surgeon's experience, availability and quality of graft/flap material and quality of the ventral versus dorsal urethra.	Strong
Treat meatal strictures by meatotomy/meatoplasty.	Weak

Figure 7.1: Women with refractory frequency, urgency, poor flow and incomplete emptying

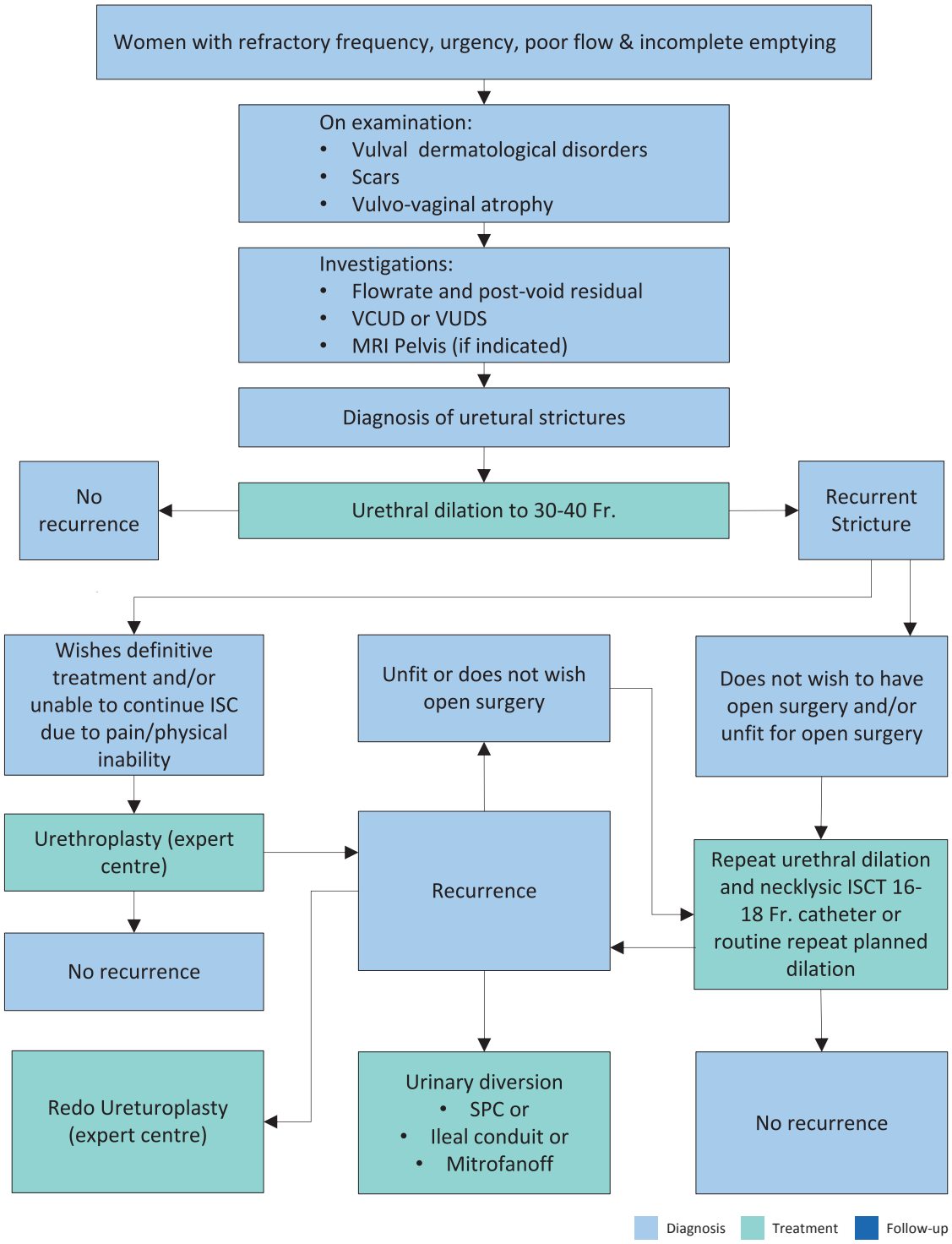

ISC = intermittent self-catheterisation; MRI = magnetic resonance imaging; VUDS = video-urodynamics.

8. DISEASE MANAGEMENT IN TRANSGENDER PATIENTS

8.1 Treatment of strictures in trans men

In trans men, stricture treatment depends on the time after neophallic reconstruction, stricture location, stricture length and quality of local tissues [147, 494].

8.1.1 Management of strictures early after neophallic reconstruction

Urethral surgery on tissues in the acute phase of inflammation and wound healing is not indicated and should be postponed until any healing problems of the neophallus have been resolved and scar tissue formation in the urethra has been stabilised. This usually takes six months [495]. Endoscopic incision for short (< 3 cm) urethral strictures has been performed, mainly at the anastomotic site, with a maximum stricture-free rate of only 16.7% when performed within six months after neophallic reconstruction [496]. Insertion of a suprapubic catheter is the first-line treatment in cases of obstructive symptoms severely affecting the patient's QoL, recurrent UTI, or retention. The alternative is perineostomy, which is a specialist procedure and should be performed by a urologist familiar with transgender urethral anatomy. The perineostomy may be closed at the time of formal urethral reconstruction [497].

8.1.2 Treatment of meatal stenosis in trans men

Intermittent urethral dilatation is an option as palliative treatment for low-grade meatal stenosis [31]. Patients with high-grade meatal stenosis, those who refuse ISD, or those who want a durable solution should be offered simple meatotomy. Patency rates are 50% and 75% for transmen after, respectively, metoidioplasty and phalloplasty [147]. The drawback is that the meatus will be in a hypospadiac position. Alternatively, a staged urethroplasty can be offered [147].

8.1.3 Treatment of strictures at the neophallic urethra

The standard treatment for these strictures is staged urethroplasty with or without graft augmentation (BMG or full thickness SG). A patency rate of 50-88% [147, 495, 498] has been reported after phalloplasty and up to 100% after metoidioplasty [147, 495].

For complex (e.g., fully obliterated) or recurrent strictures at the neophallic urethra, a complete urethral substitution with a tubularised radial forearm-free flap has been proposed with a 67% patency rate [147].

8.1.4 Treatment of strictures at the anastomosis neophallic urethra-fixed part of the urethra

Short, non-obliterative, strictures can be treated by endoscopic incision. A first endoscopic incision has a 37-45.5% patency rate, but this dropped to 0% in case of three or more attempts (median follow-up of 51 months) [495, 496]. Therefore, repetitive endoscopic incisions should be discouraged unless with palliative intent.

For very short (< 1.5 cm) low-grade strictures, Heineke-Mikulicz urethroplasty is an option reporting a 58-80% after phalloplasty and up to 100% after metoidioplasty [147, 495].

If the stricture is nearly or completely obliterative, options are EPA, graft augmentation urethroplasty or staged urethroplasty. Excision and primary anastomosis yields a patency rate of 46-57% after phalloplasty and 78% after metoidioplasty [147, 495]. Alternatively or if EPA is not possible (stricture length >2 cm), a graft augmentation urethroplasty can be performed with a 56-100% patency rate [147, 495]. In case of insufficient ventral tissue during graft urethroplasty, it is advised to support this graft by a local fasciocutaneous flap [147]. An alternative (especially after failure of the previous techniques) can be a staged approach [147, 495].

8.1.5 Treatment of strictures at the fixed part of the urethra

This part of the urethra has a more reliable blood supply, and the dorsal part of the urethra is supported by the corporal bodies of the clitoris. Therefore, single-stage dorsal inlay graft urethroplasty is possible for strictures at this site, especially after metoidioplasty, with up to 100% patency rate [495]. Staged repair with or without a dorsal graft is an alternative for these rare strictures [495].

8.1.6 Definitive perineostomy in trans men

Definitive perineostomy should be offered to patients with refractory strictures or to those with strictures who do not wish to have complex reconstructive surgery [147, 495].

8.2 Peri-operative care after treatment of strictures in trans men

Anecdotally, after endoscopic incision and urethroplasty, the urethral catheter is maintained for two to three weeks [496, 499]. Peri-catheter urethrography is advised before catheter removal as it might be challenging to reinsert the urethral catheter in case of urinary extravasation [499].

8.3 Strictures in trans women

It is acceptable to start with dilation of a short and non-obliterative stricture in trans women although no long-term data about the effectiveness are available [31]. If this is not possible or if it fails, a short (< 1 cm) meatal stricture can be treated by Y-V meatoplasty with an 85% stricture-free rate [500]. Somewhat longer (1-2 cm) meatal strictures can be treated by a neovaginal advancement flap (inverted U or "7-flap") with no recurrence observed after 37 months median follow-up [501].

Summary of evidence	LE
After neophallic reconstruction, local tissues go through the different stages of wound healing and stable wound healing is usually achieved after six months.	3
After two attempts, endoscopic incision is no longer successful in trans men.	3
Two-stage urethroplasty for strictures at the neophallic urethra has a patency rate of 50-88% after phalloplasty and up to 100% after metoidioplasty.	3
Y-V meatoplasty for short (< 1 cm) meatal stenosis in trans women has a stricture-free rate of 85%.	3

Recommendations	Strength rating
Do not perform endoscopic incision or urethroplasty within six months after neophalloplasty.	Strong
Do not perform more than two endoscopic incisions for strictures in trans men unless with palliative intent.	Strong
Perform staged urethroplasty for strictures at the neophallic urethra if open reconstruction is indicated.	Weak
Perform Y-V meatoplasty for short (< 1 cm) meatal stenosis in trans women if open reconstruction is indicated.	Weak

9. TISSUE TRANSFER

9.1 Comparison of grafts with flaps

One small RCT (LS excluded) comparing OMG with PSF found no significant difference in urethral patency rate [502]. Penile skin flaps had a higher urogenital morbidity (superficial penile skin necrosis, penile torsion, penile hypoesthesia, and post-void dribbling) and longer operation time compared to OMG. Furthermore, patient dissatisfaction was significantly higher with penile flaps [502]. Another small RCT (LS excluded) comparing penile skin grafts with PSF confirmed these findings with longer operation time and more superficial penile skin necrosis in the group of the flaps, whereas the urethral patency rate was similar between both groups [355]. Several retrospective series also found a comparable urethral patency rate between PSF and grafts [272, 274, 503, 504] (Table 9.1).

Table 9.1: Comparative studies of grafts vs. flaps used in urethroplasty for anterior urethral strictures

Study	Type of study	LS	Follow-up (months)	Flap		Graft		p-value*
				Type	Urethral patency	type	Urethral patency	
Barbagli *et al.* [272]	Retrospective	Excl.	55	LIF	12/18 (67%)	OMG/PSG	36/45 (80%)	0.32
Dubey *et al.* [502]	RCT	Excl.	22-24	LIF	22/26 (84.6%)	BMG	24/27 (88.9%)	0.70
Fu *et al.* [274]	Retrospective	Excl.	>12	All types	166/199 (83.4%)	LMG	80/94 (85.1%)	0.71

Hussein *et al.* [355]	RCT	Excl.	36	TIF	15/19 (78.9%)	PSG	13/18 (72.2%)	0.25
Lumen *et al.* [504]	Retrospective	NR	42-43	All types	23/29 (79.3%)	OMG/PSG	63/75 (84%)	0.57
Sa *et al.* [503]	Retrospective	Excl.	28 (18-60)	TIF	28/34 (82.3%)	BMG	67/82 (81.7%)	0.851

BMG = buccal mucosa graft; Excl. = excluded; LIF = longitudinal island flap; LMG = lingual mucosa graft; LS = lichen sclerosus; mo = months; NR = not reported; OMG = oral mucosa graft; PSG = penile skin graft; TIF = transverse island flap; RCT = randomised controlled trial.
** if not reported: recalculated by EAU Urethral Strictures Panel with chi²-statistics.*

Due to their robust vascular pedicle, flaps can be used as a tube as well as a patch in a single-stage approach [442]. Castagnetti *et al.*, showed that grafts used as a tube have significantly higher complication rates as compared to onlay grafts (OR: 5.86; 95% CI: 1.5-23.4) [505]. A review by Patterson *et al.*, also reported high (circa 50%) complication and recurrence rates for tubularised grafts [506]. Iqbal *et al.*, have shown an encouraging 87% stricture-free rate in 23 patients who were offered single-stage circumferential skin flap urethroplasty [281]. Therefore, if there is a need to reconstruct a complete urethral segment with a tissue-transfer tube in a one-stage operation, flaps are usually the preferred option. As flaps carry their own vascular supply to the reconstruction site, they do not rely on the local vascularisation of the recipient site. Therefore, they need to be considered in case of poor urethral vascularisation (e.g., after irradiation or dense scarring after previous urethroplasty) [504, 507]. In addition, flaps survive well in the presence of active urinary infection [508].

Grafts and flaps should not be considered competitors in urethral surgery. A combination of a flap with a graft is possible for complex, multifocal or penobulbar strictures [504, 509, 510].

Summary of evidence	**LE**
Flaps have a higher urogenital morbidity, but a comparable patency rate compared to grafts.	1b
Grafts have a significantly higher complication rate compared to flaps when complete tubularisation in a single-stage approach is needed.	1b
Flaps do not rely on the local vascularisation of the recipient site.	3

Recommendations	**Strength rating**
Use a graft above a flap when both options are equally indicated.	Strong
Do not use grafts in a tubularised fashion in a single-stage approach.	Strong
Use flaps in case of poor vascularisation of the urethral bed.	Weak

9.2 Comparison of different types of flaps

Different local flaps have been described. Penile skin flaps are generally hairless, although the ventral penile skin can be hair-bearing around the raphe in some ethnic groups/phenotypes. They can be harvested as a transverse preputial skin flap [511], a transverse distal PSF [358, 508, 512, 513] or as a longitudinal island flap [514]. Urethral patency rates vary between 74.2-100% [274, 358, 508, 511-514]. Complications include skin necrosis (0-3.8%), fistula (0-7%), penile deformity (0-7%), post-void dribbling (0-79%) and sacculation (0-16.5%) (see supplementary Table S9.1). As there are no direct comparative series available about these flaps it is not possible to determine which performs better.

Hair-bearing perineal and scrotal flaps have been described as well. Fu *et al.*, demonstrated that PSF had a significantly better urethral patency rate compared to scrotal and perineal skin flaps (respectively 87.7%, 69% and 66.7%) [274]. The hair-bearing perineal and scrotal skin flaps are associated with hairball formation and chronic infection which may cause failure of the repair. A study of Blandy with long-term follow-up, reports 3% revision for calculi and 3% revision for diverticula [515].

An alternative is to epilate the needed scrotal skin prior to tissue transfer [516, 517] or to patch an OMG to the underlying dartos tissue of the scrotum after incision of the scrotal skin and use this patch as a flap in a second attempt [442].

Summary of evidence	LE
Hair-bearing flaps have a lower urethral patency rate compared to non-hair-bearing flaps.	3

Recommendation	Strength rating
Do not use hair-bearing perineal or scrotal flaps unless no other option is feasible.	Strong

9.3 Comparison of different types of grafts

Buccal mucosa is at present the most commonly used graft. A systematic review on anterior urethral strictures reports a urethral patency rates of buccal mucosa of 86.6% with an average follow-up of 31.5 months [518].

Penile skin is another popular graft, especially in uncircumcised men where the foreskin is an abundant source of graft material.

In case of LS, Trivedi *et al*., demonstrated a significantly higher urethral patency rate when using non-genital mucosal grafts for reconstruction (82.6%) compared to genital skin grafts (4%) [519]; therefore, the use of genital skin in LS cases is not indicated.

In one RCT (Pee'BuSt trial) comparing buccal mucosa with penile skin as a graft for dorsal onlay augmentation urethroplasty for anterior strictures, no significant difference in outcome could be observed [520]. A systematic review and meta-analysis suggests that BMG augmentented urethroplasty, may be superior to penile skin graft urethroplasty. However, there were a lot of confounding factors, and clear conclusions cannot be made [521]. Lengthy skin grafts (up to 20 cm) can be taken from the foreskin in a spiroid fashion which is clearly more difficult with OMG.

The main disadvantage of BMG harvesting is the oral morbidity and because of this morbidity, lingual mucosa has been proposed as alternative. A SR and meta-analysis of comparative studies comparing LMG with BMG (four prospective, two retrospective studies) showed no significant differences in urethral patency rate and overall long-term complication rate [522-524]. These studies revealed that LMG was associated with more difficulties in eating/drinking, speaking, tongue protrusion and dysgeusia [522, 523]. In 13.8-20%, speaking problems remained after six months [522, 523]. A retrospective study of Xu *et al*., reported difficulties in tongue movements, numbness over the donor site and speaking difficulties in 6.2%, 4.9% and 2.5% of patients, respectively after twelve months [301]. On the other hand, BMG harvesting provoked more oral tightness which was present in up to 24% of patients after six months [522, 523]. Chauhan *et al*., showed that immediate and early donor site complications were more common in the BMG group, except for bleeding being more common in the LMG group. Numbness (61%), difficulty in chewing (54%), swelling (48%) and articulation (40%) were the most common problems during the first week. Late donor site complications were rare [525]. Pal *et al*., describes more short-term complications (difficulty in tongue movement and slurring of speech) in the LMG group, compared to the BMG group. Long-term complications (after three months) at the donor site (persistent pain, perioral numbness, tightness of mouth, salivary disturbance, scarring of the cheeks) were only seen in the BMG group [526]. For long strictures, buccal mucosa can be combined with lingual mucosa [301].

The use of lower lip mucosa was described, especially when smaller grafts are needed, and has similar qualities to lingual mucosa. However, a narrative review based on the experience from retrospective series showed that these grafts have a higher post-operative donor site morbidity and can lead to permanent sequelae (persistent discomfort, neurosensory deficits, salivary flow changes and important aesthetic changes) at the donor site, which have not been described with lingual mucosa [527].

Beyond the oral mucosa and penile skin graft, a multitude of other autologous grafts have been described. These include: postauricular skin [510, 528], abdominal skin [360], split-thickness mesh graft from the thigh [341], inguinal skin [300] and colonic mucosa [529] (Table 9.2). Manoj *et al*., only used the postauricular skin when both genital skin and oral mucosa were not usable [528]. Marchal *et al*., used postauricular skin in addition to oral mucosa to reconstruct lengthy strictures [510]. Meeks *et al*., reported the use of abdominal skin graft mainly in patients with lengthy strictures where OMG harvesting would be insufficient, in case of prior OMG urethroplasty or if OMG was refused by the patient [360]. Pfalzgraf *et al*., reported a comparable urethral patency rate for split-thickness mesh graft and BMG (respectively 84% and 83%), but more penile deviation (9% vs. 0%) and lower satisfaction (83.3% vs. 96.7%) with split-thickness mesh graft [341]. Xu *et al*., used colonic mucosa for lengthy (> 10 cm) strictures. Urethral patency rate was 85.7% but graft harvest requires an abdominal procedure, and 1/35 (2.9%) patient developed a colonic-abdominal fistula [529]. Due to the limited experience with grafts other than oral mucosa and penile skin, they should only be considered if oral mucosa and penile skin are not available, indicated, or desired.

Table 9.2: Outcome of case series of other autologous grafts

Study	Type of graft	N	Follow-up (months)	Stricture length (cm)	Urethral patency (%)
Bastian *et al*. 2012 [302]	Inguinal skin	34	70 (3-86)	8 (1.5-14)	91
Manoj *et al*. 2009 [528]	Postauricular skin	35	22 (3-48)	8.9 (3-15)	89
Meeks *et al*. 2010 [360]	Abdominal wall skin	21	28 (11-52)	11 (4-24)	81
Pfalzgraf *et al*. 2010 [351]	Split thickness skin graft	57/68	32	NR	84
Xu *et al*. 2009 [529]	Colonic mucosa	35	53.6 (26-94)	15.1 (10-20)	85.7

N = number of patients; NR = not reported.

Summary of evidence	LE
Patency rates of buccal mucosa and lingual mucosa are comparable.	1a
Different types of oral grafts have distinct types of oral morbidity and some of the oral complications might last in the long-term.	1a
Patency rates with penile skin grafts are 79-81.8% versus 85.9-88.1% with buccal mucosa.	3
In LS related strictures, the use of genital skin graft is associated with poor patency rates (4%).	3

Recommendations	Strength rating
Use buccal or lingual mucosa if a graft is needed and these grafts are available.	Weak
Inform the patient about the potential complications of the different types of oral grafting (buccal versus lingual versus lower lip) when an oral graft is proposed.	Strong
Use penile skin if buccal/lingual mucosa is not available, suitable, or accepted by the patient for reconstruction.	Weak
Do not use genital skin graft in case of lichen sclerosus.	Strong

9.4 Tissue engineered grafts

9.4.1 Cell-free tissue engineered grafts

These grafts are derived from cadaveric or animal sources (e.g., porcine small intestine submucosa [SIS], acellular bladder matrix, acellular dermal matrix), are completely cell-free and serve as a scaffold for host cell ingrowth [530]. The main advantage suggested for their use is the off-shelf availability [530].

A small RCT (n=30) comparing acellular bladder matrix with BMG reported a urethral patency rate of respectively 66.6% and 100%. The poorer results of acellular bladder matrix were the most apparent in cases of an unhealthy urethral bed [531].

Several small retrospective case series using mainly porcine small intestinal submucosa, demonstrate varying patency rates from 20-110%. The patient groups were heterogenious in terms of aetiology, previous treatment, urethral location and definition of success rate. An overview can be found in Table 9.3. Most papers report a poorer outcome in case of extensive spongiofibrosis, poor vascular graft bed, previous treatments and longer strictures [531-535] (Table 9.3).

Table 9.3: Outcome of retrospective case series using cell-free tissue engineered grafts

Study	N	FU (mo)	Type of graft	Patency Rate (%)
el-Kassaby *et al*. 2008 [531]	15	25	cadaveric acellular bladder matrix	33-88
Palminteri *et al*. 2012 [535]	30	71	porcine small intestinal submucosa	76
Xu *et al*. 2013 [534]	28	24.8	porcine small intestinal submucosa	92
Tang *et al*. 2020 [533]	49	15	allogeneic acellular dermal matrix	85.7
Fiala *et al*. 2007 [532]	50	31.2	porcine small intestinal submucosa	80

Summary of evidence	LE
Patency rate of cell-free tissue engineered grafts decreases with large stricture length and unhealthy urethral bed.	1b

Recommendation	Strength rating
Do not use cell-free tissue engineered grafts in case of extensive spongiofibrosis, after failed previous urethroplasty or stricture length > 4 cm.	Weak

9.4.2 Autologous tissue engineered oral mucosa graftss

These grafts contain a matrix seeded with autologous oral mucosa cells. Production requires a small oral mucosa biopsy (at 0.5 cm²) and the graft is further manufactured in the lab. The main advantage suggested is the reduction of oral donor site morbidity whereas the main disadvantages are costs and the strict time frame between manufacturing and implantation of the graft [530].

The clinical use of autologous tissue-engineered OMG was evaluated in a prospective, multicentre study including 99 patients [536]. Estimated twelve- and 24-months urethral patency rate was 67.3 and 58.2%, respectively. Oral adverse events were minimal. No comparative studies with acellular grafts or native OMGs are available nor are there any data about the cost-effectiveness [530].

Summary of evidence	LE
Safety, patency rate and cost-effectiveness of autologous tissue-engineered grafts is currently under research.	3

Recommendation	Strength rating
Do not use autologous tissue-engineered oral mucosa grafts outside the frame of a clinical trial.	Strong

9.5 Management of oral cavity after buccal mucosa harvesting

The post-operative morbidity of closure vs. non-closure of the buccal mucosa harvesting site has been evaluated by a number of prospective RCTs.

The results are summarised in Table 9.4. Based on these findings, no clear recommendation can be provided as to whether or not to close the harvesting site and the decision can be left to the treating physician.

Oral rinsing with chamomile [537] or chlorhexidine [523, 538] solution has been suggested in the first post-operative days without any evidence that this reduces pain or other oral complications.

Table 9.4: Effect of non-closure compared to closure on oral morbidity after buccal mucosa harvesting

Study	Early oral pain	Eating/ drinking problems	Altered taste	Altered salivation	Oral tightness	Perioral numbness	Oral bleeding	Slurred speech
Soave *et al*. [537]	=	=	=	=	=	=	=	=
Rourke *et al*. [539]	=	↓	NR	NR	↓	↓	=	NR
Muruganandam *et al*. [540]	↓	=	NR	=	=	=	=	NR
Wong *et al*. [538]	=	↑	NR	NR	=	=	=	NR
Lumen *et al*. [523]	↑	NR	NR	NR	NR	NR	NR	NR

↓ = less morbidity with non-closure; ↑ = more morbidity with non-closure; = = no significant difference; NR = not reported.

10. PERI-OPERATIVE CARE OF URETHRAL SURGERY

10.1 Urethral rest

After any form of urethral manipulation (urethral catheter, ISD, dilatation, DVIU), a period of urethral rest is necessary in order to allow tissue recovery and stricture "maturation" before considering urethroplasty. This improves the ability to identify the true extent of the fibrotic segments during subsequent surgery. If the patient develops incapacitating obstructive symptoms or urinary retention, a suprapubic catheter should be inserted. Terlecki *et al*., propose diagnostic evaluation after two months and urethroplasty after three months of urethral rest. These timings are based on the general principles of wound healing [541]. In their study, it has been shown that these periods allow for reliable stricture evaluation during urethrography which is, in turn, important to ensure selection of the most appropriate urethroplasty technique [541]. Utilising this strategy, similar outcomes were obtained compared to patients with stable previously unmanipulated strictures [541]. However, the optimal duration of urethral rest for all patients is not known and the degree of associated infection and inflammation should be taken into account as well, with longer periods of rest in those with greater degrees of infection and inflammation.

Summary of evidence	LE
After any form of urethral manipulation, a minimum period of three months urethral rest is necessary to allow for tissue healing before performing urethroplasty.	3

Recommendation	Strength rating
Do not perform urethroplasty within three months of any form of urethral manipulation.	Weak

10.2 Antibiotics

Post-operative wound infection and UTI are common post-operative complications and infection at the site of reconstruction may contribute to failure of urethroplasty. The vast majority of reconstructive urologists perform urine culture one to two weeks prior to surgery [542]. Urine culture is superior to urine-analysis which can be omitted in the pre-operative evaluation [542]. If infection or colonisation is present, a therapeutic course with antibiotics is recommended pre-operatively. Pre-operative UTI, even when properly treated, could increase the risk of post-operative UTI [543]. In case of an indwelling catheter general principles would suggest at least an attempt to suppress the colonisation with pre-operative antibiotics [542]. These practices are in accordance with the strong recommendations of the EAU Guidelines on Urological Infections [589]:

- "Screen for and treat asymptomatic bacteriuria prior to urological procedures breaching the mucosa."
- "Treat catheter-associated asymptomatic bacteriuria prior to traumatic urinary tract interventions."

An intra-operative prophylactic regimen with antibiotics (according to local antibiotic resistance profiles) is effective in reducing the rate of post-operative surgical site and UTIs [542]. Although most urologists continue with post-operative antibiotics upon and even beyond catheter removal, there is no evidence that such a prolonged administration would reduce the infective complication rate [542]. A retrospective study from Baas *et al*., revealed that extended postoperative antibiotic prophylaxis (three weeks until catheter removal versus three days around catheter removal) does not appear to affect UTI rates following urethroplasty [544]. The EAU Guidelines on Urological Infections [589] do not routinely recommend the use of antibiotic prophylaxis to prevent clinical UTI after urethral catheter removal. There is no evidence that this recommendation would not apply to catheter removal after urethral surgery.

Summary of evidence	LE
An intra-operative prophylactic regimen with antibiotics is effective in reducing the rate of postoperative surgical site and urinary tract infections.	4

Recommendation	Strength rating
Administer an intra-operative prophylactic regimen with antibiotics at time of urethral surgery.	Strong

10.3 Catheter management

After uncomplicated DVIU, there is no advantage in maintaining the catheter for a prolonged period and it should be removed within 72 hours [545].

After one-stage urethroplasty and closure of the urethral plate after staged urethroplasty, urinary extravasation at the site of reconstruction must be avoided [546]. For this purpose, urinary diversion by either transurethral catheter or suprapubic catheter with urethral stent can be used. With respect to the type of catheter material, a prospective randomised (but underpowered) trial comparing silicone vs. hydrogel coated latex transurethral catheters showed no significant difference in the time to stricture recurrence nor in the overall recurrence rate [546]. The size of the urethral catheter utilised usually varies between 14 Fr and 20 Fr [547, 548]. Systematic use of anticholinergic drugs has not shown a significant reduction in the rate of involuntary pericatheter voiding whilst catheterised [549].

After urethroplasty an indwelling catheter is commonly left *in situ* for two to three weeks [548, 550]. After three weeks of urethral catheterisation, an extravasation rate of 2.2-11.5% at urethrography has been reported after different types of urethroplasty [550-553]. However, success with early catheter removal under three weeks has also been reported. A study after EPA for non-complicated anterior strictures demonstrated no significant difference in extravasation (6.8% vs. 4.5%) and recurrence rates (4.9% vs. 5.2%) between catheter removal at one or two weeks respectively [554]. Poelaert *et al*., reported an extravasation rate of 3.5% vs. 8.3%, when the catheter was removed < 10 days or > 10 days, respectively, after all types of urethroplasty (n=219) (p=0.158) [547]. Importantly, patients who had a duration of catheterisation of > 10 days had longer and more complex strictures [547]. Beiske *et al*., revealed a higher incidence of UTI in patients with a three week catheterisation after open urethroplasty, compared to two weeks [555].

Prior to catheter removal after urethroplasty, it is important to assess for urinary extravasation to avoid ensuing complications including peri-urethral inflammation, abscess formation and fistulation [550, 552]. Importantly, some authors have identified urinary extravasation as a predictive factor for stricture recurrence [547, 556]. Other series, however, could not confirm the prognostic significance of urinary extravasation but they included any form of extravasation (including minor leaks) [552, 553]. Grossgold *et al*., found that high-grade leaks (defined as length > 1.03 cm and width > 0.32 cm) were significantly associated with higher restricture rates. This study also found length of extravasation > 1.03 cm alone to be an independent predictor of restricture [556]. In cases of persistent and significant urinary extravasation, the catheter should be maintained or reinserted and the examination repeated after one week [550]. However, low-grade ("wisp-like") extravasation does not appear to affect long-term restricture rate and the catheter can be removed in these cases without subsequent urethrogram [552, 556]. In case of any doubt about the significance of extravasation, it is safe to keep the catheter in for an additional week and ReDo the assessment.

The assessment of urinary extravasation is achieved by either pericatheter retrograde urethrography (pcRUG), classic RUG or VCUG [550]. A prospective study (n=80) comparing pcRUG and VCUG in a within-patient fashion demonstrated a comparable sensitivity for contrast extravasation. Moreover, pcRUG averts the risk of having to reinsert the catheter, avoids the problem of patients being unable to void during VCUG and requires significantly less radiation (120 mGy/cm^2 versus 241 mGy/cm^2; $p < 0.001$) [557].

In cases of attempted VCUG where the patient is not able to void during fluoroscopy after catheter removal, RUG should be performed [556].

Although limited evidence for urethroplasty care in trans men exists, one study advised a three-week period of transurethral catheterisation with pcRUG upon catheter removal [499].

After perineostomy or the 1st stage of staged urethroplasty, the catheter can be removed without need for urethrography after three to five days [339, 552].

Summary of evidence	**LE**
Prior to catheter removal after urethroplasty, it is important to assess for urinary extravasation with urethrography to avoid ensuing complications including peri-urethral inflammation, abscess formation and fistulation.	2b
After uncomplicated DVIU, there is no advantage in maintaining the catheter for a prolonged period.	3
Early catheter removal may be appropriate for a subset of patients with short, uncomplicated, strictures.	3

Recommendations	Strength rating
Perform a form of validated urethrography after urethroplasty to assess for urinary extravasation prior to catheter removal.	Strong
Remove the catheter within 72 hours after uncomplicated direct vision internal urethrotomy or urethral dilatation.	Weak
Consider 1st urethrography seven to ten days after uncomplicated urethroplasty to assess whether catheter removal is possible, especially in patients with bother from their urethral catheter.	Weak

11. FOLLOW-UP

11.1 Rationale for follow-up after urethral surgery

The rationale for following-up patients after urethral stricture surgery is to detect and manage any complication or recurrence. As with any surgical procedure, following urethroplasty some patients will present with complications at short to medium follow-up: up to 34-38% of all anterior urethroplasties. Most of these complications (92-99.1%) would be classified as Clavien grade 1 or 2 [558, 559]. Even though urethroplasty techniques provide the highest chances for successful treatment of urethral strictures, some patients will experience recurrence [346]. For further details on particular outcomes in each urethral segment, please review the individual chapters of this Guideline.

Summary of evidence	LE
After urethroplasty surgery, recurrent strictures appear with different frequency depending on stricture features and urethroplasty techniques.	3

Recommendation	Strength rating
Offer follow-up to all patients after urethroplasty surgery.	Strong

11.2 Definition of success after urethroplasty surgery

The "traditional academic" definition of post-operative success after urethroplasty has been considered as "The lack of any post-operative intervention for restricture" [560]. This definition, despite being widely used [305, 558] is problematic as it ignores asymptomatic or even symptomatic recurrences in patients not willing to undergo further surgeries [560]. There is some variation as to what is considered intervention with some groups accepting endoscopic treatments as success, while considering failure only as the requirement for a ReDo urethroplasty [306].

A more objective definition of success is the "anatomic success", defined as "Normal urethral lumen during RUG or cystoscopy, regardless of patient symptoms". Using this definition, stricture recurrence or anatomical failure is considered by some groups as urethral narrowing found to be endoscopically impassable – without force – with a 16 Fr flexible endoscope [145, 561]. This definition is certainly stricter, with up to 35% of cystoscopic recurrences after bulbar urethroplasty remaining asymptomatic, and thus would have been considered as successful if a "lack of further intervention" definition was used [145]. Other groups consider cystoscopic recurrence as any stricture that is visible on post-operative cystoscopy, even the so-called "large calibre re-strictures" (> 17 Fr) [143]. Not all anatomic recurrent strictures would need further treatment [560]. It was suggested to intervene when the anatomic recurrence is associated with recurrence of symptoms, stricture-related high post-void residuals or a stricture calibre of < 14 Fr – even if these are asymptomatic [560].

Over the last ten years, the evaluation of urethral surgery outcomes has shifted towards a "patient-reported definition of success". The aim of any urethral intervention is to allow patients to return to a normal state of voiding while maintaining QoL or to minimise symptoms, reduce disability, and improve HRQoL by restoring normal urinary function [562]. Even if the surgeon reconstructed a wide and patent urethra, if patients experience pain, sexual dysfunction or perceive their urinary function as not improved, they will not rate their outcome as successful [560]. On a multivariate analysis including both patient-reported and clinical parameters, urine flowmetry parameters failed to demonstrate significant contribution to satisfaction [563]. Kessler *et al.*, reported that only 78.3% of patients with clinical success described themselves as (very) satisfied. More

dissatisfaction significantly appeared with penile curvature, penile shortening, worsening of erectile function and impairment of sexual life [564]. Conversely, 80% of patients defined as clinical failures considered themselves as (very) satisfied with their outcomes [564]. Regardless of anatomic success after urethroplasty, post-operative pain, sexual dysfunction and persistent LUTS were independent predictors of patient dissatisfaction [563]. Improvement in voiding function (i.e., statistical improvement on IPSS) alone does not predict patient satisfaction after urethroplasty [565]. On a multivariate analysis including both patient-reported and clinical parameters, after adjusting for disease recurrence and age, persistence in voiding symptoms (weak stream), genitourinary pain, and post-operative sexual function alterations were the greatest independent drivers of post-operative dissatisfaction [563]. In addition, penile shortening (OR: 2.26; 95% CI: 1.39-3.69) and chordee (OR: 2.26; 95% CI: 1.44-4.19) were independent predictors of patient dissatisfaction after urethroplasty [565] (Table 11.1).

Table 11.1: Predictors of patient dissatisfaction after urethral surgery

Predictor/Symptoms	Measure of effect	Authors
Weak/very weak urinary stream	< 0.001	Kessler TM *et al*. J Urol 2002 [564]
Penile curvature	0.001	
Penile shortening	0.001	
Worsening of erectile function	0.001	
Impairment of sexual life	< 0.001	
Sexual activity alteration	OR: 4.36 (1.54 – 12.37)*	Bertrand LA *et al*. J Urol 2016 [563]
Erection confidence (SHIM)	OR: 1.53 (1.12 – 2.07)*	
Inability to ejaculate (MSHQ)	OR: 1.52 (1.15 – 2.01)*	
Urethral pain	OR: 1.71 (1.05 - 2.77)*	
Bladder pain	OR: 2.74 (1.12 – 6.69)*	
Urinary strain (CLSS)	OR: 3.23 (1.74 – 6.01)*	
Hesitancy (IPSS)	OR: 2.01 (1.29 – 3.13)*	
Voiding quality of life (IPSS)	OR: 1.96 (1.42 – 2.72)*	
Penile shortening	OR: 2.26 (1.39-3.69)**	Maciejewski CC *et al*. Urology 2017 [565]
Chordee	OR: 2.26 (1.44 – 4.19)**	

SHIM = Sexual Heath Inventory for Men; MSHQ = Male Sexual Health Questionnaire;
CLSS = Core Lower Urinary Tract Symptom Score; IPSS = International Prostate Symptoms Score.

Due to this evident discrepancy between surgeon's assessment and patient assessment, PROMs have been developed for the follow-up after urethroplasty [160, 562].

A complete approach for urethral surgery outcomes would combine both anatomic, endoscopic, and Patient-reported success [560, 566]. The Panel suggest using a functional definition of success in clinical practice, namely "lack of symptoms and/or need for further interventions".

Collecting standardised documentation of the patient's subjective assessment of their symptoms and objective anatomic outcomes would be limited for academic purposes, in order to allow comparison of surgical outcomes among reconstructive urologic surgeons and centres. Those objective and subjective outcomes measures should therefore be assessed and reported (simultaneously but separately) when evaluating urethroplasty results [560].

11.3 Follow-up tools after urethral surgery

*11.3.1 **Diagnostic tools for follow-up after urethral surgery***

11.3.1.1 Calibration during follow-up after urethral surgery

The difference between calibration and urethral dilatation is usually subjective as soft strictures may be dilated during calibration [567]; therefore, urethral calibration should be used with caution for follow-up after urethroplasty. Dedicated calibration bougies should be used and not dilatators.

11.3.1.2 Urethrocystoscopy during follow-up after urethral surgery

Urethrocystoscopy has been considered the most useful tool to confirm the presence or absence of a recurrent stricture [143, 568], as up to 35% of patients with re-strictures remain asymptomatic [145]. Also, the cystoscope could be a measure to calibrate the strictured lumen, bearing in mind the most commonly used endoscopes: 15.7 Fr (5 mm diameter) or 17.3 Fr (5.5 mm diameter) [568]. Urethrocystoscopy allows differentiation of recurrences as diaphragm/cross-bridging – responding to simple intervention, or significant urethral restrictures – requiring repeated interventions or ReDo surgeries [569]. Endoscopic assessment at three months after anterior urethroplasty can predict the risk for further re-intervention at one year. Compared to normal endoscopy, large calibre (> 17 Fr) restrictures have a HR of 3.1 (1.35-7.29) for repeat intervention while small calibre (< 17 Fr) restrictures have a 23.7 HR (12.44-45.15) adjusted for age, stricture length, location, and aetiology [143]. The main problem with using urethrocystoscopy for routine follow-up is the low compliance of patients as only 54% of patients underwent endoscopy at one year after urethroplasty, even when it was a part of a study protocol [145].

11.3.1.3 Retrograde urethrogram and voiding cystourethrogram during follow-up after urethral surgery

Retrograde urethrogram combined with VCUG are commonly used to confirm suspected recurrence [570, 571] or as part of a routine protocol to assess post-operative urethral patency [572, 573].

11.3.1.4 Urethral ultrasound – Sonourethrography during follow-up after urethral surgery

The use of SUG as a follow-up tool is not very common. It would be a reliable tool for diagnostic recurrent strictures [570].

11.3.2 ***Screening tools for follow-up after urethral surgery***

These tools are used to assess whether there is suspicion of stricture recurrence and need for subsequent diagnostic evaluation (see section 5. Diagnostic evaluation).

11.3.2.1 Flow-rate analysis during follow-up after urethral surgery

Evaluating the Q_{max} is the commonest follow-up tool. Different cut-off points from Q_{max} 15 ml/s or 12 ml/s were suggested to consider the intervention as a failure or to trigger a confirmatory test for recurrence [574]. There is no clear threshold, and 19% of patients with Q_{max} < 14 ml/s would still have a patent urethra, allowing passage of 15 Fr cystoscope [146].

Flow rates may be affected by operator error, BPO/LUTS, bladder dysfunction, and variations in bladder capacity. Further limitations of uroflowmetry include the need for a minimum voided volume of 125-150 ml to reach a voided flow rate that reliably predicts an abnormality [567]. Even in controlled settings, the percentage of patients with adequate pre- and post-operative uroflowmetry analysis is only 31% [573]. Comparing both pre- and post-operative Q_{max} levels was suggested, and a difference in Q_{max} of 10 ml/s or less is found to be a reliable screen tool for recurrence (sensitivity 92%, specificity 78%). This measure also has strong reproducibility (R=0.52) [573]. Unfortunately, this improvement after urethroplasty is significantly different between age groups, with less than 10 ml/s average change in those over 65 years old, probably affected by BPO and/or bladder dysfunction [575]. Another parameter to consider is the shape of the voiding curve, recording it as flat (obstructed) or bell-shaped [576]. An obstructive voiding curve demonstrated 93% sensitivity to predict recurrent strictures, while a combination of urinary symptoms and obstructive voiding curve achieved 99% sensitivity and 99% NPV [576].

11.3.2.2 Post-void residual ultrasound measure during follow-up after urethral surgery

Post-void residual US measure is significantly increased in patients with recurrent strictures compared with those without recurrences [570]. Unfortunately, PVR measurement is affected by abdominal ascites, bladder diverticula and/or poor bladder function [567], with some studies reporting inconsistent correlation with obstruction in the presence of BPO. Also, US measures of PVR are user dependent, showing high interobserver variability. Combined with other tests – uroflowmetry, IPSS, and SUG – PVR achieves adequate predictive values [570], but currently there is no literature to support its solo use to assess urethral stricture recurrence [577].

11.3.2.3 Symptom questionnaires during follow-up after urethral surgery

The IPSS questionnaire, despite being designed for BPO, showed significant improvement after successful urethroplasty and inverse significant correlation with Q_{max} [565, 567]. The mean improvement of IPSS is around -11 points (range -19 to -5) [575].

Table 11.2: Post-urethroplasty changes in IPSS values

Author	N	Mean pre-operative value	Mean post-operative value	Change	Significancy
Morey AF *et al.* 1998 [578]	50	26.9	4.4	NR	p < 0.0001
DeLong J *et al.* 2013 [575]	110	NR	NR	-11 (IQR -19 - -5)	p < 0.001
Maciejewski CC *et al.* 2017 [565]	94	18.7 (+/- 9)	5.8 (+/- 5)	NR	p < 0.0001

N = number of patients; NR = not reported; IPSS = International Prostate Symptoms Score; IQR = interquartile range.

Combination of IPSS and Q_{max} analysis was suggested to diagnose recurrences. Using an IPSS cut-off point of 10 points associated with Q_{max} > 15 ml/s would prevent further invasive studies in 34% of patients, while only 4.3% of strictures < 14 Fr would have been missed. Using an IPSS cut-off point of 15 points associated with Q_{max} > 15 ml/s would prevent further invasive studies in 37% of cases, while 6% of strictures < 14 Fr would have been missed [579].

The Visual Prostate Symptom Score (VPSS) was also used to diagnose recurrent urethral strictures, offering a significantly shorter time to completion compared with IPSS, especially in cases of illiteracy or limited education. Visual Prostate Symptom Score showed a good correlation with IPSS, Q_{max} and urethral diameter. A combination of VPSS > 8 with Q_{max} < 15 ml/s had a NPV of 89% and a PPV of 87% for recurrent urethral strictures [580].

Post-micturition dribble, assessed by the specific question of the USS-PROM questionnaire, was present in 73% of patients pre-operatively and 40% after anterior urethroplasty, while only 6.3% was *de novo*. Incidence was not predicted by stricture location nor urethroplasty type [150].

11.3.3 Quality of life assessment, including disease specific questionnaires during follow-up after urethral surgery

Urethral stricture affects QoL evaluated by EQ-5D-3L questionnaire. Pre-operative anxiety and depression was found in 29% of patients. *De novo* AD after urethroplasty is uncommon (10%) and has two predictors: decreased sexual function and poor reported image of overall health [581]. A more recommended approach is the assessment of the condition-related QoL [582]. The USS-PROM proved useful to assess outcomes in anterior urethroplasty patients [562]. Its use also received criticism, as some of the individual generic QoL questions do not improve after successful urethroplasty, as they are not condition-specific [583]. Currently, there is another version of PROM, being developed and validated by a North American collaborative group, including questions related to the sexual consequences of urethral stricture disease [161]. PROM questionnaires should be implemented in each visit to check for functional success, as they are able to show improvement over time.

The Core Lower Urinary Tract Symptom Score (CLSS) questionnaire was used to assess pre- and post-urethroplasty pain in the bladder, penis/urethra, and perineum/scrotum. Most of the parameters improved after urethroplasty, but up to 29% of patients reported worsening of perineal pain after surgery [584].

Sexual function should be evaluated by validated tools if not assessed in a PROM. The international index on erectile function (IIEF), SHIM, O´Leary Brief Male Sexual Function Inventory (BMFSI), SLQQ (Sexual Life Quality Questionnaire) and, Male Sexual Health Questionnaire (MSHQ) have all been used after urethroplasties for evaluation of erectile and ejaculatory functions. Other non-validated tools were suggested such as the Post-Urethroplasty Sexual Questionnaire (PUSQ) [585] or specific questionnaires for genital appearance (length, curvature) or sensitivity [586].

Summary of evidence	LE
Retrograde urethrography and urethrocystoscopy are able to identify anatomical success after a urethroplasty.	2a
A significant gap was demonstrated between objective and subjective outcomes after urethroplasties. PROM questionnaires are specific tools to assess subjective outcomes and patient satisfaction after urethroplasty surgeries.	2a
Validated questionnaires proved useful to assess the consequences of urethral surgery on sexual function.	2a

Recommendations	Strength rating
Use cystoscopy or retrograde urethrography to assess anatomic success after urethroplasty surgery.	Weak
Use PROM questionnaires to assess subjective outcomes and patient satisfaction.	Strong
Use validated questionnaires to evaluate sexual function after urethral stricture surgeries.	Strong

11.4 Ideal follow-up interval after urethral surgery

The optimal follow-up strategy must allow for an objective determination of anatomic and functional outcomes to assess surgical success whilst avoiding excessive invasive testing that leads to unnecessary cost, discomfort, anxiety, and risk [560].

After anterior urethroplasty, 21% of recurrences are clinically evident, and cystoscopically confirmed, after three months [587] and 96% after one year [569]. Early recurrences are more frequent in patients with LS and older age, in longer strictures and when skin grafts were used [587].

11.5 Length of follow-up after urethral surgery

The median time of recurrence after bulbar urethroplasty is approximately ten months [334]. In case series, between 55.4% [587] and 96% [569, 572] of all recurrences are detected during the first year of follow-up after urethral surgery. Twenty-three percent of bulbar stricture recurrences are detected during the second year of follow-up, and the percentage of recurrences decreases after the second year [346].

On the other hand, long-term follow-up studies highlighted the role of length of follow-up as a predictor for stricture recurrence after bulbar urethroplasty [346, 588]. Late recurrences – later than five years after urethroplasty – could be observed in up to 15% of cases [144, 331, 346]. This should be considered mainly after augmentation urethroplasties, especially in case skin grafts were used [571]. Certainly, patients should be instructed to seek urological evaluation if they experience late recurrent symptoms [588].

11.6 Risk-stratified proposals during follow-up after urethral surgery

Cost of follow-up after urethroplasty is higher in the first year after the procedure [589]. In a literature review it ranged between 205 to 1,784 US Dollars, with higher costs associated to posterior urethral repairs [589]. As the risk of recurrence and side effects are related to the type of stricture and urethroplasty, a different follow-up schedule was proposed and shown to be cost-effective in the USA, potentially saving up to 85% of costs after five years [561]:

- Urethroplasties with a low risk of recurrence (EPA urethroplasty without history of radiotherapy, hypospadias, or LS features) could be safely followed up based on monitoring of symptoms, using self-administered IPSS questionnaire, every three months for one year, and annually thereafter.
- Urethroplasties with standard risk of recurrence (urethroplasty using grafts, flaps, and/or post-irradiation, hypospadias and/or LS patients) could combine IPSS questionnaire + flowmetry every three months for one year, and annually thereafter. Additionally, RUG at three and twelve months should be performed.

In this protocol, urethrocystoscopy is only performed if required [561]. Another suggested follow-up protocol includes urethrocystoscopy or RUG/VCUG at three months post-operatively, in order to rule out early failures, especially in case of graft use. If there is evidence of good anatomical outcome in these tests, flowmetry and questionnaire results at three months should be considered as the new baseline. Thereafter, follow-up could be safely and routinely performed with non-invasive tests (flowmetry – evaluating Q_{max} and the shape of curve – and questionnaires). Any deterioration should be further investigated with a urethrocystoscopy [577].

A recently suggested protocol also included assessment of LUTS, sexual function (erectile and ejaculatory), and LUT pain, that need to be compared with pre-operative findings which should include a PROM questionnaire [560]. Cystoscopy and flowmetry should be performed between three to six months postoperatively, and flowmetry findings should be considered as the new baseline for longitudinal follow-up. Future significant decline (25-30%) in Q_{max} or Q_{max} - (average flow rate) should trigger new cystoscopy to rule out anatomic recurrence, even in patients who are symptom-free [560]. A routine cystoscopy at twelve to fifteen months should be performed at the surgeon's discretion, based on risk assessment of three aspects: higher-risk patients, evidence of partial urethral narrowing at three-month assessment, low-volume surgeons [560].

Summary of evidence	LE
The higher percentage of recurrences presents during the first twelve months, after urethroplasty surgery.	2a
Risk-adjusted follow-up protocols are cost-effective and safe for the patients.	3

Recommendations	Strength rating
Offer a routine follow-up of at least one year after urethroplasty.	Strong
Adopt a risk-adjusted follow-up protocol.	Weak

11.7 Follow-up protocol proposal after urethroplasty

11.7.1 Surgeries with low risk of recurrence

- Anastomotic urethroplasties in the bulbar/(bulbo)membranous segment with no history of radiotherapy, hypospadias, or balanitis xerotica obliterans (BXO)/LS features.

Table 11.3: Follow-up protocol for urethroplasty with low risk of recurrence

Surgery	3 months	12 months	24 months*
Uroflowmetry	+	+	+
PROM (incl. sexual function)	+	+	+
Anatomic evaluation: (Urethrocystoscopy/RUG-VCUG)	+**	On indication	On indication

**Follow-up could be discontinued after two years, advising the patient to seek urological evaluation if symptoms worsen. Academic centres could increase the length of follow-up for research purposes.*
***The Panel suggests performing an anatomic assessment at three months.*

11.7.2 Surgical management options with standard risk of recurrence

- Anastomotic urethroplasties in the bulbar segment with prior history of radiotherapy, hypospadias, or BXO/LS features;
- Penile urethroplasties;
- Non-traumatic posterior urethroplasties;
- Graft or/and flap – substitution – urethroplasties.

Table 11.4: Follow-up protocol for urethroplasty with standard risk of recurrence

Surgery	3 months	12 months	24 months	5 years *
Uroflowmetry	+	+	+	+
PROM (incl. sexual function)	+	+	+	+
Anatomic evaluation: (Urethrocystoscopy/ RUG-VCUG)	+	+	+	On indication

** Follow-up could be discontinued after five years, advising the patient to seek urological evaluation if symptoms worsen. A longer follow-up period should be considered after penile and substitution urethroplasties. Academic centres could increase the length of follow-up for research purposes.*

Please see Figure 11.1 for further guidance.

Figure 11.1: Follow-up after urethroplasty

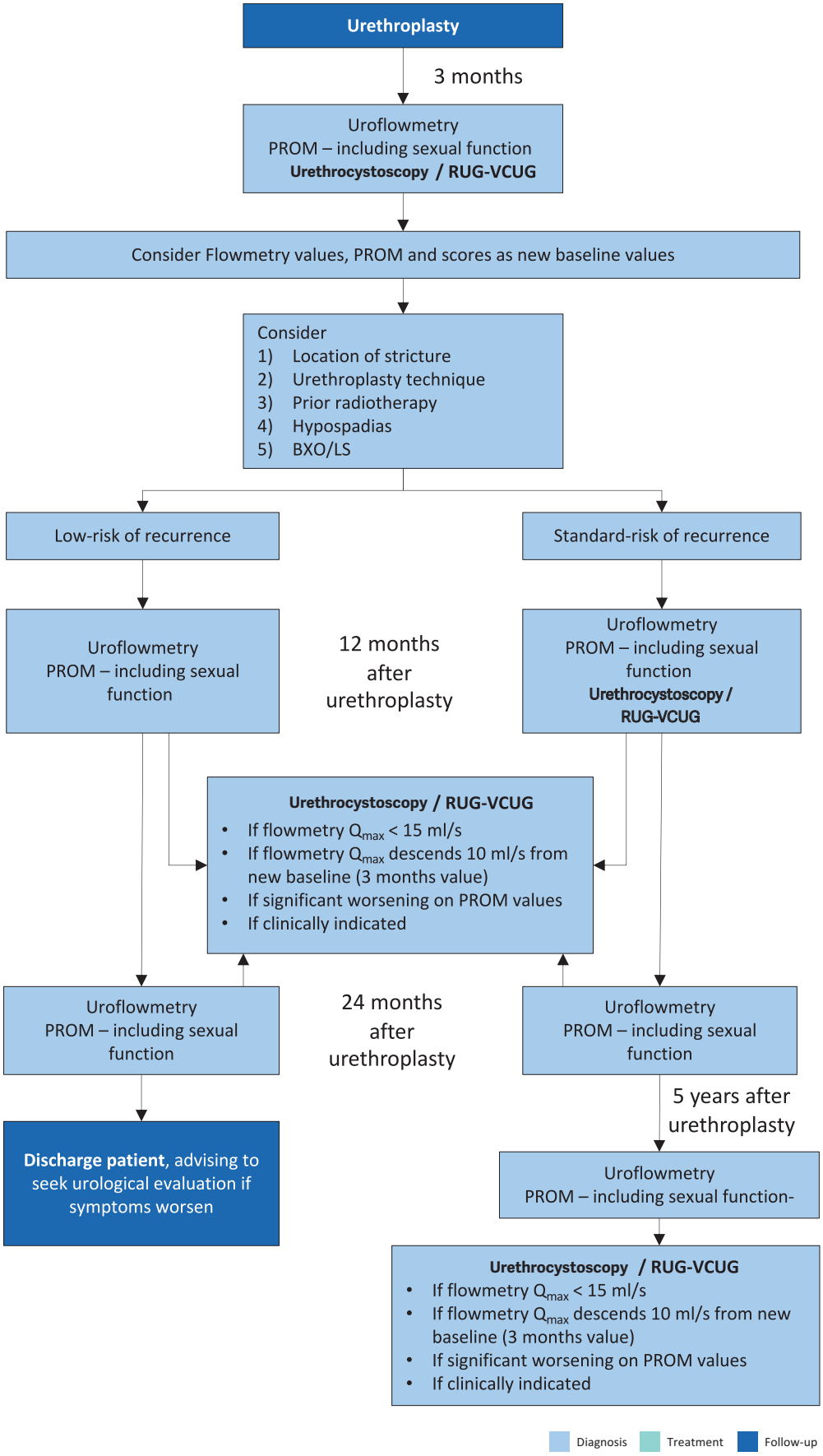

BXO = balanitis xerotica obliterans; LS = lichen sclerosus; PROM = patient reported outcome measure; Q_{max} = maximum flow rate; RUG = retrograde urethrography; VCUG = voiding cystourethrography.

12. REFERENCES

1. Guyatt, G.H., *et al*. What is "quality of evidence" and why is it important to clinicians? Bmj, 2008. 336: 995.
https://pubmed.ncbi.nlm.nih.gov/18456631/
2. Guyatt, G.H., *et al*. GRADE: an emerging consensus on rating quality of evidence and strength of recommendations. Bmj, 2008. 336: 924.
https://pubmed.ncbi.nlm.nih.gov/18436948/
3. Philips, C.B. Modified from Oxford Centre for Evidence-based Medicine Levels of Evidence (March 2009). 2014:Updated Jeremy Howick March 2009.
https://www.cebm.net/2009/06/oxford-centre-evidence-based-medicine-levels-evidence-march-2009/
4. Guyatt, G.H., *et al*. Going from evidence to recommendations. Bmj, 2008. 336: 1049.
https://pubmed.ncbi.nlm.nih.gov/18467413/
5. Hoebeke, P., *et al*. [Principles of wound healing as applied to urethra surgery]. Ann Urol (Paris), 1993. 27: 209.
https://pubmed.ncbi.nlm.nih.gov/8239546/
6. Esperto, F., *et al*. What is the role of single-stage oral mucosa graft urethroplasty in the surgical management of lichen sclerosus-related stricture disease in men? A systematic review. World J Urol, 2021.
https://pubmed.ncbi.nlm.nih.gov/34448008/
7. Barratt, R., *et al*. Free Graft Augmentation Urethroplasty for Bulbar Urethral Strictures: Which Technique Is Best? A Systematic Review. Eur Urol, 2021. 80: 57.
https://pubmed.ncbi.nlm.nih.gov/33875306/
8. Lumen, N., *et al*. European Association of Urology Guidelines on Urethral Stricture Disease (Part 1): Management of Male Urethral Stricture Disease. Eur Urol, 2021. 80: 190.
https://pubmed.ncbi.nlm.nih.gov/34059397/
9. Campos-Juanatey, F., *et al*. European Association of Urology Guidelines on Urethral Stricture Disease (Part 2): Diagnosis, Perioperative Management, and Follow-up in Males. Eur Urol, 2021. 80: 201.
https://pubmed.ncbi.nlm.nih.gov/34103180/
10. Riechardt, S., *et al*. European Association of Urology Guidelines on Urethral Stricture Disease Part 3: Management of Strictures in Females and Transgender Patients. Eur Urol Focus, 2021.
https://pubmed.ncbi.nlm.nih.gov/34393082/
11. Mundy, A.R., *et al*. Urethral trauma. Part I: introduction, history, anatomy, pathology, assessment and emergency management. BJU Int, 2011. 108: 310.
https://pubmed.ncbi.nlm.nih.gov/21771241/
12. Latini, J.M., *et al*. SIU/ICUD Consultation On Urethral Strictures: Epidemiology, etiology, anatomy, and nomenclature of urethral stenoses, strictures, and pelvic fracture urethral disruption injuries. Urology, 2014. 83: S1.
https://pubmed.ncbi.nlm.nih.gov/24210733/
13. Smith, A.L., *et al*. Female urethral strictures: successful management with long-term clean intermittent catheterization after urethral dilatation. BJU Int, 2006. 98: 96.
https://pubmed.ncbi.nlm.nih.gov/16831151/
14. Osman, N.I., *et al*. A systematic review of surgical techniques used in the treatment of female urethral stricture. Eur Urol, 2013. 64: 965.
https://pubmed.ncbi.nlm.nih.gov/23937829/
15. Singh, M., *et al*. Dorsal onlay vaginal graft urethroplasty for female urethral stricture. Indian J Urol, 2013. 29: 124.
https://pubmed.ncbi.nlm.nih.gov/23956514/
16. Montorsi, F., *et al*. Vestibular flap urethroplasty for strictures of the female urethra. Impact on symptoms and flow patterns. Urol Int, 2002. 69: 12.
https://pubmed.ncbi.nlm.nih.gov/12119432/
17. Alwaal, A., *et al*. Epidemiology of urethral strictures. Transl Androl Urol, 2014. 3: 209.
https://pubmed.ncbi.nlm.nih.gov/26813256/
18. Palminteri, E., *et al*. Contemporary urethral stricture characteristics in the developed world. Urology, 2013. 81: 191.
https://pubmed.ncbi.nlm.nih.gov/23153951/
19. Groutz, A., *et al*. Bladder outlet obstruction in women: definition and characteristics. Neurourol Urodyn, 2000. 19: 213.
https://pubmed.ncbi.nlm.nih.gov/10797578/

20. Chuang, F.C., *et al*. Lower Urinary Tract Symptoms and Video-Urodynamic Characteristics of Women with Clinically Unsuspected Bladder Outlet Obstruction. Low Urin Tract Symptoms, 2013. 5: 23.
https://pubmed.ncbi.nlm.nih.gov/26663244/
21. Malde, S., *et al*. Female bladder outlet obstruction: Common symptoms masking an uncommon cause. Low Urin Tract Symptoms, 2019. 11: 72.
https://pubmed.ncbi.nlm.nih.gov/28990728/
22. Nitti, V.W., *et al*. Diagnosing bladder outlet obstruction in women. J Urol, 1999. 161: 1535.
https://pubmed.ncbi.nlm.nih.gov/10210391/
23. Kuo, H.C. Videourodynamic characteristics and lower urinary tract symptoms of female bladder outlet obstruction. Urology, 2005. 66: 1005.
https://pubmed.ncbi.nlm.nih.gov/16286113/
24. Santucci, R.A., *et al*. Office dilation of the female urethra: a quality of care problem in the field of urology. J Urol, 2008. 180: 2068.
https://pubmed.ncbi.nlm.nih.gov/18804232/
25. Snodgrass, W.T., *et al*. Management of Urethral Strictures After Hypospadias Repair. Urol Clin North Am, 2017. 44: 105.
https://pubmed.ncbi.nlm.nih.gov/27908364/
26. Stein, D.M., *et al*. A geographic analysis of male urethral stricture aetiology and location. BJU Int, 2013. 112: 830.
https://pubmed.ncbi.nlm.nih.gov/23253867/
27. Dielubanza, E.J., *et al*. Distal urethroplasty for fossa navicularis and meatal strictures. Transl Androl Urol, 2014. 3: 163.
https://pubmed.ncbi.nlm.nih.gov/26816765/
28. Mangera, A., *et al*. Urethral stricture disease. Surgery (Oxford), 2011. 29: 272.
http://www.sciencedirect.com/science/article/pii/S0263931911000603
29. Daneshvar, M., *et al*. Surgical Management of Fossa Navicularis and Distal Urethral Strictures. Curr Urol Rep, 2018. 19: 43.
https://pubmed.ncbi.nlm.nih.gov/29667080/
30. Tonkin, J.B., *et al*. Management of distal anterior urethral strictures. Nat Rev Urol, 2009. 6: 533.
https://pubmed.ncbi.nlm.nih.gov/19736550/
31. Nassiri, N., *et al*. Urethral complications after gender reassignment surgery: a systematic review. Int J Impot Res, 2020. 33: 793.
https://pubmed.ncbi.nlm.nih.gov/32488213/
32. Bertrand, L.A., *et al*. Lower urinary tract pain and anterior urethral stricture disease: prevalence and effects of urethral reconstruction. J Urol, 2015. 193: 184.
https://pubmed.ncbi.nlm.nih.gov/25046621/
33. Lubahn, J.D., *et al*. Poor quality of life in patients with urethral stricture treated with intermittent self-dilation. J Urol, 2014. 191: 143.
https://pubmed.ncbi.nlm.nih.gov/23820057/
34. Greenwell, T.J., *et al*. Repeat urethrotomy and dilation for the treatment of urethral stricture are neither clinically effective nor cost-effective. J Urol, 2004. 172: 275.
https://pubmed.ncbi.nlm.nih.gov/15201793/
35. Santucci, R.A., *et al*. Male urethral stricture disease. J Urol, 2007. 177: 1667.
https://pubmed.ncbi.nlm.nih.gov/17437780/
36. Lumen, N., *et al*. Etiology of urethral stricture disease in the 21st century. J Urol, 2009. 182: 983.
https://pubmed.ncbi.nlm.nih.gov/19616805/
37. Lazzeri, M.S., S. Guazzoni, G, Barbaglu, G. Incidence, Causes, and Complications of Urethral Stricture Disease. Eur Urol Suppl, 2016. 15: 2.
https://www.sciencedirect.com/science/article/abs/pii/S1569905615000652
38. Heyns, C., *et al*. Etiology of male urethral strictures-Evaluation of temporal changes at a single center, and review of the literature. African Journal of Urology, 2012. 18: 4.
https://www.sciencedirect.com/science/article/pii/S1110570412000100
39. Depasquale, I., *et al*. The treatment of balanitis xerotica obliterans. BJU Int, 2000. 86: 459.
https://pubmed.ncbi.nlm.nih.gov/10971272/
40. Regauer, S. Immune dysregulation in lichen sclerosus. Eur J Cell Biol, 2005. 84: 273.
https://pubmed.ncbi.nlm.nih.gov/15819407/
41. Mallon, E., *et al*. Circumcision and genital dermatoses. Arch Dermatol, 2000. 136: 350.
https://pubmed.ncbi.nlm.nih.gov/10724196/

42. Hofer, M.D., *et al*. Lichen sclerosus in men is associated with elevated body mass index, diabetes mellitus, coronary artery disease and smoking. World J Urol, 2014. 32: 105.
https://pubmed.ncbi.nlm.nih.gov/23633127/
43. Erickson, B.A., *et al*. Understanding the Relationship between Chronic Systemic Disease and Lichen Sclerosus Urethral Strictures. J Urol, 2016. 195: 363.
https://pubmed.ncbi.nlm.nih.gov/26343349/
44. Bjekic, M., *et al*. Risk factors for genital lichen sclerosus in men. Br J Dermatol, 2011. 164: 325.
https://pubmed.ncbi.nlm.nih.gov/20973765/
45. Falcone, M., *et al*. Current Management of Penile Fracture: An Up-to-Date Systematic Review. Sex Med Rev, 2018. 6: 253.
https://pubmed.ncbi.nlm.nih.gov/28874325/
46. Barratt, R.C., *et al*. Pelvic fracture urethral injury in males-mechanisms of injury, management options and outcomes. Transl Androl Urol, 2018. 7: S29.
https://pubmed.ncbi.nlm.nih.gov/29644168/
47. Tausch, T.J., *et al*. Gunshot wound injuries of the prostate and posterior urethra: reconstructive armamentarium. J Urol, 2007. 178: 1346.
https://pubmed.ncbi.nlm.nih.gov/17706720/
48. Fenton, A.S., *et al*. Anterior urethral strictures: etiology and characteristics. Urology, 2005. 65: 1055.
https://pubmed.ncbi.nlm.nih.gov/15913734/
49. Hollingsworth, J.M., *et al*. Determining the noninfectious complications of indwelling urethral catheters: a systematic review and meta-analysis. Ann Intern Med, 2013. 159: 401.
https://pubmed.ncbi.nlm.nih.gov/24042368/
50. Davis, N.F., *et al*. Long-term outcomes of urethral catheterisation injuries: a prospective multi-institutional study. World J Urol, 2020. 38: 473.
https://pubmed.ncbi.nlm.nih.gov/31020421/
51. Kashefi, C., *et al*. Incidence and prevention of iatrogenic urethral injuries. J Urol, 2008. 179: 2254.
https://pubmed.ncbi.nlm.nih.gov/18423712/
52. Davis, N.F., *et al*. Incidence, Cost, Complications and Clinical Outcomes of Iatrogenic Urethral Catheterization Injuries: A Prospective Multi-Institutional Study. J Urol, 2016. 196: 1473.
https://pubmed.ncbi.nlm.nih.gov/27317985/
53. Daneshgari, F., *et al*. Evidence-based multidisciplinary practice: improving the safety and standards of male bladder catheterization. Medsurg Nurs, 2002. 11: 236.
https://pubmed.ncbi.nlm.nih.gov/12830746/
54. Ghaffary, C., *et al*. A practical approach to difficult urinary catheterizations. Curr Urol Rep, 2013. 14: 565.
https://pubmed.ncbi.nlm.nih.gov/23959835/
55. Davoodian, P., *et al*. Inappropriate use of urinary catheters and its common complications in different hospital wards. Saudi J Kidney Dis Transpl, 2012. 23: 63.
https://pubmed.ncbi.nlm.nih.gov/22237221/
56. Fernandez-Ruiz, M., *et al*. Inappropriate use of urinary catheters in patients admitted to medical wards in a university hospital. Enferm Infecc Microbiol Clin, 2013. 31: 523.
https://pubmed.ncbi.nlm.nih.gov/23601704/
57. Fakih, M.G., *et al*. Effect of establishing guidelines on appropriate urinary catheter placement. Acad Emerg Med, 2010. 17: 337.
https://pubmed.ncbi.nlm.nih.gov/20370769/
58. Fakih, M.G., *et al*. Avoiding potential harm by improving appropriateness of urinary catheter use in 18 emergency departments. Ann Emerg Med, 2014. 63: 761.
https://pubmed.ncbi.nlm.nih.gov/24656760/
59. Shimoni, Z., *et al*. Will more restrictive indications decrease rates of urinary catheterisation? An historical comparative study. BMJ Open, 2012. 2: e000473.
https://pubmed.ncbi.nlm.nih.gov/22403341/
60. Thomas, A.Z., *et al*. Avoidable iatrogenic complications of urethral catheterization and inadequate intern training in a tertiary-care teaching hospital. BJU Int, 2009. 104: 1109.
https://pubmed.ncbi.nlm.nih.gov/19338562/
61. Manalo, M., Jr., *et al*. Medical interns' knowledge and training regarding urethral catheter insertion and insertion-related urethral injury in male patients. BMC Med Educ, 2011. 11: 73.
https://pubmed.ncbi.nlm.nih.gov/21951692/
62. Laborde, E., *et al*. A Nurse-Driven Protocol for Foley Catheter Utilization Decreases the Incidence of Traumatic Foley Catheterization. Ochsner J, 2021. 21: 41.
https://pubmed.ncbi.nlm.nih.gov/33828425/

63. Davis, N.F., *et al*. Preventing Urethral Trauma from Inadvertent Inflation of Catheter Balloon in the Urethra during Catheterization: Evaluation of a Novel Safety Syringe after Correlating Trauma with Urethral Distension and Catheter Balloon Pressure. J Urol, 2015. 194: 1138.
https://pubmed.ncbi.nlm.nih.gov/25711195/
64. Davis, N.F., *et al*. Clinical Evaluation of a Safety-device to Prevent Urinary Catheter Inflation Related Injuries. Urology, 2018. 115: 179.
https://pubmed.ncbi.nlm.nih.gov/29501711/
65. Bugeja, S., *et al*. A new urethral catheterisation device (UCD) to manage difficult urethral catheterisation. World J Urol, 2019. 37: 595.
https://pubmed.ncbi.nlm.nih.gov/30251050/
66. Yuminaga, Y., *et al*. Multi-centre, prospective evaluation of the Seldinger technique for difficult male urethral catheter insertions by non-urology trained doctors. BJU Int, 2017. 120 Suppl 3: 21.
https://pubmed.ncbi.nlm.nih.gov/28872750/
67. Yuruk, E., *et al*. Catheter dwell time and diameter affect the recurrence rates after internal urethrotomy. Turk J Urol, 2016. 42: 184.
https://pubmed.ncbi.nlm.nih.gov/27635294/
68. Liss, M.A., *et al*. Preventing perioperative complications of robotic-assisted radical prostatectomy. Urology, 2013. 81: 319.
https://pubmed.ncbi.nlm.nih.gov/23374792/
69. Ferrie, B.G., *et al*. Comparison of silicone and latex catheters in the development of urethral stricture after cardiac surgery. Br J Urol, 1986. 58: 549.
https://pubmed.ncbi.nlm.nih.gov/3490896/
70. Nacey, J.N., *et al*. Catheter-induced urethritis: a comparison between latex and silicone catheters in a prospective clinical trial. Br J Urol, 1985. 57: 325.
https://pubmed.ncbi.nlm.nih.gov/3891005/
71. Lam, T.B., *et al*. Types of indwelling urethral catheters for short-term catheterisation in hospitalised adults. Cochrane Database Syst Rev, 2014: CD004013.
https://pubmed.ncbi.nlm.nih.gov/25248140/
72. Robertson, G.S., *et al*. Effect of catheter material on the incidence of urethral strictures. Br J Urol, 1991. 68: 612.
https://pubmed.ncbi.nlm.nih.gov/1773292/
73. Goodwin, M.I., *et al*. Meatal strictures after transurethral prostatectomy using latex or polyvinyl chloride three-way catheters. Ann R Coll Surg Engl, 1990. 72: 125.
https://pubmed.ncbi.nlm.nih.gov/2185681/
74. Hart, A.J., *et al*. Incidence of urethral stricture after transurethral resection of prostate. Effects of urinary infection, urethral flora, and catheter material and size. Urology, 1981. 18: 588.
https://pubmed.ncbi.nlm.nih.gov/7314361/
75. Lawrence, E.L., *et al*. Materials for urinary catheters: a review of their history and development in the UK. Med Eng Phys, 2005. 27: 443.
https://pubmed.ncbi.nlm.nih.gov/15990061/
76. Cornu, J.N., *et al*. A Systematic Review and Meta-analysis of Functional Outcomes and Complications Following Transurethral Procedures for Lower Urinary Tract Symptoms Resulting from Benign Prostatic Obstruction: An Update. Eur Urol, 2015. 67: 1066.
https://pubmed.ncbi.nlm.nih.gov/24972732/
77. Chen, M.L., *et al*. Urethral Strictures and Stenoses Caused by Prostate Therapy. Rev Urol, 2016. 18: 90.
https://pubmed.ncbi.nlm.nih.gov/27601967/
78. Michielsen, D.P., *et al*. Urethral strictures and bipolar transurethral resection in saline of the prostate: fact or fiction? J Endourol, 2010. 24: 1333.
https://pubmed.ncbi.nlm.nih.gov/20583960/
79. Balbay, M.D., *et al*. Development of urethral stricture after transurethral prostatectomy: a retrospective study. Int Urol Nephrol, 1992. 24: 49.
https://pubmed.ncbi.nlm.nih.gov/1378047/
80. Rassweiler, J., *et al*. Complications of transurethral resection of the prostate (TURP)--incidence, management, and prevention. Eur Urol, 2006. 50: 969.
https://pubmed.ncbi.nlm.nih.gov/16469429/
81. Robinson, H.P., *et al*. Postoperative contracture of the vesical neck. II. Experimental production of contractures in dogs: transurethral series. J Urol, 1962. 87: 610.
https://pubmed.ncbi.nlm.nih.gov/14492908/

82. Lumen, N., *et al*. Challenging non-traumatic posterior urethral strictures treated with urethroplasty: a preliminary report. Int Braz J Urol, 2009. 35: 442.
https://pubmed.ncbi.nlm.nih.gov/19719860/
83. Gür, A., *et al*. Risk Factors for Early Urethral Stricture After Mono-Polar Transurethral Prostate Resection: A Single-Center Experience. Cureus, 2021. 13: e19663.
https://pubmed.ncbi.nlm.nih.gov/34976457/
84. Tao, H., *et al*. Analysis of risk factors leading to postoperative urethral stricture and bladder neck contracture following transurethral resection of prostate. Int Braz J Urol, 2016. 42: 302.
https://pubmed.ncbi.nlm.nih.gov/27256185/
85. Tan, G.H., *et al*. Urethral strictures after bipolar transurethral resection of prostate may be linked to slow resection rate. Investig Clin Urol, 2017. 58: 186.
https://pubmed.ncbi.nlm.nih.gov/28480344/
86. Gunes, M., *et al*. Does resectoscope size play a role in formation of urethral stricture following transurethral prostate resection? Int Braz J Urol, 2015. 41: 744.
https://pubmed.ncbi.nlm.nih.gov/26401868/
87. Park, J.K., *et al*. Is warm temperature necessary to prevent urethral stricture in combined transurethral resection and vaporization of prostate? Urology, 2009. 74: 125.
https://pubmed.ncbi.nlm.nih.gov/19395006/
88. Varkarakis, J., *et al*. Long-term morbidity and mortality of transurethral prostatectomy: a 10-year follow-up. Prostate, 2004. 58: 248.
https://pubmed.ncbi.nlm.nih.gov/14743463/
89. Lee, Y.H., *et al*. Comprehensive study of bladder neck contracture after transurethral resection of prostate. Urology, 2005. 65: 498.
https://pubmed.ncbi.nlm.nih.gov/15780363/
90. Lan, Y., *et al*. Thulium (Tm:YAG) laser vaporesection of prostate and bipolar transurethral resection of prostate in patients with benign prostate hyperplasia: a systematic review and meta-analysis. Lasers Med Sci, 2018. 33: 1411.
https://pubmed.ncbi.nlm.nih.gov/29947009/
91. Pirola, G.M., *et al*. Urethral stricture following endoscopic prostate surgery: a systematic review and meta-analysis of prospective, randomized trials. World J Urol, 2022. 40: 1391.
https://pubmed.ncbi.nlm.nih.gov/35152322/
92. Sciarra, A., *et al*. Use of cyclooxygenase-2 inhibitor for prevention of urethral strictures secondary to transurethral resection of the prostate. Urology, 2005. 66: 1218.
https://pubmed.ncbi.nlm.nih.gov/16360446/
93. Bailey, M.J., *et al*. The role of internal urethrotomy in the prevention of urethral stricture following transurethral resection of prostate. Br J Urol, 1979. 51: 28.
https://pubmed.ncbi.nlm.nih.gov/465957/
94. Steenfos, H.H., *et al*. The importance of internal urethrotomy a.m. Otis for the incidence of urethral stricture following transurethral prostatectomy. Int Urol Nephrol, 1988. 20: 55.
https://pubmed.ncbi.nlm.nih.gov/3360588/
95. Schultz, A., *et al*. Prevention of urethral stricture formation after transurethral resection of the prostate: a controlled randomized study of Otis urethrotomy versus urethral dilation and the use of the polytetrafluoroethylene coated versus the uninsulated metal sheath. J Urol, 1989. 141: 73.
https://pubmed.ncbi.nlm.nih.gov/2642313/
96. Nielsen, K.K., *et al*. Does internal urethrotomy prevent urethral stricture after transurethral prostatectomy. Early and late results. Eur Urol, 1989. 16: 258.
https://pubmed.ncbi.nlm.nih.gov/2670580/
97. Nielsen, K.K., *et al*. Urethral stricture following transurethral prostatectomy. Urology, 1990. 35: 18.
https://pubmed.ncbi.nlm.nih.gov/2404365/
98. Faul, P. Video TUR: raising the gold standard. New aspects, techniques and tendencies to minimize invasiveness. Eur Urol, 1993. 24: 256.
https://pubmed.ncbi.nlm.nih.gov/8375449/
99. Rocco, N.R., *et al*. An update on best practice in the diagnosis and management of post-prostatectomy anastomotic strictures. Ther Adv Urol, 2017. 9: 99.
https://pubmed.ncbi.nlm.nih.gov/28588647/
100. Browne, B.M., *et al*. Management of Urethral Stricture and Bladder Neck Contracture Following Primary and Salvage Treatment of Prostate Cancer. Curr Urol Rep, 2017. 18: 76.
https://pubmed.ncbi.nlm.nih.gov/28776126/

101. Herschorn, S., *et al*. SIU/ICUD Consultation on Urethral Strictures: Posterior urethral stenosis after treatment of prostate cancer. Urology, 2014. 83: S59.
https://pubmed.ncbi.nlm.nih.gov/24361008/
102. Tewari, A., *et al*. Positive surgical margin and perioperative complication rates of primary surgical treatments for prostate cancer: a systematic review and meta-analysis comparing retropubic, laparoscopic, and robotic prostatectomy. Eur Urol, 2012. 62: 1.
https://pubmed.ncbi.nlm.nih.gov/22405509/
103. Sujenthiran, A., *et al*. National cohort study comparing severe medium-term urinary complications after robot-assisted vs laparoscopic vs retropubic open radical prostatectomy. BJU Int, 2018. 121: 445.
https://pubmed.ncbi.nlm.nih.gov/29032582/
104. Hu, J.C., *et al*. Comparative effectiveness of minimally invasive vs open radical prostatectomy. JAMA, 2009. 302: 1557.
https://pubmed.ncbi.nlm.nih.gov/19826025/
105. Almatar, A., *et al*. Effect of radical prostatectomy surgeon volume on complication rates from a large population-based cohort. Can Urol Assoc J, 2016. 10: 45.
https://pubmed.ncbi.nlm.nih.gov/26977206/
106. Patel, V.R., *et al*. Robotic radical prostatectomy in the community setting--the learning curve and beyond: initial 200 cases. J Urol, 2005. 174: 269.
https://pubmed.ncbi.nlm.nih.gov/15947662/
107. Spector, B.L., *et al*. Bladder Neck Contracture Following Radical Retropubic versus Robotic-Assisted Laparoscopic Prostatectomy. Curr Urol, 2017. 10: 145.
https://pubmed.ncbi.nlm.nih.gov/28878598/
108. Gillitzer, R., *et al*. Single center comparison of anastomotic strictures after radical perineal and radical retropubic prostatectomy. Urology, 2010. 76: 417.
https://pubmed.ncbi.nlm.nih.gov/19969328/
109. Hu, J.C., *et al*. Role of surgeon volume in radical prostatectomy outcomes. J Clin Oncol, 2003. 21: 401.
https://pubmed.ncbi.nlm.nih.gov/12560426/
110. Srougi, M., *et al*. The influence of bladder neck mucosal eversion and early urinary extravasation on patient outcome after radical retropubic prostatectomy: a prospective controlled trial. BJU Int, 2005. 95: 757.
https://pubmed.ncbi.nlm.nih.gov/15794777/
111. Kowalewski, K.F., *et al*. Interrupted versus Continuous Suturing for Vesicourethral Anastomosis During Radical Prostatectomy: A Systematic Review and Meta-analysis. Eur Urol Focus, 2019. 5: 980.
https://pubmed.ncbi.nlm.nih.gov/29907547/
112. Bai, Y., *et al*. Assessing the Impact of Barbed Suture on Vesicourethral Anastomosis During Minimally Invasive Radical Prostatectomy: A Systematic Review and Meta-analysis. Urology, 2015. 85: 1368.
https://pubmed.ncbi.nlm.nih.gov/25868736/
113. Awad, M.A., *et al*. Prostate cancer radiation and urethral strictures: a systematic review and meta-analysis. Prostate Cancer Prostatic Dis, 2018. 21: 168.
https://pubmed.ncbi.nlm.nih.gov/29296018/
114. Moltzahn, F., *et al*. Urethral strictures after radiation therapy for prostate cancer. Investig Clin Urol, 2016. 57: 309.
https://pubmed.ncbi.nlm.nih.gov/27617311/
115. Dosanjh, A., *et al*. High-intensity Focused Ultrasound for the Treatment of Prostate Cancer: A National Cohort Study Focusing on the Development of Stricture and Fistulae. Eur Urol Focus, 2021. 7: 340.
https://pubmed.ncbi.nlm.nih.gov/31924529/
116. Hofer, M.D., *et al*. Treatment of Radiation-Induced Urethral Strictures. Urol Clin North Am, 2017. 44: 87.
https://pubmed.ncbi.nlm.nih.gov/27908375/
117. Sullivan, L., *et al*. Urethral stricture following high dose rate brachytherapy for prostate cancer. Radiother Oncol, 2009. 91: 232.
https://pubmed.ncbi.nlm.nih.gov/19097660/
118. Hindson, B.R., *et al*. Urethral strictures following high-dose-rate brachytherapy for prostate cancer: analysis of risk factors. Brachytherapy, 2013. 12: 50.
https://pubmed.ncbi.nlm.nih.gov/22561217/

119. Kowalczyk, K.J., *et al*. Optimal timing of early versus delayed adjuvant radiotherapy following radical prostatectomy for locally advanced prostate cancer. Urol Oncol, 2014. 32: 303.
https://pubmed.ncbi.nlm.nih.gov/24321259/
120. Seppenwoolde, Y., *et al*. HDR prostate monotherapy: dosimetric effects of implant deformation due to posture change between TRUS- and CT-imaging. Radiother Oncol, 2008. 86: 114.
https://pubmed.ncbi.nlm.nih.gov/18054101/
121. Mohammed, N., *et al*. Comparison of acute and late toxicities for three modern high-dose radiation treatment techniques for localized prostate cancer. Int J Radiat Oncol Biol Phys, 2012. 82: 204.
https://pubmed.ncbi.nlm.nih.gov/21167653/
122. Lumen, N., *et al*. Urethroplasty for failed hypospadias repair: a matched cohort analysis. J Pediatr Urol, 2011. 7: 170.
https://pubmed.ncbi.nlm.nih.gov/20965140/
123. Vetterlein, M.W., *et al*. Anterior Urethral Strictures in Children: Disease Etiology and Comparative Effectiveness of Endoscopic Treatment vs. Open Surgical Reconstruction. Front Pediatr, 2019. 7: 5.
https://pubmed.ncbi.nlm.nih.gov/30805317/
124. Cotter, K.J., *et al*. Trends in Urethral Stricture Disease Etiology and Urethroplasty Technique From a Multi-institutional Surgical Outcomes Research Group. Urology, 2019. 130: 167.
https://pubmed.ncbi.nlm.nih.gov/30880075/
125. Simonato, A., *et al*. Vaginal flap urethroplasty for wide female stricture disease. J Urol, 2010. 184: 1381.
https://pubmed.ncbi.nlm.nih.gov/20727538/
126. Sharma, G.K., *et al*. Dorsal onlay lingual mucosal graft urethroplasty for urethral strictures in women. BJU Int, 2010. 105: 1309.
https://pubmed.ncbi.nlm.nih.gov/19874307/
127. Onol, F.F., *et al*. Techniques and results of urethroplasty for female urethral strictures: our experience with 17 patients. Urology, 2011. 77: 1318.
https://pubmed.ncbi.nlm.nih.gov/21459417/
128. Blaivas, J.G., *et al*. Management of urethral stricture in women. J Urol, 2012. 188: 1778.
https://pubmed.ncbi.nlm.nih.gov/22998912/
129. Rijal, A., *et al*. Bladder outflow problems in females. Nepal Med Coll J, 2013. 15: 46.
https://pubmed.ncbi.nlm.nih.gov/24592794/
130. Xu, Y.M., *et al*. A rationale for procedure selection to repair female urethral stricture associated with urethrovaginal fistulas. J Urol, 2013. 189: 176.
https://pubmed.ncbi.nlm.nih.gov/23174242/
131. Kowalik, C., *et al*. Intermediate outcomes after female urethral reconstruction: graft vs flap. Urology, 2014. 83: 1181.
https://pubmed.ncbi.nlm.nih.gov/24674113/
132. Onol, F.F., *et al*. Ventral inlay labia minora graft urethroplasty for the management of female urethral strictures. Urology, 2014. 83: 460.
https://pubmed.ncbi.nlm.nih.gov/24210559/
133. Spilotros, M., *et al*. Female urethral stricture: a contemporary series. World J Urol, 2017. 35: 991.
https://pubmed.ncbi.nlm.nih.gov/27704202/
134. Powell, C.R., *et al*. Dorsal Onlay Buccal Urethroplasty in the Female is Associated with High Quality of Life Using Validated Lower Urinary Tract Symptom Instruments. Urology Practice, 2017. 4: 48.
https://www.auajournals.org/doi/abs/10.1016/j.urpr.2016.02.002
135. Mukhtar, B.M.B., *et al*. Ventral-onlay buccal mucosa graft substitution urethroplasty for urethral stricture in women. BJU Int, 2017. 120: 710.
https://pubmed.ncbi.nlm.nih.gov/28749039/
136. Tao, T.T.X., *et al*. Novel surgical technique for female distal urethral stricture disease: an evaluation of efficacy and safety compared with urethral dilatation. Int J Clin Exp Med, 2018. 11: 12002.
http://www.ijcem.com/V11_No11.html
137. Romero-Maroto, J., *et al*. Lateral-based Anterior Vaginal Wall Flap in the Treatment of Female Urethral Stricture: Efficacy and Safety. Eur Urol, 2018. 73: 123.
https://pubmed.ncbi.nlm.nih.gov/27692474/
138. West, C., *et al*. Female urethroplasty: contemporary thinking. World J Urol, 2019. 37: 619.
https://pubmed.ncbi.nlm.nih.gov/30456711/
139. Rehder, P., *et al*. Dorsal urethroplasty with labia minora skin graft for female urethral strictures. BJU Int, 2010. 106: 1211.
https://pubmed.ncbi.nlm.nih.gov/20230383/

140. Wood, D.N., *et al*. Peritoneal and perineal anatomy and surgical approaches. BJU Int, 2004. 94: 719.
https://pubmed.ncbi.nlm.nih.gov/15329090/
141. Terlecki, R.P., *et al*. Grafts are unnecessary for proximal bulbar reconstruction. J Urol, 2010. 184: 2395.
https://pubmed.ncbi.nlm.nih.gov/20952000/
142. John, A., *et al*. Classification systems for anterior urethral stricture disease in men: a systematic review. World J Urol, 2021. 39: 761.
https://pubmed.ncbi.nlm.nih.gov/32451616/
143. Baradaran, N., *et al*. Clinical significance of cystoscopic urethral stricture recurrence after anterior urethroplasty: a multi-institution analysis from Trauma and Urologic Reconstructive Network of Surgeons (TURNS). World J Urol, 2019.
https://pubmed.ncbi.nlm.nih.gov/30712091/
144. Purohit, R.S., *et al*. Natural History of Low-stage Urethral Strictures. Urology, 2017. 108: 180.
https://pubmed.ncbi.nlm.nih.gov/28552818/
145. Erickson, B.A., *et al*. Multi-institutional 1-year bulbar urethroplasty outcomes using a standardized prospective cystoscopic follow-up protocol. Urology, 2014. 84: 213.
https://pubmed.ncbi.nlm.nih.gov/24837453/
146. Palminteri, E., *et al*. Two-sided dorsal plus ventral oral graft bulbar urethroplasty: long-term results and predictive factors. Urology, 2015. 85: 942.
https://pubmed.ncbi.nlm.nih.gov/25817122/
147. Waterschoot, M., *et al*. Treatment of Urethral Strictures in Transmasculine Patients. J Clin Med, 2021. 10.
https://pubmed.ncbi.nlm.nih.gov/34501359/
148. Rourke, K., *et al*. The clinical spectrum of the presenting signs and symptoms of anterior urethral stricture: detailed analysis of a single institutional cohort. Urology, 2012. 79: 1163.
https://pubmed.ncbi.nlm.nih.gov/22446349/
149. Nuss, G.R., *et al*. Presenting symptoms of anterior urethral stricture disease: a disease specific, patient reported questionnaire to measure outcomes. The Journal of urology, 2012. 187: 559.
https://pubmed.ncbi.nlm.nih.gov/22177165/
150. Cotter, K.J., *et al*. Prevalence of Post-Micturition Incontinence before and after Anterior Urethroplasty. J Urol, 2018. 200: 843.
https://pubmed.ncbi.nlm.nih.gov/29654804/
151. Anwar M.S., *et al*. To find out the Incidence of Erectile Dysfunction among patients of Stricture Urethra. Pak J Med Hlth Sci 2018. 12: 746.
https://pjmhsonline.com/2018/april_june/pdf/746.pdf
152. Mondal, S., *et al*. Erectile dysfunction in anterior urethral strictures after urethroplasty with reference to vascular parameters. Med J Armed Forces India, 2016. 72: 344.
https://pubmed.ncbi.nlm.nih.gov/27843181/
153. Blaschko, S.D., *et al*. *De novo* erectile dysfunction after anterior urethroplasty: a systematic review and meta-analysis. BJU Int, 2013. 112: 655.
https://pubmed.ncbi.nlm.nih.gov/23924424/
154. Kaluzny, A., *et al*. Ejaculatory Disorders in Men With Urethral Stricture and Impact of Urethroplasty on the Ejaculatory Function: A Systematic Review. J Sex Med, 2018. 15: 974.
https://pubmed.ncbi.nlm.nih.gov/29960631/
155. Browne, B.M., *et al*. Use of Alternative Techniques and Grafts in Urethroplasty. Urol Clin North Am, 2017. 44: 127.
https://pubmed.ncbi.nlm.nih.gov/27908367/
156. Gelman, J., *et al*. Posterior Urethral Strictures. Adv Urol, 2015. 2015: 628107.
https://pubmed.ncbi.nlm.nih.gov/26691883/
157. Potts, B.A., *et al*. Intraurethral Steroids are a Safe and Effective Treatment for Stricture Disease in Patients with Biopsy Proven Lichen Sclerosus. J Urol, 2016. 195: 1790.
https://pubmed.ncbi.nlm.nih.gov/26707511/
158. Anderson, K.M., *et al*. Management of the devastated posterior urethra and bladder neck: refractory incontinence and stenosis. Transl Androl Urol, 2015. 4: 60.
https://pubmed.ncbi.nlm.nih.gov/26816811/
159. Simms, M.S., *et al*. Well leg compartment syndrome after pelvic and perineal surgery in the lithotomy position. Postgrad Med J, 2005. 81: 534.
https://pubmed.ncbi.nlm.nih.gov/16085748/

160. Jackson, M.J., *et al*. Defining a patient-reported outcome measure for urethral stricture surgery. Eur Urol, 2011. 60: 60.
https://pubmed.ncbi.nlm.nih.gov/21419566/
161. Breyer, B.N., *et al*. Comprehensive Qualitative Assessment of Urethral Stricture Disease: Toward the Development of a Patient Centered Outcome Measure. J Urol, 2017. 198: 1113.
https://pubmed.ncbi.nlm.nih.gov/28559007/
162. Bonkat G, *et al*. Urological Infections, in EAU Guidelines. Edn. presented at the EAU Annual Congress Amsterdam 2022. 2022, The European Association of Urology: Arnhem, The Netherlands.
https://uroweb.org/guideline/urological-infections/
163. Lambert, E., *et al*. Validated uroflowmetry-based predictive model for the primary diagnosis of urethral stricture disease in men. Int J Urol, 2018. 25: 792.
https://pubmed.ncbi.nlm.nih.gov/30021245/
164. Bishara S., *et al*. Can urodynamics distinguish betweenurethral strictures and Benign Prostatic Hyperplasia (BPH)? J Clin Urol, 2015. 8: 274.
https://journals.sagepub.com/doi/abs/10.1177/2051415814565371
165. Rosenbaum, C.M., *et al*. Management of Anterior Urethral Strictures in Adults: A Survey of Contemporary Practice in Germany. Urol Int, 2017. 99: 43.
https://pubmed.ncbi.nlm.nih.gov/28601862/
166. Mahmud, S.M., *et al*. Is ascending urethrogram mandatory for all urethral strictures? J Pak Med Assoc, 2008. 58: 429.
https://pubmed.ncbi.nlm.nih.gov/18822639/
167. Krukowski, J., *et al*. Comparison between cystourethrography and sonourethrography in preoperative diagnostic management of patients with anterior urethral strictures. Med Ultrason, 2018. 20: 436.
https://pubmed.ncbi.nlm.nih.gov/30534649/
168. Kalabhavi S., *et al*. Role of Sonourethrogram in Evaluation of Anterior Urethral Stricture and its Correlation with Retrograde Urethrogram and Intraoperative Findings-A Prospective Study. J Clin Diag Res, 2018. 12: 1.
https://www.researchgate.net/publication/326945990
169. Bach, P., *et al*. Independently interpreted retrograde urethrography does not accurately diagnose and stage anterior urethral stricture: the importance of urologist-performed urethrography. Urology, 2014. 83: 1190.
https://pubmed.ncbi.nlm.nih.gov/24767528/
170. Goel, A., *et al*. Antegrade urethrogram: A technique to visualize the proximal bulbous urethral segment in anterior urethral stricture. Indian J Urol, 2009. 25: 415.
https://pubmed.ncbi.nlm.nih.gov/19881146/
171. Sung, D.J., *et al*. Obliterative urethral stricture: MR urethrography versus conventional retrograde urethrography with voiding cystourethrography. Radiology, 2006. 240: 842.
https://pubmed.ncbi.nlm.nih.gov/16857977/
172. Kathpalia, R., *et al*. Effect of phallic stretch on length of bulbous urethral stricture during retrograde urethrography. Urol Int, 2014. 93: 63.
https://pubmed.ncbi.nlm.nih.gov/24080710/
173. Buckley, J.C., *et al*. Impact of urethral ultrasonography on decision-making in anterior urethroplasty. BJU Int, 2012. 109: 438.
https://pubmed.ncbi.nlm.nih.gov/21615851/
174. Bansal, A., *et al*. Urethro-venous intravasation: a rare complication of retrograde urethrogram. BMJ Case Rep, 2016. 2016.
https://pubmed.ncbi.nlm.nih.gov/27045054/
175. Berna-Mestre, J.D., *et al*. Optimisation of sonourethrography: the clamp method. Eur Radiol, 2018. 28: 1961.
https://pubmed.ncbi.nlm.nih.gov/29247355/
176. Shahrour, W., *et al*. The Benefits of Using a Small Caliber Ureteroscope in Evaluation and Management of Urethral Stricture. Adv Urol, 2018. 2018: 9137892.
https://pubmed.ncbi.nlm.nih.gov/30584423/
177. Abu Nasra, W., *et al*. The Importance of Cystoscopy in Diagnosis and Treatment of Urethral Stricture Following Transurethral Prostatectomy. Isr Med Assoc J, 2020. 22: 241.
https://pubmed.ncbi.nlm.nih.gov/32286028/
178. Li, X., *et al*. Flexible cystoscope for evaluating pelvic fracture urethral distraction defects. Urol Int, 2012. 89: 402.
https://pubmed.ncbi.nlm.nih.gov/23221433/

179. Bryk, D.J., *et al*. Outpatient Ultrasound Urethrogram for Assessment of Anterior Urethral Stricture: Early Experience. Urology, 2016. 93: 203.
https://pubmed.ncbi.nlm.nih.gov/26993351/
180. Ravikumar, B.R., *et al*. A comparative study of ascending urethrogram and sono-urethrogram in the evaluation of stricture urethra. Int Braz J Urol, 2015. 41: 388.
https://pubmed.ncbi.nlm.nih.gov/26005985/
181. Talreja, S.M., *et al*. Comparison of sonoelastography with sonourethrography and retrograde urethrography in the evaluation of male anterior urethral strictures. Turk J Urol, 2016. 42: 84.
https://pubmed.ncbi.nlm.nih.gov/27274893/
182. Chung, P.H., *et al*. Contrast-Enhanced Ultrasound and Shear Wave Elastography: Novel Methods for the Evaluation of Urethral Stricture Disease. J Urol, 2022. 207: 152.
https://pubmed.ncbi.nlm.nih.gov/34428090/
183. Chen, L., *et al*. Three-Dimensional Computerized Model Based on the Sonourethrogram: A Novel Technique to Evaluate Anterior Urethral Stricture. J Urol, 2018. 199: 568.
https://pubmed.ncbi.nlm.nih.gov/28866465/
184. Murugesan VK, B.P. Role of Magnetic Resonance Urethrography in Evaluation of Male Urethral Stricture Against Conventional Retrograde Urethrography. J Clin Diag Res, 2018. 12: 7.
https://www.researchgate.net/publication/325867037
185. Fath El-Bab, T.K., *et al*. Magnetic resonance urethrography versus conventional retrograde urethrography in the evaluation of urethral stricture Comparison with surgical findings. Egypt J Radiol Nucl Med, 2015. 46: 199.
https://www.researchgate.net/publication/276316898
186. El-Ghar, M.A., *et al*. MR urethrogram versus combined retrograde urethrogram and sonourethrography in diagnosis of urethral stricture. Eur J Radiol, 2010. 74: e193.
https://pubmed.ncbi.nlm.nih.gov/19608363/
187. Oh, M.M., *et al*. Magnetic resonance urethrography to assess obliterative posterior urethral stricture: comparison to conventional retrograde urethrography with voiding cystourethrography. J Urol, 2010. 183: 603.
https://pubmed.ncbi.nlm.nih.gov/20018323/
188. Horiguchi, A., *et al*. Pubourethral Stump Angle Measured on Preoperative Magnetic Resonance Imaging Predicts Urethroplasty Type for Pelvic Fracture Urethral Injury Repair. Urology, 2018. 112: 198.
https://pubmed.ncbi.nlm.nih.gov/29158171/
189. Bugeja, S., *et al*. Fistulation into the Pubic Symphysis after Treatment of Prostate Cancer: An Important and Surgically Correctable Complication. J Urol, 2016. 195: 391.
https://pubmed.ncbi.nlm.nih.gov/26301787/
190. Whybrow, P., *et al*. How Men Manage Bulbar Urethral Stricture by Concealing Urinary Symptoms. Qual Health Res, 2015. 25: 1435.
https://pubmed.ncbi.nlm.nih.gov/25711843/
191. Hofer, M.D., *et al*. Outcomes after urethroplasty for radiotherapy induced bulbomembranous urethral stricture disease. The Journal of urology, 2014. 191: 1307.
https://pubmed.ncbi.nlm.nih.gov/24333513/
192. Fuchs, J.S., *et al*. Role of Chronic Suprapubic Tube in the Management of Radiation Induced Urethral Strictures. Urology Practice, 2017. 4: 479.
https://www.auajournals.org/doi/10.1016/j.urpr.2016.10.004
193. Harrison, S.C., *et al*. British Association of Urological Surgeons' suprapubic catheter practice guidelines. BJU international, 2011. 107: 77.
https://pubmed.ncbi.nlm.nih.gov/21054755/
194. Ferguson, G.G., *et al*. Minimally invasive methods for bulbar urethral strictures: a survey of members of the American Urological Association. Urology, 2011. 78: 701.
https://pubmed.ncbi.nlm.nih.gov/21762965/
195. Das, S.K., *et al*. A comparative study between the outcomes of visual internal urethrotomy for short segment anterior urethral strictures done under spinal anesthesia and local anesthesia. Turk J Urol, 2019. 45: 431.
https://pubmed.ncbi.nlm.nih.gov/31603417/
196. Steenkamp JW, *et al*. Internal Urethrotomy versus dilatation as treatment for male urethral strictures: a prospective, randomised comparison. J Urol 1997. 157: 98.
https://pubmed.ncbi.nlm.nih.gov/8976225/

197. Güler, Y. Urethral Injury Treatment Challenge. Comparison of Surgical Treatments for Acquired or Iatrogenic Urethral Stenosis and Predictive Values for Failure of Each Surgical Method. Folia Med (Plovdiv), 2021. 63: 42.
https://pubmed.ncbi.nlm.nih.gov/33650395/
198. Kluth, L.A., *et al*. Direct Vision Internal Urethrotomy for Short Anterior Urethral Strictures and Beyond: Success Rates, Predictors of Treatment Failure, and Recurrence Management. Urology, 2017. 106: 210.
https://pubmed.ncbi.nlm.nih.gov/28479479/
199. Barbagli G., *et al*. Focus on Internal Urethrotomy as Primary Treatment for Untreated Bulbar Urethral Strictures: Results from a Multivariable Analysis. Eur Urol Focus, 2020. 6: 164.
https://pubmed.ncbi.nlm.nih.gov/30409684/
200. Al Taweel W, S.R. Visual Internal Urethrotomy for Adult Male Urethral Stricture Has Poor Long-Term Results. Advances in Urology, 2015: 1.
https://pubmed.ncbi.nlm.nih.gov/26494995/
201. Pal D.K., *et al*. Direct visual internal urethrotomy: Is it a durable treatment option? Urol Ann, 2017. 9: 18.
https://pubmed.ncbi.nlm.nih.gov/28216923/
202. Launonen, E., *et al*. Role of visual internal urethrotomy in pediatric urethral strictures. J Pediatr Urol, 2014. 10: 545.
https://pubmed.ncbi.nlm.nih.gov/24388665/
203. Redon-Galvez, L., *et al*. Predictors of urethral stricture recurrence after endoscopic urethrotomy. Actas Urol Esp, 2016. 40: 529.
https://pubmed.ncbi.nlm.nih.gov/27207599/
204. Harraz A.M., *et al*. Is there a way to predict failure after direct vision internal urethrotomy for single and short bulbar urethral strictures? Arab J Urol., 2015. 13: 277.
https://pubmed.ncbi.nlm.nih.gov/26609447/
205. Goulao, B., *et al*. Surgical Treatment for Recurrent Bulbar Urethral Stricture: A Randomised Open-label Superiority Trial of Open Urethroplasty Versus Endoscopic Urethrotomy (the OPEN Trial). European urology, 2020.
https://pubmed.ncbi.nlm.nih.gov/32636099/
206. Shen, J., *et al*. Endoscopic urethrotomy versus open urethroplasty for men with bulbar urethral stricture: the OPEN randomised trial cost-effectiveness analysis. BMC Urol, 2021. 21: 76.
https://pubmed.ncbi.nlm.nih.gov/33941140/
207. Brown, E.T., *et al*. Direct visual internal urethrotomy for isolated, post-urethroplasty strictures: a retrospective analysis. Therapeutic advances in urology, 2017. 9: 39.
https://pubmed.ncbi.nlm.nih.gov/28203286/
208. Rosenbaum, C.M., *et al*. Internal urethrotomy in patients with recurrent urethral stricture after buccal mucosa graft urethroplasty. World journal of urology, 2015. 33: 1337.
https://pubmed.ncbi.nlm.nih.gov/25428791/
209. Heyns, C.F., *et al*. Treatment of male urethral strictures: is repeated dilation or internal urethrotomy useful? The Journal of urology, 1998. 160: 356.
https://pubmed.ncbi.nlm.nih.gov/9679876/
210. Torres Castellanos, L., *et al*. Evaluation of the Efficacy and Safety of Laser versus Cold Knife Urethrotomy in the Management of Patients with Urethral Strictures: A Systematic Review and Meta-Analysis of Randomized Clinical Trials. Urol Int, 2017. 99: 453.
https://pubmed.ncbi.nlm.nih.gov/28697506/
211. Jin, T., *et al*. Safety and efficacy of laser and cold knife urethrotomy for urethral stricture. Chin Med J (Engl), 2010. 123: 1589.
https://pubmed.ncbi.nlm.nih.gov/20819517/
212. Chen, J., *et al*. Comparison of holmium laser combined ureteroscopy and cold knife urethrotomy in treatment of simple urethral stricture: a 5 year follow-up study. Int J Clin Exp Med 2018. 11: 13792.
http://www.ijcem.com/files/ijcem0079991.pdf
213. Yenice, M.G., *et al*. Comparison of cold-knife optical internal urethrotomy and holmium:YAG laser internal urethrotomy in bulbar urethral strictures. Cent European J Urol, 2018. 71: 114.
https://pubmed.ncbi.nlm.nih.gov/29732217/
214. Gamal, M.A., *et al*. Holmium: YAG Versus Cold Knife Internal Urethrotomy in the Management of Short Urethral Strictures: A Randomized Controlled Trial. J Lasers Med Sci, 2021. 12: e35.
https://pubmed.ncbi.nlm.nih.gov/34733758/
215. Cecen, K., *et al*. PlasmaKinetic versus cold knife internal urethrotomy in terms of recurrence rates: a prospective randomized study. Urol Int, 2014. 93: 460.
https://pubmed.ncbi.nlm.nih.gov/25138990/

216. Ozcan, L., *et al*. Internal urethrotomy versus plasmakinetic energy for surgical treatment of urethral stricture. Arch Ital Urol Androl, 2015. 87: 161.
https://pubmed.ncbi.nlm.nih.gov/26150037/
217. Basok, E.K., *et al*. Can bipolar vaporization be considered an alternative energy source in the endoscopic treatment of urethral strictures and bladder neck contracture? Int Braz J Urol, 2008. 34: 577.
https://pubmed.ncbi.nlm.nih.gov/18986561/
218. Graversen, P.H., *et al*. Erectile dysfunction following direct vision internal urethrotomy. Scandinavian journal of urology and nephrology, 1991. 25: 175.
https://pubmed.ncbi.nlm.nih.gov/1947846/
219. Shaw, N.M., *et al*. Endoscopic Management of Urethral Stricture: Review and Practice Algorithm for Management of Male Urethral Stricture Disease. Current urology reports, 2018. 19: 19.
https://pubmed.ncbi.nlm.nih.gov/29479640/
220. Wong, S.S., *et al*. Simple urethral dilatation, endoscopic urethrotomy, and urethroplasty for urethral stricture disease in adult men. The Cochrane database of systematic reviews, 2012. 12: CD006934.
https://pubmed.ncbi.nlm.nih.gov/23235635/
221. Yu, S.C., *et al*. High-pressure balloon dilation for male anterior urethral stricture: single-center experience. J Zhejiang Univ Sci B, 2016. 17: 722.
https://pubmed.ncbi.nlm.nih.gov/27604864/
222. Hudak, S.J., *et al*. Repeat transurethral manipulation of bulbar urethral strictures is associated with increased stricture complexity and prolonged disease duration. J Urol, 2012. 187: 1691.
https://pubmed.ncbi.nlm.nih.gov/22425115/
223. Buckley, J.C., *et al*. SIU/ICUD Consultation on Urethral Strictures: Dilation, internal urethrotomy, and stenting of male anterior urethral strictures. Urology, 2014. 83: S18.
https://pubmed.ncbi.nlm.nih.gov/24286602/
224. Hosseini, J., *et al*. Feasibility, complication and long-term follow-up of the newly nelaton based urethral dilation method, retrospective study. Am J Clin Exp Urol, 2019. 7: 378.
https://pubmed.ncbi.nlm.nih.gov/31970233/
225. Kallidonis, P., *et al*. The use of S-curved coaxial dilator for urethral dilatation: Experience of a tertiary department. Urol Ann, 2018. 10: 375.
https://pubmed.ncbi.nlm.nih.gov/30386089/
226. Nomikos, M., *et al*. The use of Amplatz renal dilators in the minimally invasive management of complex urethral strictures. Cent European J Urol, 2017. 70: 301.
https://pubmed.ncbi.nlm.nih.gov/29104795/
227. Jackson, M.J., *et al*. Intermittent self-dilatation for urethral stricture disease in males. The Cochrane database of systematic reviews, 2014: CD010258.
https://pubmed.ncbi.nlm.nih.gov/25523166/
228. Chhabra, J.S., *et al*. Urethral Balloon Dilatation: Factors Affecting Outcomes. Urol Int, 2016. 96: 427.
https://pubmed.ncbi.nlm.nih.gov/26845345/
229. Greenwell, T.J., *et al*. Clean intermittent self-catheterization does not appear to be effective in the prevention of urethral stricture recurrence. Scandinavian journal of urology, 2016. 50: 71.
https://pubmed.ncbi.nlm.nih.gov/26428415/
230. Bodker A., *et al*. Treatment of recurrent urethral stricture by internal urethrotomy and intermittent self-catheterisation: A controlled study of a new therapy. J Urol., 1992. 148: 308.
https://pubmed.ncbi.nlm.nih.gov/1635124/
231. Kjaeergard B, W.S., Bartholin J, Andersen JT, Nøhr S, Beck H. Prevention of urethral stricture recurrence using clean intermittent self cathterisation. Jr J Urol., 1994. 73: 692.
https://pubmed.ncbi.nlm.nih.gov/8032838/
232. Khan S, *et al*. Role of cleanintermittent self catheterisation (CISC) in the prevention of recurrent urethral srtictures after internal optical urethrotomy. Journal o Ayub Medical College, Abbottabad: JAMC, 2011. 23: 22.
https://pubmed.ncbi.nlm.nih.gov/24800335/
233. Rijal, A., *et al*. Intermittent self dilatation--still a viable option for treatment of urethral stricture disease. Nepal Medical College journal : NMCJ, 2008. 10: 155.
https://pubmed.ncbi.nlm.nih.gov/19253858/
234. Horiguchi, A., *et al*. Do Transurethral Treatments Increase the Complexity of Urethral Strictures? The Journal of urology, 2018. 199: 508.
https://pubmed.ncbi.nlm.nih.gov/28866464/

235. Zhang, K., *et al*. Efficacy and safety of local steroids for urethra strictures: a systematic review and meta-analysis. J Endourol, 2014. 28: 962.
https://pubmed.ncbi.nlm.nih.gov/24745607/
236. Ergun, O., *et al*. A prospective, randomized trial to evaluate the efficacy of clean intermittent catheterization versus triamcinolone ointment and contractubex ointment of catheter following internal urethrotomy: long-term results. International urology and nephrology, 2015. 47: 909.
https://pubmed.ncbi.nlm.nih.gov/25913052/
237. Regmi, S., *et al*. Efficacy of Use of Triamcinolone Ointment for Clean Intermittent Self Catheterization following Internal Urethrotomy. JNMA; journal of the Nepal Medical Association, 2018. 56: 745.
https://pubmed.ncbi.nlm.nih.gov/30387461/
238. Jacobs, M.E., *et al*. The use of local therapy in preventing urethral strictures: A systematic review. PLoS One, 2021. 16: e0258256.
https://pubmed.ncbi.nlm.nih.gov/34614033/
239. Pang, K.H., *et al*. A Systematic Review and Meta-analysis of Adjuncts to Minimally Invasive Treatment of Urethral Stricture in Men. Eur Urol, 2021. 80: 467.
https://pubmed.ncbi.nlm.nih.gov/34275660/
240. Xu, C., *et al*. Efficacy of Mitomycin C Combined with Direct Vision Internal Urethrotomy for Urethral Strictures: A Systematic Review and Meta-Analysis. Urol Int, 2021: 1.
https://pubmed.ncbi.nlm.nih.gov/34670219/
241. Rezaei, M., *et al*. The effect of platelet-rich plasma injection on post-internal urethrotomy stricture recurrence. World journal of urology, 2019. 37: 1959.
https://pubmed.ncbi.nlm.nih.gov/30535714/
242. Abdallah, M.M., *et al*. Thermo-expandable metallic urethral stents for managing recurrent bulbar urethral strictures: To use or not? Arab journal of urology, 2013. 11: 85.
https://pubmed.ncbi.nlm.nih.gov/26579252/
243. Wong, E., *et al*. Durability of Memokath urethral stent for stabilisation of recurrent bulbar urethral strictures -- medium-term results. BJU international, 2014. 113 Suppl 2: 35.
https://pubmed.ncbi.nlm.nih.gov/24053476/
244. Atesci, Y.Z., *et al*. Long-term results of permanent memotherm urethral stent in the treatment of recurrent bulbar urethral strictures. International braz j urol : official journal of the Brazilian Society of Urology, 2014. 40: 80.
https://pubmed.ncbi.nlm.nih.gov/24642153/
245. Temeltas, G., *et al*. The long-term results of temporary urethral stent placement for the treatment of recurrent bulbar urethral stricture disease? International braz j urol : official journal of the Brazilian Society of Urology, 2016. 42: 351.
https://pubmed.ncbi.nlm.nih.gov/27256191/
246. Jordan, G.H., *et al*. Effect of a temporary thermo-expandable stent on urethral patency after dilation or internal urethrotomy for recurrent bulbar urethral stricture: results from a 1-year randomized trial. The Journal of urology, 2013. 190: 130.
https://pubmed.ncbi.nlm.nih.gov/23313208/
247. Erickson, B.A., *et al*. Management for prostate cancer treatment related posterior urethral and bladder neck stenosis with stents. The Journal of urology, 2011. 185: 198.
https://pubmed.ncbi.nlm.nih.gov/21074796/
248. Sertcelik, M.N., *et al*. Long-term results of permanent urethral stent Memotherm implantation in the management of recurrent bulbar urethral stenosis. BJU international, 2011. 108: 1839.
https://pubmed.ncbi.nlm.nih.gov/21756278/
249. Jung, H.S., *et al*. Early experience with a thermo-expandable stent (memokath) for the management of recurrent urethral stricture. Korean journal of urology, 2013. 54: 851.
https://pubmed.ncbi.nlm.nih.gov/24363867/
250. Elliott, S.P., *et al*. One-Year Results for the ROBUST III Randomized Controlled Trial Evaluating the Optilume(®) Drug-Coated Balloon for Anterior Urethral Strictures. J Urol, 2022. 207: 866.
https://pubmed.ncbi.nlm.nih.gov/34854748/
251. Buckley, J.C., *et al*. Removal of endoprosthesis with urethral preservation and simultaneous urethral reconstruction. The Journal of urology, 2012. 188: 856.
https://pubmed.ncbi.nlm.nih.gov/22819407/
252. Angulo, J.C., *et al*. Urethroplasty After Urethral Urolume Stent: An International Multicenter Experience. Urology, 2018. 118: 213.
https://pubmed.ncbi.nlm.nih.gov/29751026/

253. Chapple, C.R., *et al*. Management of the failure of a permanently implanted urethral stent-a therapeutic challenge. European urology, 2008. 54: 665.
https://pubmed.ncbi.nlm.nih.gov/18054424/
254. Angulo, J.C., *et al*. Urethral reconstruction in patients previously treated with Memokath urethral endoprosthesis. Actas urologicas espanolas, 2019. 43: 26.
https://pubmed.ncbi.nlm.nih.gov/30100140/
255. Ekerhult, T.O., *et al*. Limited experience, high body mass index and previous urethral surgery are risk factors for failure in open urethroplasty due to penile strictures. Scand J Urol, 2015. 49: 415.
https://pubmed.ncbi.nlm.nih.gov/25854925/
256. Joshi, P.M., *et al*. A novel composite two-stage urethroplasty for complex penile strictures: A multicenter experience. Indian J Urol, 2017. 33: 155.
https://pubmed.ncbi.nlm.nih.gov/28469305/
257. Kozinn, S.I., *et al*. Management of complex anterior urethral strictures with multistage buccal mucosa graft reconstruction. Urology, 2013. 82: 718.
https://pubmed.ncbi.nlm.nih.gov/23876581/
258. Pfalzgraf, D., *et al*. Redo-urethroplasty: comparison of early functional results and quality of life in penile and bulbar strictures. World J Urol, 2014. 32: 1191.
https://pubmed.ncbi.nlm.nih.gov/24154812/
259. Kulkarni, S., *et al*. Lichen sclerosus of the male genitalia and urethra: surgical options and results in a multicenter international experience with 215 patients. Eur Urol, 2009. 55: 945.
https://pubmed.ncbi.nlm.nih.gov/18691809/
260. Shukla, A.R., *et al*. The 2-stage hypospadias repair. Is it a misnomer? J Urol, 2004. 172: 1714.
https://pubmed.ncbi.nlm.nih.gov/15371797/
261. Mori, R.L., *et al*. Staged urethroplasty in the management of complex anterior urethral stricture disease. Transl Androl Urol, 2015. 4: 29.
https://pubmed.ncbi.nlm.nih.gov/26816806/
262. Horiguchi, A. Substitution urethroplasty using oral mucosa graft for male anterior urethral stricture disease: Current topics and reviews. Int J Urol, 2017. 24: 493.
https://pubmed.ncbi.nlm.nih.gov/28600871/
263. Mangera, A., *et al*. Management of anterior urethral stricture: an evidence-based approach. Curr Opin Urol, 2010. 20: 453.
https://pubmed.ncbi.nlm.nih.gov/20827208/
264. Mangera, A., *et al*. A systematic review of graft augmentation urethroplasty techniques for the treatment of anterior urethral strictures. Eur Urol, 2011. 59: 797.
https://pubmed.ncbi.nlm.nih.gov/21353379/
265. Abramowitz, D., *et al*. Multi-institutional review of non-hypospadiac penile urethral stricture management and outcomes. Int J Urol, 2022. 29: 376.
https://pubmed.ncbi.nlm.nih.gov/35118726/
266. Hoy, N.Y., *et al*. Better defining the optimal management of penile urethral strictures: A retrospective comparison of single-stage vs. two-stage urethroplasty. Can Urol Assoc J, 2019. 13: 414.
https://pubmed.ncbi.nlm.nih.gov/31039110/
267. Barbagli, G., *et al*. Current controversies in reconstructive surgery of the anterior urethra: a clinical overview. Int Braz J Urol, 2012. 38: 307.
https://pubmed.ncbi.nlm.nih.gov/22765862/
268. Hudak, S.J. Use of overlapping buccal mucosa graft urethroplasty for complex anterior urethral strictures. Transl Androl Urol, 2015. 4: 16.
https://pubmed.ncbi.nlm.nih.gov/26813234/
269. Martins, F.E., *et al*. Management of Long-Segment and Panurethral Stricture Disease. Adv Urol, 2015. 2015: 853914.
https://pubmed.ncbi.nlm.nih.gov/26779259/
270. Zumstein, V., *et al*. A critical outcome analysis of Asopa single-stage dorsal inlay substitution urethroplasty for penile urethral stricture. World J Urol, 2020. 38: 1283.
https://pubmed.ncbi.nlm.nih.gov/31321508/
271. Aldaqadossi, H., *et al*. Dorsal onlay (Barbagli technique) versus dorsal inlay (Asopa technique) buccal mucosal graft urethroplasty for anterior urethral stricture: a prospective randomized study. Int J Urol, 2014. 21: 185.
https://pubmed.ncbi.nlm.nih.gov/23931150/
272. Barbagli, G., *et al*. Retrospective outcome analysis of one-stage penile urethroplasty using a flap or graft in a homogeneous series of patients. BJU international, 2008. 102: 853.
https://pubmed.ncbi.nlm.nih.gov/18485036/

273. Barbagli, G., *et al*. Long-term followup and deterioration rate of anterior substitution urethroplasty. J Urol, 2014. 192: 808.
https://pubmed.ncbi.nlm.nih.gov/24533999/
274. Fu, Q., *et al*. Substitution urethroplasty for anterior urethral stricture repair: comparison between lingual mucosa graft and pedicled skin flap. Scandinavian journal of urology, 2017. 51: 479.
https://pubmed.ncbi.nlm.nih.gov/28738760/
275. Goel, A., *et al*. Buccal mucosal graft urethroplasty for penile stricture: only dorsal or combined dorsal and ventral graft placement? Urology, 2011. 77: 1482.
https://pubmed.ncbi.nlm.nih.gov/21354596/
276. Xu, Y.M., *et al*. Outcome of 1-stage urethroplasty using oral mucosal grafts for the treatment of urethral strictures associated with genital lichen sclerosus. Urology, 2014. 83: 232.
https://pubmed.ncbi.nlm.nih.gov/24200196/
277. Jinga, V., *et al*. Ventral buccal mucosa graft urethroplasty for penile urethral strictures: a predictable failure? Chirurgia (Bucur), 2013. 108: 245.
https://pubmed.ncbi.nlm.nih.gov/23618576/
278. Mellon, M.J., *et al*. Ventral onlay buccal mucosa urethroplasty: a 10-year experience. Int J Urol, 2014. 21: 190.
https://pubmed.ncbi.nlm.nih.gov/23980634/
279. Salako, A.A., *et al*. Pendulous urethral stricture: peculiarities and relevance of longitudinal penile fascio-cutaneous flap reconstruction in poor resource community. Urol J, 2014. 10: 1088.
https://pubmed.ncbi.nlm.nih.gov/24469655/
280. Jiang, J., *et al*. Combined Dorsal Plus Ventral Double-Graft Urethroplasty in Anterior Urethral Reconstruction. Indian J Surg, 2015. 77: 996.
https://pubmed.ncbi.nlm.nih.gov/27011497/
281. Iqbal, Z., *et al*. Comparison of onlay and circumferential tubular fasciocutaneous penile skin flap for penile urethral strictures. J. Med. Sci, 2015. 23: 134.
https://www.researchgate.net/publication/321342370
282. Peterson, A.C., *et al*. Heroic measures may not always be justified in extensive urethral stricture due to lichen sclerosus (balanitis xerotica obliterans). Urology, 2004. 64: 565.
https://pubmed.ncbi.nlm.nih.gov/15351594/
283. Palminteri, E., *et al*. Urethral reconstruction in lichen sclerosus. Curr Opin Urol, 2012. 22: 478.
https://pubmed.ncbi.nlm.nih.gov/22965317/
284. Chapple, C., *et al*. SIU/ICUD Consultation on Urethral Strictures: The management of anterior urethral stricture disease using substitution urethroplasty. Urology, 2014. 83: S31.
https://pubmed.ncbi.nlm.nih.gov/24411214/
285. Shakir, N.A., *et al*. Excision and Primary Anastomosis Reconstruction for Traumatic Strictures of the Pendulous Urethra. Urology, 2019. 125: 234.
https://pubmed.ncbi.nlm.nih.gov/30125648/
286. El-Kassaby, A.W., *et al*. Management of men with ultra-short penile urethral stricture using augmented anastomotic penile skin flap urethroplasty; a retrospective analysis. African Journal of Urology, 2021. 27: 33.
https://afju.springeropen.com/articles/10.1186/s12301-021-00130-4
287. Hampson, L.A., *et al*. Male urethral strictures and their management. Nat Rev Urol, 2014. 11: 43.
https://pubmed.ncbi.nlm.nih.gov/24346008/
288. Kulkarni, S.B., *et al*. Redo hypospadias surgery: current and novel techniques. Res Rep Urol, 2018. 10: 117.
https://pubmed.ncbi.nlm.nih.gov/30320039/
289. Craig, J.R., *et al*. Management of adults with prior failed hypospadias surgery. Transl Androl Urol, 2014. 3: 196.
https://pubmed.ncbi.nlm.nih.gov/26816767/
290. Rourke, K., *et al*. Transitioning patients with hypospadias and other penile abnormalities to adulthood: What to expect? Can Urol Assoc J, 2018. 12: S27.
https://pubmed.ncbi.nlm.nih.gov/29681271/
291. Lee, O.T., *et al*. Predictors of secondary surgery after hypospadias repair: a population based analysis of 5,000 patients. J Urol, 2013. 190: 251.
https://pubmed.ncbi.nlm.nih.gov/23376710/
292. Spilotros, M., *et al*. Penile urethral stricture disease. Journal of Clinical Urology, 2018. 12: 145.
https://journals.sagepub.com/doi/10.1177/2051415818774227

293. Wu, M., *et al*. Management of failed hypospadias: choosing the right method and achieving optimal results. Int Urol Nephrol, 2018. 50: 1795.
https://pubmed.ncbi.nlm.nih.gov/30121720/
294. Kiss, A., *et al*. Long-term psychological and sexual outcomes of severe penile hypospadias repair. J Sex Med, 2011. 8: 1529.
https://pubmed.ncbi.nlm.nih.gov/21091883/
295. Morrison, C.D., *et al*. Surgical Approaches and Long-Term Outcomes in Adults with Complex Reoperative Hypospadias Repair. J Urol, 2018. 199: 1296.
https://pubmed.ncbi.nlm.nih.gov/29198998/
296. Myers, J.B., *et al*. Treatment of adults with complications from previous hypospadias surgery. The Journal of urology, 2012. 188: 459.
https://pubmed.ncbi.nlm.nih.gov/22698621/
297. Aldamanhori, R.B., *et al*. Contemporary outcomes of hypospadias retrieval surgery in adults. BJU Int, 2018. 122: 673.
https://pubmed.ncbi.nlm.nih.gov/29671932/
298. Pandey, A., *et al*. The Staged Urethroplasty with Vascularised Scrotal Flap and Buccal Mucosa Graft after Failed Hypospadias Surgery: A Reliable Technique with a Novel Tool. Urol Int, 2017. 99: 36.
https://pubmed.ncbi.nlm.nih.gov/28285314/
299. Li, H.B., *et al*. One-stage dorsal lingual mucosal graft urethroplasty for the treatment of failed hypospadias repair. Asian J Androl, 2016. 18: 467.
https://pubmed.ncbi.nlm.nih.gov/26228042/
300. Bastian, P.J., *et al*. Single-stage dorsal inlay for reconstruction of recurrent peno-glandular stenosis. World journal of urology, 2012. 30: 715.
https://pubmed.ncbi.nlm.nih.gov/21989815/
301. Xu, Y.M., *et al*. Intermediate-Term Outcomes and Complications of Long Segment Urethroplasty with Lingual Mucosa Grafts. The Journal of urology, 2017. 198: 401.
https://pubmed.ncbi.nlm.nih.gov/28286073/
302. Xu, Y.M., *et al*. Treatment of urethral strictures using lingual mucosas urethroplasty: experience of 92 cases. Chin Med J (Engl), 2010. 123: 458.
https://pubmed.ncbi.nlm.nih.gov/20193487/
303. Barbagli, G., *et al*. Correlation Between Primary Hypospadias Repair and Subsequent Urethral Strictures in a Series of 408 Adult Patients. Eur Urol Focus, 2017. 3: 287.
https://pubmed.ncbi.nlm.nih.gov/28753858/
304. Liu, Y., *et al*. One-stage dorsal inlay oral mucosa graft urethroplasty for anterior urethral stricture. BMC Urol, 2014. 14: 35.
https://pubmed.ncbi.nlm.nih.gov/24885070/
305. Warner, J.N., *et al*. A Multi-institutional Evaluation of the Management and Outcomes of Long-segment Urethral Strictures. Urology, 2015. 85: 1483.
https://pubmed.ncbi.nlm.nih.gov/25868738/
306. Blaschko, S.D., *et al*. Repeat urethroplasty after failed urethral reconstruction: outcome analysis of 130 patients. J Urol, 2012. 188: 2260.
https://pubmed.ncbi.nlm.nih.gov/23083654/
307. Belsante, M.J., *et al*. The contemporary management of urethral strictures in men resulting from lichen sclerosus. Transl Androl Urol, 2015. 4: 22.
https://pubmed.ncbi.nlm.nih.gov/26816805/
308. Treiyer, A., *et al*. [Treatment of urethral meatus stenosis due to Balanitis xerotic obliterans. Long term results using the meatoplasty of Malone]. Actas Urol Esp, 2011. 35: 494.
https://pubmed.ncbi.nlm.nih.gov/21514696/
309. Madden-Fuentes, R.J., *et al*. Contemporary analysis of management of isolated pendulous urethral strictures using pedicled skin flap urethroplasty repair. World J Urol, 2019. 37: 2769.
https://pubmed.ncbi.nlm.nih.gov/30824984/
310. Babu, P., *et al*. Evaluation of Jordan's meatoplasty for the treatment of fossa navicularis strictures. A retrospective study. Cent European J Urol, 2017. 70: 103.
https://pubmed.ncbi.nlm.nih.gov/28461997/
311. Tijani, K.H., *et al*. Dorsal Island Penile Fasciocutaneous Flap for Fossa Navicularis and Meatal Strictures: Short and Intermediate Term Outcome in West African Men. Urol J, 2015. 12: 2267.
https://pubmed.ncbi.nlm.nih.gov/26341770/

312. Zumstein, V., *et al*. Single-stage buccal mucosal graft urethroplasty for meatal stenoses and fossa navicularis strictures: a monocentric outcome analysis and literature review on alternative treatment options. World J Urol, 2020. 38: 2609.
https://pubmed.ncbi.nlm.nih.gov/31786639/
313. Wirtz, M., *et al*. Treatment of Meatal Strictures by Dorsal Inlay Oral Mucosa Graft Urethroplasty: A Single-Center Experience. J Clin Med, 2021. 10.
https://pubmed.ncbi.nlm.nih.gov/34640331/
314. Campos-Juanatey, F., *et al*. Single-stage tubular urethral reconstruction using oral grafts is an alternative to classical staged approach for selected penile urethral strictures. Asian J Androl, 2020. 22: 134.
https://pubmed.ncbi.nlm.nih.gov/31441450/
315. Nilsen, O.J., *et al*. To Transect or Not Transect: Results from the Scandinavian Urethroplasty Study, A Multicentre Randomised Study of Bulbar Urethroplasty Comparing Excision and Primary Anastomosis Versus Buccal Mucosal Grafting. Eur Urol, 2022. 81: 375.
https://pubmed.ncbi.nlm.nih.gov/35012771/
316. Morey, A.F., *et al*. SIU/ICUD Consultation on Urethral Strictures: Anterior urethra--primary anastomosis. Urology, 2014. 83: S23.
https://pubmed.ncbi.nlm.nih.gov/24373726/
317. Chapman, D., *et al*. Independent Predictors of Stricture Recurrence Following Urethroplasty for Isolated Bulbar Urethral Strictures. J Urol, 2017. 198: 1107.
https://pubmed.ncbi.nlm.nih.gov/28483575/
318. Sawant, A.S., *et al*. An Audit of Urethroplasty Techniques used for Managing Anterior Urethral Strictures at a Tertiary Care Teaching Institute-What We Learned. Journal of Clinical and Diagnostic Research, 2018. 12: PC17.
https://www.researchgate.net/publication/323677279
319. Chapman, D.W., *et al*. Non-Transecting Techniques Reduce Sexual Dysfunction After Anastomotic Bulbar Urethroplasty: Results of a Multi-Institutional Comparative Analysis. J Urol, 2018.
https://pubmed.ncbi.nlm.nih.gov/30266331/
320. Suh, J.G., *et al*. Surgical Outcome of Excision and End-to-End Anastomosis for Bulbar Urethral Stricture. Korean J Urol, 2013. 54: 442.
https://pubmed.ncbi.nlm.nih.gov/23878686/
321. Siegel, J.A., *et al*. Repeat Excision and Primary Anastomotic Urethroplasty for Salvage of Recurrent Bulbar Urethral Stricture. J Urol, 2015. 194: 1316.
https://pubmed.ncbi.nlm.nih.gov/26003205/
322. Ivaz, S., *et al*. The Nontransecting Approach to Bulbar Urethroplasty. Urol Clin North Am, 2017. 44: 57.
https://pubmed.ncbi.nlm.nih.gov/27908372/
323. Horiguchi, A., *et al*. Surgical and patient-reported outcomes of urethroplasty for bulbar stricture due to a straddle injury. World J Urol, 2020. 38: 1805.
https://pubmed.ncbi.nlm.nih.gov/31559477/
324. Jordan, G.H., *et al*. The technique of vessel sparing excision and primary anastomosis for proximal bulbous urethral reconstruction. J Urol, 2007. 177: 1799.
https://pubmed.ncbi.nlm.nih.gov/17437823/
325. Andrich, D.E., *et al*. Non-transecting anastomotic bulbar urethroplasty: a preliminary report. BJU Int, 2012. 109: 1090.
https://pubmed.ncbi.nlm.nih.gov/21933325/
326. Morey, A.F., *et al*. Proximal bulbar urethroplasty via extended anastomotic approach--what are the limits? J Urol, 2006. 175: 2145.
https://pubmed.ncbi.nlm.nih.gov/16697823/
327. Waterloos, M., *et al*. Excision and Primary Anastomosis for Short Bulbar Strictures: Is It Safe to Change from the Transecting towards the Nontransecting Technique? Biomed Res Int, 2018. 2018: 3050537.
https://pubmed.ncbi.nlm.nih.gov/30515389/
328. Virasoro, R., *et al*. International multi-institutional experience with the vessel-sparing technique to reconstruct the proximal bulbar urethra: mid-term results. World J Urol, 2015. 33: 2153.
https://pubmed.ncbi.nlm.nih.gov/25690318/
329. Elkady, E., *et al*. Bulbospongiosus Muscle Sparing Urethroplasty Versus Standard Urethroplasty: A Comparative Study. Urology, 2019. 126: 217.
https://pubmed.ncbi.nlm.nih.gov/30605695/

330. Vasudeva, P., *et al*. Dorsal versus ventral onlay buccal mucosal graft urethroplasty for long-segment bulbar urethral stricture: A prospective randomized study. Int J Urol, 2015. 22: 967.
https://pubmed.ncbi.nlm.nih.gov/26138109/
331. Benson, C.R., *et al*. Long term outcomes of one-stage augmentation anterior urethroplasty: a systematic review and meta-analysis. Int Braz J Urol, 2021. 47: 237.
https://pubmed.ncbi.nlm.nih.gov/32459452/
332. Barbagli, G., *et al*. Muscle- and nerve-sparing bulbar urethroplasty: a new technique. Eur Urol, 2008. 54: 335.
https://pubmed.ncbi.nlm.nih.gov/18384930/
333. Fredrick, A., *et al*. Functional Effects of Bulbospongiosus Muscle Sparing on Ejaculatory Function and Post-Void Dribbling after Bulbar Urethroplasty. J Urol, 2017. 197: 738.
https://pubmed.ncbi.nlm.nih.gov/27686691/
334. Kahokehr, A.A., *et al*. A Critical Analysis of Bulbar Urethroplasty Stricture Recurrence: Characteristics and Management. J Urol, 2018. 200: 1302.
https://pubmed.ncbi.nlm.nih.gov/30012364/
335. Abouassaly, R., *et al*. Augmented anastomotic urethroplasty. J Urol, 2007. 177: 2211.
https://pubmed.ncbi.nlm.nih.gov/17509322/
336. Redmond, E.J., *et al*. Augmented Anastomotic Urethroplasty is Independently Associated with Failure after Reconstruction for Long Bulbar Urethral Strictures. J Urol, 2020. 204: 989.
https://pubmed.ncbi.nlm.nih.gov/32501135/
337. Bugeja, S., *et al*. Non-transecting bulbar urethroplasty. Transl Androl Urol, 2015. 4: 41.
https://pubmed.ncbi.nlm.nih.gov/26816808/
338. Rajaian, S., *et al*. Non Transecting Dorsal Onlay and Ventral Inlay Buccal Mucosal Substitution Urethroplasty for Obliterative Bulbar Urethral Strictures. Urol Int, 2019. 103: 454.
https://pubmed.ncbi.nlm.nih.gov/31614357/
339. Barbagli, G., *et al*. Clinical outcome and quality of life assessment in patients treated with perineal urethrostomy for anterior urethral stricture disease. The Journal of urology, 2009. 182: 548.
https://pubmed.ncbi.nlm.nih.gov/19524945/
340. Secrest, C.L. Staged urethroplasty: indications and techniques. Urol Clin North Am, 2002. 29: 467.
https://pubmed.ncbi.nlm.nih.gov/12371236/
341. Pfalzgraf, D., *et al*. Two-staged urethroplasty: buccal mucosa and mesh graft techniques. Aktuelle Urologie, 2010. 41 Suppl 1: S5.
https://pubmed.ncbi.nlm.nih.gov/20094954/
342. Levine, M.A., *et al*. Revision urethroplasty success is comparable to primary urethroplasty: a comparative analysis. Urology, 2014. 84: 928.
https://pubmed.ncbi.nlm.nih.gov/25129537/
343. Pfalzgraf, D., *et al*. Staged urethroplasty: comparison of early functional results and quality of life in mesh graft and buccal mucosa technique. Can J Urol, 2015. 22: 7720.
https://pubmed.ncbi.nlm.nih.gov/25891336/
344. Yalçınkaya, F., *et al*. Critical analysis of urethroplasty for male anterior urethral stricture: a single-center experience. World J Urol, 2020. 38: 2313.
https://pubmed.ncbi.nlm.nih.gov/31732770/
345. Shalkamy, O., *et al*. Factors Predicting Urethral Stricture Recurrence after Dorsal Onlay Augmented, Buccal Mucosal Graft Urethroplasty. Urol Int, 2021. 105: 269.
https://pubmed.ncbi.nlm.nih.gov/33333534/
346. Barbagli, G., *et al*. Treatments of 1242 bulbar urethral strictures: multivariable statistical analysis of results. World J Urol, 2019. 37: 1165.
https://pubmed.ncbi.nlm.nih.gov/30220045/
347. Viers, B.R., *et al*. Urethral Reconstruction in Aging Male Patients. Urology, 2018. 113: 209.
https://pubmed.ncbi.nlm.nih.gov/29031840/
348. Ahyai, S.A., *et al*. Outcomes of Ventral Onlay Buccal Mucosa Graft Urethroplasty in Patients after Radiotherapy. J Urol, 2015. 194: 441.
https://pubmed.ncbi.nlm.nih.gov/25846417/
349. Breyer, B.N., *et al*. Multivariate analysis of risk factors for long-term urethroplasty outcome. J Urol, 2010. 183: 613.
https://pubmed.ncbi.nlm.nih.gov/20018318/
350. Kinnaird, A.S., *et al*. Stricture length and etiology as preoperative independent predictors of recurrence after urethroplasty: A multivariate analysis of 604 urethroplasties. Canadian Urological Association journal = Journal de l'Association des urologues du Canada, 2014. 8: E296.
https://pubmed.ncbi.nlm.nih.gov/24940453/

351. Verla, W., *et al*. Independent risk factors for failure after anterior urethroplasty: a multivariate analysis on prospective data. World J Urol, 2020. 38: 3251.
https://pubmed.ncbi.nlm.nih.gov/32076822/
352. Rosenbaum, C.M., *et al*. Redo buccal mucosa graft urethroplasty: success rate, oral morbidity and functional outcomes. BJU Int, 2016. 118: 797.
https://pubmed.ncbi.nlm.nih.gov/27170089/
353. Javali, T.D., *et al*. Management of recurrent anterior urethral strictures following buccal mucosal graft-urethroplasty: A single center experience. Urology annals, 2016. 8: 31.
https://pubmed.ncbi.nlm.nih.gov/26834398/
354. Vetterlein, M.W., *et al*. The Impact of Surgical Sequence on Stricture Recurrence after Anterior 1-Stage Buccal Mucosal Graft Urethroplasty: Comparative Effectiveness of Initial, Repeat and Secondary Procedures. J Urol, 2018. 200: 1308.
https://pubmed.ncbi.nlm.nih.gov/30126826/
355. Hussein, M.M., *et al*. The use of penile skin graft versus penile skin flap in the repair of long bulbo-penile urethral stricture: a prospective randomized study. Urology, 2011. 77: 1232.
https://pubmed.ncbi.nlm.nih.gov/21208648/
356. Kulkarni, S.B., *et al*. Management of panurethral stricture disease in India. J Urol, 2012. 188: 824.
https://pubmed.ncbi.nlm.nih.gov/22818345/
357. Hussein, M.M., *et al*. Urethroplasty for treatment of long anterior urethral stricture: buccal mucosa graft versus penile skin graft-does the stricture length matter? Int Urol Nephrol, 2016. 48: 1831.
https://pubmed.ncbi.nlm.nih.gov/27401984/
358. El Dahshoury, Z.M. Modified annular penile skin flap for repair of pan-anterior urethral stricture. International urology and nephrology, 2009. 41: 889.
https://pubmed.ncbi.nlm.nih.gov/19189226/
359. Mathur, R.K., *et al*. Tunica albuginea urethroplasty for panurethral strictures. Urol J, 2010. 7: 120.
https://pubmed.ncbi.nlm.nih.gov/20535700/
360. Meeks, J.J., *et al*. Urethroplasty with abdominal skin grafts for long segment urethral strictures. The Journal of urology, 2010. 183: 1880.
https://pubmed.ncbi.nlm.nih.gov/20303098/
361. Tavakkoli Tabassi, K., *et al*. Dorsally Placed Buccal Mucosal Graft Urethroplasty in Treatment of Long Urethral Strictures Using One-Stage Transperineal Approach. International scholarly research notices, 2014. 2014: 792982.
https://pubmed.ncbi.nlm.nih.gov/27437449/
362. Alsagheer, G.A., *et al*. Management of long segment anterior urethral stricture (≥ 8cm) using buccal mucosal (BM) graft and penile skin (PS) flap: outcome and predictors of failure. Int Braz J Urol, 2018. 44: 163.
https://pubmed.ncbi.nlm.nih.gov/29211404/
363. DeLong, J., *et al*. Augmented perineal urethrostomy using a dorsal buccal mucosal graft, bi-institutional study. World J Urol, 2017. 35: 1285.
https://pubmed.ncbi.nlm.nih.gov/28108798/
364. Lumen, N., *et al*. Perineal urethrostomy: surgical and functional evaluation of two techniques. Biomed Res Int, 2015. 2015: 365715.
https://pubmed.ncbi.nlm.nih.gov/25789316/
365. Myers, J.B., *et al*. The outcomes of perineal urethrostomy with preservation of the dorsal urethral plate and urethral blood supply. Urology, 2011. 77: 1223.
https://pubmed.ncbi.nlm.nih.gov/21215434/
366. French, D., *et al*. The "7-flap" perineal urethrostomy. Urology, 2011. 77: 1487.
https://pubmed.ncbi.nlm.nih.gov/21256550/
367. McKibben, M.J., *et al*. Versatile algorithmic midline approach to perineal urethrostomy for complex urethral strictures. World J Urol, 2019. 37: 1403.
https://pubmed.ncbi.nlm.nih.gov/30334075/
368. Bascom, A., *et al*. Assessment of Wound Complications After Bulbar Urethroplasty: The Impact of a Lambda Perineal Incision. Urology, 2016. 90: 184.
https://pubmed.ncbi.nlm.nih.gov/26777749/
369. Lin, Y., *et al*. Perineal midline vertical incision verses inverted-U incision in the urethroplasty: which is better? World journal of urology, 2018. 36: 1267.
https://pubmed.ncbi.nlm.nih.gov/29541891/
370. Starke, N.R., *et al*. '7-flap' perineal urethrostomy: an effective option for obese men with devastated urethras. The Canadian journal of urology, 2015. 22: 7902.
https://pubmed.ncbi.nlm.nih.gov/26267029/

371. Granieri, M.A., *et al*. The evolution of urethroplasty for bulbar urethral stricture disease: lessons learned from a single center experience. J Urol, 2014. 192: 1468.
https://pubmed.ncbi.nlm.nih.gov/24859444/
372. Fuchs, J.S., *et al*. Changing Trends in Reconstruction of Complex Anterior Urethral Strictures: From Skin Flap to Perineal Urethrostomy. Urology, 2018. 122: 169.
https://pubmed.ncbi.nlm.nih.gov/30138682/
373. Lopez, J.C., *et al*. Perineostomy: the last oportunity. Int Braz J Urol, 2015. 41: 91.
https://pubmed.ncbi.nlm.nih.gov/25928514/
374. Murphy, G.P., *et al*. Urinary and Sexual Function after Perineal Urethrostomy for Urethral Stricture Disease: An Analysis from the TURNS. J Urol, 2019. 201: 956.
https://pubmed.ncbi.nlm.nih.gov/30676476/
375. Ramchandani, P., *et al*. Vesicourethral anastomotic strictures after radical prostatectomy: efficacy of transurethral balloon dilation. Radiology, 1994. 193: 345.
https://pubmed.ncbi.nlm.nih.gov/7972741/
376. LaBossiere, J.R., *et al*. Endoscopic Treatment of Vesicourethral Stenosis after Radical Prostatectomy: Outcomes and Predictors of Success. J Urol, 2016. 195: 1495.
https://pubmed.ncbi.nlm.nih.gov/26719028/
377. Kumar, P., *et al*. Management of post-radical prostatectomy anastomotic stricture by endoscopic transurethral balloon dilatation. Scand J Urol Nephrol, 2007. 41: 314.
https://pubmed.ncbi.nlm.nih.gov/17763223/
378. Ishii, G., *et al*. High pressure balloon dilation for vesicourethral anastomotic strictures after radical prostatectomy. BMC Urol, 2015. 15: 62.
https://pubmed.ncbi.nlm.nih.gov/26134267/
379. Kravchick, S., *et al*. Transrectal ultrasonography-guided injection of long-acting steroids in the treatment of recurrent/resistant anastomotic stenosis after radical prostatectomy. J Endourol, 2013. 27: 875.
https://pubmed.ncbi.nlm.nih.gov/23461798/
380. Hayashi, T., *et al*. Successful treatment of recurrent vesicourethral stricture after radical prostatectomy with holmium laser: report of three cases. Int J Urol, 2005. 12: 414.
https://pubmed.ncbi.nlm.nih.gov/15948734/
381. Merrick, G.S., *et al*. Risk factors for the development of prostate brachytherapy related urethral strictures. J Urol, 2006. 175: 1376.
https://pubmed.ncbi.nlm.nih.gov/16516001/
382. Bang, S.L., *et al*. Post Prostatectomy Vesicourethral Stenosis or Bladder Neck Contracture with Concomitant Urinary Incontinence: Our Experience and Recommendations. Curr Urol, 2017. 10: 32.
https://pubmed.ncbi.nlm.nih.gov/28559775/
383. Matsushita, K., *et al*. Pubovesical fistula: a rare complication after treatment of prostate cancer. Urology, 2012. 80: 446.
https://pubmed.ncbi.nlm.nih.gov/22698471/
384. Gupta, S., *et al*. Pubic symphysis osteomyelitis in the prostate cancer survivor: clinical presentation, evaluation, and management. Urology, 2015. 85: 684.
https://pubmed.ncbi.nlm.nih.gov/25733290/
385. Shapiro, D.D., *et al*. Urosymphyseal Fistulas Resulting From Endoscopic Treatment of Radiation-induced Posterior Urethral Strictures. Urology, 2018. 114: 207.
https://pubmed.ncbi.nlm.nih.gov/29305945/
386. Sukumar, S., *et al*. The Devastated Bladder Outlet in Cancer Survivors After Local Therapy for Prostate Cancer. Current Bladder Dysfunction Reports, 2016. 11: 79.
https://www.researchgate.net/publication/299530474
387. Veerman, H., *et al*. Surgical and Functional Outcomes of Bladder Neck Incision for Primary Vesico-Urethral Anastomosis Stricture after Robot-assisted Radical Prostatectomy are Influenced by the Presence of Pre- or Postoperative Radiotherapy. Urology, 2022. 166: 216.
https://pubmed.ncbi.nlm.nih.gov/35318046/
388. Ramirez, D., *et al*. Deep lateral transurethral incisions for recurrent bladder neck contracture: promising 5-year experience using a standardized approach. Urology, 2013. 82: 1430.
https://pubmed.ncbi.nlm.nih.gov/24054130/
389. Yurkanin, J.P., *et al*. Evaluation of cold knife urethrotomy for the treatment of anastomotic stricture after radical retropubic prostatectomy. J Urol, 2001. 165: 1545.
https://pubmed.ncbi.nlm.nih.gov/11342914/

390. Giannarini, G., *et al*. Cold-knife incision of anastomotic strictures after radical retropubic prostatectomy with bladder neck preservation: efficacy and impact on urinary continence status. Eur Urol, 2008. 54: 647.
https://pubmed.ncbi.nlm.nih.gov/18155824/
391. Brede, C., *et al*. Continence outcomes after treatment of recalcitrant postprostatectomy bladder neck contracture and review of the literature. Urology, 2014. 83: 648.
https://pubmed.ncbi.nlm.nih.gov/24365088/
392. Popken, G., *et al*. Anastomotic stricture after radical prostatectomy. Incidence, findings and treatment. Eur Urol, 1998. 33: 382.
https://pubmed.ncbi.nlm.nih.gov/9612681/
393. Gousse, A.E., *et al*. Two-stage management of severe postprostatectomy bladder neck contracture associated with stress incontinence. Urology, 2005. 65: 316.
https://pubmed.ncbi.nlm.nih.gov/15708045/
394. Lagerveld, B.W., *et al*. Holmium:YAG laser for treatment of strictures of vesicourethral anastomosis after radical prostatectomy. J Endourol, 2005. 19: 497.
https://pubmed.ncbi.nlm.nih.gov/15910265/
395. Brodak, M., *et al*. Bipolar transurethral resection of anastomotic strictures after radical prostatectomy. J Endourol, 2010. 24: 1477.
https://pubmed.ncbi.nlm.nih.gov/20653423/
396. Eltahawy, E., *et al*. Management of recurrent anastomotic stenosis following radical prostatectomy using holmium laser and steroid injection. BJU Int, 2008. 102: 796.
https://pubmed.ncbi.nlm.nih.gov/18671784/
397. Sourial, M.W., *et al*. Mitomycin-C and urethral dilatation: A safe, effective, and minimally invasive procedure for recurrent vesicourethral anastomotic stenoses. Urol Oncol, 2017. 35: 672 e15.
https://pubmed.ncbi.nlm.nih.gov/28844555/
398. Kranz, J., *et al*. Differences in Recurrence Rate and *De Novo* Incontinence after Endoscopic Treatment of Vesicourethral Stenosis and Bladder Neck Stenosis. Front Surg, 2017. 4: 44.
https://pubmed.ncbi.nlm.nih.gov/28848735/
399. Pfalzgraf, D., *et al*. Vesico-urethral anastomotic stenosis following radical prostatectomy: a multi-institutional outcome analysis with a focus on endoscopic approach, surgical sequence, and the impact of radiation therapy. World J Urol, 2021. 39: 89.
https://pubmed.ncbi.nlm.nih.gov/32236662/
400. Ozturk, H. Treatment of recurrent vesicourethral anastomotic stricture after radical prostatectomy using plasma-button vaporization. Scand J Urol, 2015. 49: 371.
https://pubmed.ncbi.nlm.nih.gov/25697282/
401. Vanni, A.J., *et al*. Radial urethrotomy and intralesional mitomycin C for the management of recurrent bladder neck contractures. J Urol, 2011. 186: 156.
https://pubmed.ncbi.nlm.nih.gov/21575962/
402. Nagpal, K., *et al*. Durable Results of Mitomycin C Injection with Internal Urethrotomy for Refractory Bladder Neck Contractures: Multi-institutional Experience. Urology Practice, 2015. 2: 250.
https://www.auajournals.org/doi/abs/10.1016/j.urpr.2014.12.007
403. Farrell, M.R., *et al*. Visual Internal Urethrotomy With Intralesional Mitomycin C and Short-term Clean Intermittent Catheterization for the Management of Recurrent Urethral Strictures and Bladder Neck Contractures. Urology, 2015. 85: 1494.
https://pubmed.ncbi.nlm.nih.gov/26099892/
404. Redshaw, J.D., *et al*. Intralesional injection of mitomycin C at transurethral incision of bladder neck contracture may offer limited benefit: TURNS Study Group. The Journal of urology, 2015. 193: 587.
https://pubmed.ncbi.nlm.nih.gov/25200807/
405. Lyon, T.D., *et al*. Bipolar Transurethral Incision of Bladder Neck Stenoses with Mitomycin C Injection. Adv Urol, 2015. 2015: 758536.
https://pubmed.ncbi.nlm.nih.gov/26635876/
406. Rozanski, A.T., *et al*. The Effect of Radiation Therapy on the Efficacy of Internal Urethrotomy With Intralesional Mitomycin C for Recurrent Vesicourethral Anastomotic Stenoses and Bladder Neck Contractures: A Multi-Institutional Experience. Urology, 2021. 147: 294.
https://pubmed.ncbi.nlm.nih.gov/33035561/
407. Kahokehr, A.A., *et al*. Posterior urethral stenosis after prostate cancer treatment: contemporary options for definitive management. Transl Androl Urol, 2018. 7: 580.
https://pubmed.ncbi.nlm.nih.gov/30211048/

408. Nikolavsky, D., *et al*. Open reconstruction of recurrent vesicourethral anastomotic stricture after radical prostatectomy. Int Urol Nephrol, 2014. 46: 2147.
https://pubmed.ncbi.nlm.nih.gov/25134944/
409. Kirshenbaum, E.J., *et al*. Patency and Incontinence Rates After Robotic Bladder Neck Reconstruction for Vesicourethral Anastomotic Stenosis and Recalcitrant Bladder Neck Contractures: The Trauma and Urologic Reconstructive Network of Surgeons Experience. Urology, 2018. 118: 227.
https://pubmed.ncbi.nlm.nih.gov/29777787/
410. Mundy, A.R., *et al*. Posterior urethral complications of the treatment of prostate cancer. BJU Int, 2012. 110: 304.
https://pubmed.ncbi.nlm.nih.gov/22340079/
411. Dinerman, B.F., *et al*. Robotic-Assisted Abdomino-perineal Vesicourethral Anastomotic Reconstruction for 4.5 Centimeter Post-prostatectomy Stricture. Urol Case Rep, 2017. 14: 1.
https://pubmed.ncbi.nlm.nih.gov/28607874/
412. Schuettfort, V.M., *et al*. Transperineal reanastomosis for treatment of highly recurrent anastomotic strictures after radical retropubic prostatectomy: extended follow-up. World J Urol, 2017. 35: 1885.
https://pubmed.ncbi.nlm.nih.gov/28674908/
413. Pfalzgraf, D., *et al*. Open retropubic reanastomosis for highly recurrent and complex bladder neck stenosis. J Urol, 2011. 186: 1944.
https://pubmed.ncbi.nlm.nih.gov/21944115/
414. Giudice, C.R., *et al*. Surgical approach to vesicourethral anastomotic stricture following radical prostatectomy. Actas Urol Esp, 2016. 40: 124.
https://pubmed.ncbi.nlm.nih.gov/26515118/
415. Faris, S.F., *et al*. Urinary diversions after radiation for prostate cancer: indications and treatment. Urology, 2014. 84: 702.
https://pubmed.ncbi.nlm.nih.gov/25168555/
416. Rosenbaum, C.M., *et al*. The T-plasty as therapy for recurrent bladder neck stenosis: success rate, functional outcome, and patient satisfaction. World journal of urology, 2017. 35: 1907.
https://pubmed.ncbi.nlm.nih.gov/28929299/
417. Shu, H.Q., *et al*. Laparoscopic T-Plasty for the Treatment of Refractory Bladder Neck Stenosis. Am J Mens Health, 2019. 13: 1557988319873517.
https://pubmed.ncbi.nlm.nih.gov/31470756/
418. Musch, M., *et al*. Robot-assisted laparoscopic Y-V plasty in 12 patients with refractory bladder neck contracture. J Robot Surg, 2018. 12: 139.
https://pubmed.ncbi.nlm.nih.gov/28451939/
419. Avallone, M.A., *et al*. Robotic-assisted Laparoscopic Subtrigonal Inlay of Buccal Mucosal Graft for Treatment of Refractory Bladder Neck Contracture. Urology, 2019. 130: 209.
https://pubmed.ncbi.nlm.nih.gov/31063762/
420. Kulkarni, S.B., *et al*. Management of post TURP strictures. World J Urol, 2019. 37: 589.
https://pubmed.ncbi.nlm.nih.gov/30267196/
421. Sapienza, L.G., *et al*. Efficacy and Incontinence Rates After Urethroplasty for Radiation-induced Urethral Stenosis: A Systematic Review and Meta-analysis. Urology, 2021. 152: 109.
https://pubmed.ncbi.nlm.nih.gov/33631205/
422. Rourke, K., *et al*. Observations and outcomes of urethroplasty for bulbomembranous stenosis after radiation therapy for prostate cancer. World J Urol, 2016. 34: 377.
https://pubmed.ncbi.nlm.nih.gov/26047655/
423. Chi, A.C., *et al*. Urethral strictures and the cancer survivor. Curr Opin Urol, 2014. 24: 415.
https://pubmed.ncbi.nlm.nih.gov/24809412/
424. Patil, M.B., *et al*. Total bladder and posterior urethral reconstruction: salvage technique for defunctionalized bladder with recalcitrant posterior urethral stenosis. J Urol, 2015. 193: 1649.
https://pubmed.ncbi.nlm.nih.gov/25534328/
425. Pisters, L.L., *et al*. Salvage prostatectomy with continent catheterizable urinary reconstruction: a novel approach to recurrent prostate cancer after radiation therapy. J Urol, 2000. 163: 1771.
https://pubmed.ncbi.nlm.nih.gov/10799179/
426. Ullrich, N.F., *et al*. A technique of bladder neck closure combining prostatectomy and intestinal interposition for unsalvageable urethral disease. J Urol, 2002. 167: 634.
https://pubmed.ncbi.nlm.nih.gov/11792934/
427. De, E., *et al*. Salvage prostatectomy with bladder neck closure, continent catheterizable stoma and bladder augmentation: feasibility and patient reported continence outcomes at 32 months. J Urol, 2007. 177: 2200.
https://pubmed.ncbi.nlm.nih.gov/17509319/

428. Spahn, M., *et al*. Last resort in devastated bladder outlet: bladder neck closure and continent vesicostomy--long-term results and comparison of different techniques. Urology, 2010. 75: 1185.
https://pubmed.ncbi.nlm.nih.gov/20206979/
429. Sack, B.S., *et al*. Cystectomy and Urinary Diversion for the Management of a Devastated Lower Urinary Tract Following Prostatic Cryotherapy and/or Radiotherapy. Wmj, 2016. 115: 70.
https://pubmed.ncbi.nlm.nih.gov/27197339/
430. Lumen, N., *et al*. Perineal anastomotic urethroplasty for posttraumatic urethral stricture with or without previous urethral manipulations: a review of 61 cases with long-term followup. J Urol, 2009. 181: 1196.
https://pubmed.ncbi.nlm.nih.gov/19152939/
431. Koraitim, M.M. Complex pelvic fracture urethral distraction defects revisited. Scandinavian journal of urology, 2014. 48: 84.
https://pubmed.ncbi.nlm.nih.gov/23883274/
432. Kulkarni, S.B., *et al*. Posterior urethral stricture after pelvic fracture urethral distraction defects in developing and developed countries, and choice of surgical technique. J Urol, 2010. 183: 1049.
https://pubmed.ncbi.nlm.nih.gov/20092843/
433. Barbagli, G., *et al*. The spectrum of pelvic fracture urethral injuries and posterior urethroplasty in an Italian high-volume centre, from 1980 to 2013. Arab journal of urology, 2015. 13: 32.
https://pubmed.ncbi.nlm.nih.gov/26019976/
434. Cai, W., *et al*. Bipolar plasma vaporization using plasma-cutting and plasma-loop electrodes versus cold-knife transurethral incision for the treatment of posterior urethral stricture: a prospective, randomized study. Clinics (Sao Paulo), 2016. 71: 1.
https://pubmed.ncbi.nlm.nih.gov/26872076/
435. Tausch, T.J., *et al*. Unintended negative consequences of primary endoscopic realignment for men with pelvic fracture urethral injuries. J Urol, 2014. 192: 1720.
https://pubmed.ncbi.nlm.nih.gov/24972309/
436. Horiguchi, A., *et al*. Primary Realignment for Pelvic Fracture Urethral Injury Is Associated With Prolonged Time to Urethroplasty and Increased Stenosis Complexity. Urology, 2017. 108: 184.
https://pubmed.ncbi.nlm.nih.gov/28606774/
437. Hong, Y.K., *et al*. Predictors for success of internal urethrotomy in patients with urethral contracture following perineal repair of pelvic fracture urethral injuries. Injury, 2017. 48: 1035.
https://pubmed.ncbi.nlm.nih.gov/28259378/
438. Hussain, A., *et al*. Outcome of end-to-end urethroplasty in post-traumatic stricture of posterior urethra. Journal of the College of Physicians and Surgeons--Pakistan : JCPSP, 2013. 23: 272.
https://pubmed.ncbi.nlm.nih.gov/23552538/
439. Helmy, T.E., *et al*. Internal urethrotomy for recurrence after perineal anastomotic urethroplasty for posttraumatic pediatric posterior urethral stricture: could it be sufficient? Journal of endourology, 2013. 27: 693.
https://pubmed.ncbi.nlm.nih.gov/23441683/
440. Ali, S., *et al*. Delayed Single Stage Perineal Posterior Urethroplasty. Journal of the College of Physicians and Surgeons--Pakistan : JCPSP, 2015. 25: 438.
https://pubmed.ncbi.nlm.nih.gov/26100998/
441. Fu, Q., *et al*. Use of anastomotic urethroplasty with partial pubectomy for posterior urethral obliteration injuries: 10 years experience. World journal of urology, 2009. 27: 695.
https://pubmed.ncbi.nlm.nih.gov/19238398/
442. Kulkarni, S.B., *et al*. Management of complex and redo cases of pelvic fracture urethral injuries. Asian journal of urology, 2018. 5: 107.
https://pubmed.ncbi.nlm.nih.gov/29736373/
443. Mundy, A.R., *et al*. Urethral trauma. Part II: Types of injury and their management. BJU international, 2011. 108: 630.
https://pubmed.ncbi.nlm.nih.gov/21854524/
444. Gomez, R.G., *et al*. SIU/ICUD Consultation on Urethral Strictures: Pelvic fracture urethral injuries. Urology, 2014. 83: S48.
https://pubmed.ncbi.nlm.nih.gov/24210734/
445. Koraitim, M.M. Transpubic urethroplasty revisited: total, superior, or inferior pubectomy? Urology, 2010. 75: 691.
https://pubmed.ncbi.nlm.nih.gov/19962726/
446. Xu, Y.M., *et al*. Surgical treatment of 31 complex traumatic posterior urethral strictures associated with urethrorectal fistulas. European urology, 2010. 57: 514.
https://pubmed.ncbi.nlm.nih.gov/19282100/

447. Koraitim, M.M., *et al*. Perineal repair of pelvic fracture urethral injury: in pursuit of a successful outcome. BJU international, 2015. 116: 265.
https://pubmed.ncbi.nlm.nih.gov/24552421/
448. Zhang, L., *et al*. The application of valgus urethral mucosa anastomosis in the operation of posterior urethral stricture. International urology and nephrology, 2015. 47: 491.
https://pubmed.ncbi.nlm.nih.gov/25613432/
449. Gomez, R.G., *et al*. Reconstruction of Pelvic Fracture Urethral Injuries With Sparing of the Bulbar Arteries. Urology, 2016. 88: 207.
https://pubmed.ncbi.nlm.nih.gov/26616094/
450. Verla, W., *et al*. Vessel-sparing Excision and Primary Anastomosis. Journal of visualized experiments : JoVE, 2019.
https://pubmed.ncbi.nlm.nih.gov/30663665/
451. Xie, H., *et al*. Preliminary Experience of Nontransecting Urethroplasty for Pelvic Fracture-related Urethral Injury. Urology, 2017. 109: 178.
https://pubmed.ncbi.nlm.nih.gov/28735015/
452. Wang, P., *et al*. Modified urethral pull-through operation for posterior urethral stricture and long-term outcome. The Journal of urology, 2008. 180: 2479.
https://pubmed.ncbi.nlm.nih.gov/18930502/
453. Yin, L., *et al*. Urethral pull-through operation for the management of pelvic fracture urethral distraction defects. Urology, 2011. 78: 946.
https://pubmed.ncbi.nlm.nih.gov/21777964/
454. Unterberg, S.H., *et al*. Robotic-assisted Proximal Perineal Urethroplasty: Improving Visualization and Ergonomics. Urology, 2019. 125: 230.
https://pubmed.ncbi.nlm.nih.gov/30452962/
455. Hosseini, J., *et al*. Effects of Anastomotic Posterior Urethroplasty (Simple or Complex) on Erectile Function: a Prospective Study. Urol J, 2018. 15: 33.
https://pubmed.ncbi.nlm.nih.gov/29299889/
456. Tang, C.Y., *et al*. Erectile dysfunction in patients with traumatic urethral strictures treated with anastomotic urethroplasty: a single-factor analysis. The Canadian journal of urology, 2012. 19: 6548.
https://pubmed.ncbi.nlm.nih.gov/23228290/
457. Feng, C., *et al*. The relationship between erectile dysfunction and open urethroplasty: a systematic review and meta-analysis. The journal of sexual medicine, 2013. 10: 2060.
https://pubmed.ncbi.nlm.nih.gov/23656595/
458. El-Assmy, A., *et al*. Erectile dysfunction post-perineal anastomotic urethroplasty for traumatic urethral injuries: analysis of incidence and possibility of recovery. International urology and nephrology, 2015. 47: 797.
https://pubmed.ncbi.nlm.nih.gov/25778817/
459. Koraitim, M.M. Predictors of erectile dysfunction post pelvic fracture urethral injuries: a multivariate analysis. Urology, 2013. 81: 1081.
https://pubmed.ncbi.nlm.nih.gov/23465164/
460. Anger, J.T., *et al*. Ejaculatory profiles and fertility in men after posterior urethroplasty for pelvic fracture-urethral distraction defect injuries. BJU international, 2008. 102: 351.
https://pubmed.ncbi.nlm.nih.gov/18702781/
461. El-Assmy, A., *et al*. Ejaculatory function after anastomotic urethroplasty for pelvic fracture urethral injuries. International urology and nephrology, 2015. 47: 497.
https://pubmed.ncbi.nlm.nih.gov/25655257/
462. Bagga, H.S., *et al*. The mechanism of continence after posterior urethroplasty. Arab journal of urology, 2015. 13: 60.
https://pubmed.ncbi.nlm.nih.gov/26019981/
463. Sa, Y., *et al*. Transperineal anastomotic urethroplasty for the treatment of pelvic fracture urethral distraction defects: a progressive surgical strategy. World J Urol, 2021. 39: 4435.
https://pubmed.ncbi.nlm.nih.gov/34247286/
464. Mehmood, S., *et al*. Outcome of anastomotic posterior urethroplasty with various ancillary maneuvers for post-traumatic urethral injury. Does prior urethral manipulation affect the outcome of urethroplasty? Urology annals, 2018. 10: 175.
https://pubmed.ncbi.nlm.nih.gov/29719330/
465. Kulkarni, S.B., *et al*. Laparoscopic omentoplasty to support anastomotic urethroplasty in complex and redo pelvic fracture urethral defects. Urology, 2015. 85: 1200.
https://pubmed.ncbi.nlm.nih.gov/25818909/

466. Ibrahim, A.G., *et al*. Results of delayed repair of posterior urethral disruption injuries in Maiduguri. Surgical Practice, 2013. 17: 92.
https://www.researchgate.net/publication/263719232
467. Garg, G., *et al*. Outcome of patients with failed pelvic fracture-associated urethral repair: a single center 10-year experience. Turkish journal of urology, 2019. 45: 139.
https://www.ncbi.nlm.nih.gov/pmc/articles/PMC6368039/pdf/tju-45-2-139.pdf
468. Fu, Q., *et al*. Recurrence and complications after transperineal bulboprostatic anastomosis for posterior urethral strictures resulting from pelvic fracture: a retrospective study from a urethral referral centre. BJU international, 2013. 112: E358.
https://pubmed.ncbi.nlm.nih.gov/23773274/
469. Hwang, J.H., *et al*. Clinical factors that predict successful posterior urethral anastomosis with a gracilis muscle flap. Korean journal of urology, 2013. 54: 710.
https://pubmed.ncbi.nlm.nih.gov/24175047/
470. Podesta, M., *et al*. Delayed surgical repair of posttraumatic posterior urethral distraction defects in children and adolescents: long-term results. J Pediatr Urol, 2015. 11: 67 e1.
https://pubmed.ncbi.nlm.nih.gov/25869826/
471. Bhagat, S.K., *et al*. Redo-urethroplasty in pelvic fracture urethral distraction defect: an audit. World journal of urology, 2011. 29: 97.
https://pubmed.ncbi.nlm.nih.gov/20204376/
472. Gupta, N.P., *et al*. Does a previous end-to-end urethroplasty alter the results of redo end-to-end urethroplasty in patients with traumatic posterior urethral strictures? International journal of urology : official journal of the Japanese Urological Association, 2008. 15: 885.
https://pubmed.ncbi.nlm.nih.gov/18721207/
473. Mundy, A.R., *et al*. Entero-urethroplasty for the salvage of bulbo-membranous stricture disease or trauma. BJU international, 2010. 105: 1716.
https://pubmed.ncbi.nlm.nih.gov/19930173/
474. Goel, A., *et al*. Dorsal onlay buccal mucosal graft urethroplasty in female urethral stricture disease: a single-center experience. Int Urogynecol J, 2014. 25: 525.
https://pubmed.ncbi.nlm.nih.gov/24154743/
475. Popat, S., *et al*. Long-term management of luminal urethral stricture in women. Int Urogynecol J, 2016. 27: 1735.
https://pubmed.ncbi.nlm.nih.gov/27026141/
476. Sussman, R.D., *et al*. Gel-Infused Translabial Ultrasound in the Evaluation of Female Urethral Stricture. Female Pelvic Med Reconstr Surg, 2020. 26: 737.
https://pubmed.ncbi.nlm.nih.gov/30664026/
477. Massey, J.A., *et al*. Obstructed voiding in the female. Br J Urol, 1988. 61: 36.
https://pubmed.ncbi.nlm.nih.gov/3342298/
478. Romman, A.N., *et al*. Distal intramural urethral pathology in women. J Urol, 2012. 188: 1218.
https://pubmed.ncbi.nlm.nih.gov/22902013/
479. Akman, R.Y., *et al*. Geriatrik yaş grubu kadinlarda üretra darliklari tani ve tedavi. Turkish J Geriatr, 2013. 16.
http://geriatri.dergisi.org/abstract.php?lang=tr&id=735
480. Averous, M., *et al*. [Urethral stenosis in the young girl, myth or reality? Comparison of clinical, radiological, instrumental and urodynamic data (author's transl)]. J Urol (Paris), 1981. 87: 67.
https://pubmed.ncbi.nlm.nih.gov/7276599/
481. Heising, J., *et al*. [Meatus stenosis of girls--clinical demonstration and therapy (author's transl)]. Urologe A, 1978. 17: 292.
https://pubmed.ncbi.nlm.nih.gov/706007/
482. Schwender, C.E., *et al*. Technique and results of urethroplasty for female stricture disease. J Urol, 2006. 175: 976.
https://pubmed.ncbi.nlm.nih.gov/16469596/
483. Gormley, E.A. Vaginal flap urethroplasty for female urethral stricture disease. Neurourol Urodyn, 2010. 29 Suppl 1: S42.
https://pubmed.ncbi.nlm.nih.gov/20419801/
484. Gozzi, C., *et al*. Volar onlay urethroplasty for reconstruction of female urethra in recurrent stricture disease. BJU Int, 2011. 107: 1964.
https://pubmed.ncbi.nlm.nih.gov/21083639/
485. Tanello, M., *et al*. Use of pedicle flap from the labia minora for the repair of female urethral strictures. Urol Int, 2002. 69: 95.
https://pubmed.ncbi.nlm.nih.gov/12187036/

486. Migliari, R., *et al*. Dorsal buccal mucosa graft urethroplasty for female urethral strictures. J Urol, 2006. 176: 1473.
https://pubmed.ncbi.nlm.nih.gov/16952664/
487. Tsivian, A., *et al*. Dorsal graft urethroplasty for female urethral stricture. J Urol, 2006. 176: 611.
https://pubmed.ncbi.nlm.nih.gov/16813901/
488. Castillo, O.A., *et al*. [Urethroplasty with dorsal oral mucosa graft in female urethral stenosis]. Actas Urol Esp, 2011. 35: 246.
https://pubmed.ncbi.nlm.nih.gov/21397358/
489. Berglund, R.K., *et al*. Buccal mucosa graft urethroplasty for recurrent stricture of female urethra. Urology, 2006. 67: 1069.
https://pubmed.ncbi.nlm.nih.gov/16635524/
490. Hoag, N., *et al*. Vaginal-sparing ventral buccal mucosal graft urethroplasty for female urethral stricture: A novel modification of surgical technique. Investig Clin Urol, 2016. 57: 298.
https://pubmed.ncbi.nlm.nih.gov/27437540/
491. Katiyar, V.K., *et al*. Critical Analysis of Outcome Between Ventral and Dorsal Onlay Urethroplasty In Female Urethral Stricture. Urology, 2021. 157: 79.
https://pubmed.ncbi.nlm.nih.gov/34029605/
492. Petrou, S.P., *et al*. Dorsal vaginal graft urethroplasty for female urethral stricture disease. BJU Int, 2012. 110: E1090.
https://pubmed.ncbi.nlm.nih.gov/22594612/
493. Blander, D.S., *et al*. Endoluminal magnetic resonance imaging in the evaluation of urethral diverticula in women. Urology, 2001. 57: 660.
https://pubmed.ncbi.nlm.nih.gov/11306374/
494. de Rooij, F.P.W., *et al*. Surgical outcomes and proposal for a treatment algorithm for urethral strictures in transgender men. BJU Int, 2022. 129: 63.
https://pubmed.ncbi.nlm.nih.gov/34046987/
495. Lumen, N., *et al*. Endoscopic incision of short (<3 cm) urethral strictures after phallic reconstruction. Journal of endourology, 2009. 23: 1329.
https://pubmed.ncbi.nlm.nih.gov/19566413/
496. Lumen, N., *et al*. Urethroplasty for strictures after phallic reconstruction: a single-institution experience. Eur Urol, 2011. 60: 150.
https://pubmed.ncbi.nlm.nih.gov/21145648/
497. Schardein, J., *et al*. Staged Urethroplasty for Reconstruction of Long Complex Pendulous Strictures of a Neophallic Urethra. Urology, 2022. 164: e309.
https://pubmed.ncbi.nlm.nih.gov/35101545/
498. Pariser, J.J., *et al*. Buccal mucosal graft urethroplasty for the treatment of urethral stricture in the neophallus. Urology, 2015. 85: 927.
https://pubmed.ncbi.nlm.nih.gov/25681247/
499. Rossi Neto, R., *et al*. Gender reassignment surgery--a 13 year review of surgical outcomes. International braz j urol : official journal of the Brazilian Society of Urology, 2012. 38: 97.
https://pubmed.ncbi.nlm.nih.gov/22397771/
500. Waterloos, M., *et al*. Neo-vaginal advancement flaps in the treatment of urethral strictures in transwomen. Urology, 2019.
https://pubmed.ncbi.nlm.nih.gov/30779891/
501. Dubey, D., *et al*. Dorsal onlay buccal mucosa versus penile skin flap urethroplasty for anterior urethral strictures: results from a randomized prospective trial. The Journal of urology, 2007. 178: 2466.
https://pubmed.ncbi.nlm.nih.gov/17937943/
502. Sa, Y.L., *et al*. A comparative study of buccal mucosa graft and penile pedical flap for reconstruction of anterior urethral strictures. Chinese medical journal, 2010. 123: 365.
https://pubmed.ncbi.nlm.nih.gov/20193261/
503. Lumen, N., *et al*. Urethroplasty for urethral strictures: quality assessment of an in-home algorithm. International journal of urology : official journal of the Japanese Urological Association, 2010. 17: 167.
https://pubmed.ncbi.nlm.nih.gov/20070412/
504. Castagnetti, M., *et al*. Aptness and complications of labial mucosa grafts for the repair of anterior urethral defects in children and adults: single centre experience with 115 cases. World journal of urology, 2009. 27: 799.
https://pubmed.ncbi.nlm.nih.gov/19301012/
505. Patterson, J.M., *et al*. Surgical techniques in substitution urethroplasty using buccal mucosa for the treatment of anterior urethral strictures. European urology, 2008. 53: 1162.
https://pubmed.ncbi.nlm.nih.gov/18609764/

506. Levy, A.C., *et al*. Refractory Urethral Stricture Management: Indications for Alternative Grafts and Flaps. Current urology reports, 2018. 19: 20.
https://pubmed.ncbi.nlm.nih.gov/29479650/
507. Olajide, A.O., *et al*. Complications of transverse distal penile island flap: urethroplasty of complex anterior urethral stricture. Urol J, 2010. 7: 178.
https://pubmed.ncbi.nlm.nih.gov/20845294/
508. Langston, J.P., *et al*. Synchronous urethral stricture reconstruction via 1-stage ascending approach: rationale and results. The Journal of urology, 2009. 181: 2161.
https://pubmed.ncbi.nlm.nih.gov/19296985/
509. Marchal, C., *et al*. Barbagli's dorsal urethroplasty. Analysis of results and factors for success. Archivos espanoles de urologia, 2010. 63: 537.
https://pubmed.ncbi.nlm.nih.gov/20876950/
510. Schwentner, C., *et al*. Anterior urethral reconstruction using the circular fasciocutaneous flap technique: long-term follow-up. World journal of urology, 2011. 29: 115.
https://pubmed.ncbi.nlm.nih.gov/20379722/
511. Onol, S.Y., *et al*. Reconstruction of strictures of the fossa navicularis and meatus with transverse island fasciocutaneous penile flap. The Journal of urology, 2008. 179: 1437.
https://pubmed.ncbi.nlm.nih.gov/18295281/
512. Whitson, J.M., *et al*. Long-term efficacy of distal penile circular fasciocutaneous flaps for single stage reconstruction of complex anterior urethral stricture disease. The Journal of urology, 2008. 179: 2259.
https://pubmed.ncbi.nlm.nih.gov/18423682/
513. Mostafa, D., *et al*. Twin penile skin flap, is it the answer for repair of long anterior urethral strictures? Arab J Urol, 2018. 16: 224.
https://pubmed.ncbi.nlm.nih.gov/29892487/
514. Rogers, H.S., *et al*. Long-term results of one-stage scrotal patch urethroplasty. Br J Urol, 1992. 69: 621.
https://pubmed.ncbi.nlm.nih.gov/1638346/
515. Gil-Vernet, A., *et al*. Scrotal flap epilation in urethroplasty: concepts and technique. J Urol, 1995. 154: 1723.
https://pubmed.ncbi.nlm.nih.gov/7563332/
516. Gil-Vernet, J., *et al*. A new biaxial epilated scrotal flap for reconstructive urethral surgery. J Urol, 1997. 158: 412.
https://pubmed.ncbi.nlm.nih.gov/9224314/
517. Jasionowska, S., *et al*. Anterior Urethroplasty for the Management of Urethral Strictures in Males: A Systematic Review. Urology, 2022. 159: 222.
https://pubmed.ncbi.nlm.nih.gov/34537198/
518. Trivedi, S., *et al*. Urethral reconstruction in balanitis xerotica obliterans. Urologia internationalis, 2008. 81: 285.
https://pubmed.ncbi.nlm.nih.gov/18931544/
519. Tyagi, S., *et al*. 'Pee'BuSt Trial: A single-centre prospective randomized study comparing functional and anatomic outcomes after augmentation urethroplasty with penile skin graft versus buccal mucosa graft for anterior urethral stricture disease. World J Urol, 2022. 40: 475.
https://pubmed.ncbi.nlm.nih.gov/34655304/
520. Sharma, G., *et al*. Buccal mucosa or penile skin for substitution urethroplasty: A systematic review and meta-analysis. Indian J Urol, 2020. 36: 81.
https://pubmed.ncbi.nlm.nih.gov/32549657/
521. Sharma, A.K., *et al*. Lingual versus buccal mucosa graft urethroplasty for anterior urethral stricture: a prospective comparative analysis. International journal of urology : official journal of the Japanese Urological Association, 2013. 20: 1199.
https://pubmed.ncbi.nlm.nih.gov/23601029/
522. Lumen, N., *et al*. Buccal Versus Lingual Mucosa Graft in Anterior Urethroplasty: A Prospective Comparison of Surgical Outcome and Donor Site Morbidity. The Journal of urology, 2016. 195: 112.
https://pubmed.ncbi.nlm.nih.gov/26241906/
523. Abrate, A., *et al*. Lingual mucosal graft urethroplasty 12 years later: Systematic review and meta-analysis. Asian journal of urology, 2019. 6: 230.
https://pubmed.ncbi.nlm.nih.gov/31297314/
524. Chauhan, S., *et al*. Outcome of buccal mucosa and lingual mucosa graft urethroplasty in the management of urethral strictures: A comparative study. Urology annals, 2016. 8: 36.
https://pubmed.ncbi.nlm.nih.gov/26834399/

525. Pal, D.K., *et al*. A comparative study of lingual mucosal graft urethroplasty with buccal mucosal graft urethroplasty in urethral stricture disease: An institutional experience. Urology annals, 2016. 8: 157.
https://pubmed.ncbi.nlm.nih.gov/27141184/
526. Song, L.J., *et al*. Lingual mucosal grafts for anterior urethroplasty: a review. BJU international, 2009. 104: 1052.
https://pubmed.ncbi.nlm.nih.gov/19583725/
527. Manoj, B., *et al*. Postauricular skin as an alternative to oral mucosa for anterior onlay graft urethroplasty: a preliminary experience in patients with oral mucosa changes. Urology, 2009. 74: 345.
https://pubmed.ncbi.nlm.nih.gov/19428075/
528. Xu, Y.M., *et al*. Urethral reconstruction using colonic mucosa graft for complex strictures. The Journal of urology, 2009. 182: 1040.
https://pubmed.ncbi.nlm.nih.gov/19616803/
529. Mangera, A., *et al*. Tissue engineering in urethral reconstruction--an update. Asian J Androl, 2013. 15: 89.
https://pubmed.ncbi.nlm.nih.gov/23042444/
530. el-Kassaby, A., *et al*. Randomized comparative study between buccal mucosal and acellular bladder matrix grafts in complex anterior urethral strictures. The Journal of urology, 2008. 179: 1432.
https://pubmed.ncbi.nlm.nih.gov/18295282/
531. Fiala, R., *et al*. Porcine small intestinal submucosa graft for repair of anterior urethral strictures. Eur Urol, 2007. 51: 1702.
https://pubmed.ncbi.nlm.nih.gov/17306922/
532. Tang, X., *et al*. The Clinical Effects of Utilizing Allogeneic Acellular Dermal Matrix in the Surgical Therapy of Anterior Urethral Stricture. Urol Int, 2020. 104: 933.
https://pubmed.ncbi.nlm.nih.gov/33022676/
533. Xu, Y.M., *et al*. Outcome of small intestinal submucosa graft for repair of anterior urethral strictures. International journal of urology : official journal of the Japanese Urological Association, 2013. 20: 622.
https://pubmed.ncbi.nlm.nih.gov/23131085/
534. Palminteri, E., *et al*. Long-term results of small intestinal submucosa graft in bulbar urethral reconstruction. Urology, 2012. 79: 695.
https://pubmed.ncbi.nlm.nih.gov/22245298/
535. Ram-Liebig, G., *et al*. Results of Use of Tissue-Engineered Autologous Oral Mucosa Graft for Urethral Reconstruction: A Multicenter, Prospective, Observational Trial. EBioMedicine, 2017. 23: 185.
https://pubmed.ncbi.nlm.nih.gov/28827035/
536. Soave, A., *et al*. Substitution Urethroplasty with Closure Versus Nonclosure of the Buccal Mucosa Graft Harvest Site: A Randomized Controlled Trial with a Detailed Analysis of Oral Pain and Morbidity. European urology, 2018. 73: 910.
https://pubmed.ncbi.nlm.nih.gov/29198583/
537. Wong, E., *et al*. Does closure of the buccal mucosal graft bed matter? Results from a randomized controlled trial. Urology, 2014. 84: 1223.
https://pubmed.ncbi.nlm.nih.gov/25194996/
538. Rourke, K., *et al*. Effect of wound closure on buccal mucosal graft harvest site morbidity: results of a randomized prospective trial. Urology, 2012. 79: 443.
https://pubmed.ncbi.nlm.nih.gov/22119261/
539. Muruganandam, K., *et al*. Closure versus nonclosure of buccal mucosal graft harvest site: A prospective randomized study on post operative morbidity. Indian journal of urology : IJU : journal of the Urological Society of India, 2009. 25: 72.
https://pubmed.ncbi.nlm.nih.gov/19468433/
540. Terlecki, R.P., *et al*. Urethral rest: role and rationale in preparation for anterior urethroplasty. Urology, 2011. 77: 1477.
https://pubmed.ncbi.nlm.nih.gov/21513968/
541. McDonald, M.L., *et al*. Antimicrobial Practice Patterns for Urethroplasty: Opportunity for Improved Stewardship. Urology, 2016. 94: 237.
https://pubmed.ncbi.nlm.nih.gov/27138266/
542. Kim, S., *et al*. Antibiotic Stewardship and Postoperative Infections in Urethroplasties. Urology, 2021. 152: 142.
https://pubmed.ncbi.nlm.nih.gov/33373707/
543. Baas, W., *et al*. Antibiotic Duration After Urethroplasty: An Attempt at Improving Antibiotic Stewardship. Urology, 2021. 158: 228.
https://pubmed.ncbi.nlm.nih.gov/34380052/

544. Beckley, I., *et al*. Post-operative care following primary optical urethrotomy: towards an evidence based approach. Journal of Clinical Urology, 2012. 6: 164.
https://journals.sagepub.com/doi/10.1016/j.bjmsu.2012.04.006
545. Erickson, B.A., *et al*. A prospective, randomized trial evaluating the use of hydrogel coated latex versus all silicone urethral catheters after urethral reconstructive surgery. The Journal of urology, 2008. 179: 203.
https://pubmed.ncbi.nlm.nih.gov/18001794/
546. Poelaert, F., *et al*. Duration of urethral catheterization after urethroplasty: how long is enough? Minerva urologica e nefrologica = The Italian journal of urology and nephrology, 2017. 69: 372.
https://pubmed.ncbi.nlm.nih.gov/27097155/
547. Yeung, L.L., *et al*. Urethroplasty practice and surveillance patterns: a survey of reconstructive urologists. Urology, 2013. 82: 471.
https://pubmed.ncbi.nlm.nih.gov/23896103/
548. Peng, X.F., *et al*. Effectiveness of Solifenacin for Managing of Bladder Spasms in Patients With Urethroplasty. American journal of men's health, 2017. 11: 1580.
https://pubmed.ncbi.nlm.nih.gov/28669278/
549. Granieri, M.A., *et al*. A Critical Evaluation of the Utility of Imaging After Urethroplasty for Bulbar Urethral Stricture Disease. Urology, 2016. 91: 203.
https://pubmed.ncbi.nlm.nih.gov/26923442/
550. Solanki, S., *et al*. Evaluation of healing at urethral anastomotic site by pericatheter retrograde urethrogram in patients with urethral stricture. Urology annals, 2014. 6: 325.
https://pubmed.ncbi.nlm.nih.gov/25371610/
551. Sussman, R.D., *et al*. Novel pericatheter retrograde urethrogram technique is a viable method for postoperative urethroplasty imaging. International urology and nephrology, 2017. 49: 2157.
https://pubmed.ncbi.nlm.nih.gov/28913706/
552. Vetterlein, M.W., *et al*. Characterization of a Standardized Postoperative Radiographic and Functional Voiding Trial after 1-Stage Bulbar Ventral Onlay Buccal Mucosal Graft Urethroplasty and the Impact on Stricture Recurrence-Free Survival. The Journal of urology, 2019. 201: 563.
https://pubmed.ncbi.nlm.nih.gov/30240692/
553. Bansal, A., *et al*. Early removal of urinary catheter after excision and primary anastomosis in anterior urethral stricture. Turkish journal of urology, 2016. 42: 80.
https://pubmed.ncbi.nlm.nih.gov/27274892/
554. Beiske, M.J., *et al*. A comparison of urethral catheterization duration - three weeks versus two weeks after bulbar urethroplasty. Scand J Urol, 2021. 55: 313.
https://pubmed.ncbi.nlm.nih.gov/34223800/
555. Grossgold, E.T., *et al*. Routine Urethrography After Buccal Graft Bulbar Urethroplasty: The Impact of Initial Urethral Leak on Surgical Success. Urology, 2017. 104: 215.
https://pubmed.ncbi.nlm.nih.gov/28214570/
556. Verla, W., *et al*. POIROT trial: post-operative imaging after urethroplasty with peri-catheter retrograde urethrography or trial of voiding with voiding cysto-urethrography. World J Urol, 2022. 40: 1195.
https://pubmed.ncbi.nlm.nih.gov/35098358/
557. Granieri, M.A., *et al*. Critical Analysis of Patient-reported Complaints and Complications After Urethroplasty for Bulbar Urethral Stricture Disease. Urology, 2015. 85: 1489.
https://pubmed.ncbi.nlm.nih.gov/25868735/
558. Bandini, M., *et al*. Assessing in-hospital morbidity after urethroplasty using the European Association of Urology Quality Criteria for standardized reporting. World J Urol, 2021. 39: 3921.
https://pubmed.ncbi.nlm.nih.gov/33855598/
559. Erickson, B.A., *et al*. Definition of Successful Treatment and Optimal Follow-up after Urethral Reconstruction for Urethral Stricture Disease. Urol Clin North Am, 2017. 44: 1.
https://pubmed.ncbi.nlm.nih.gov/27908363/
560. Belsante, M.J., *et al*. Cost-effectiveness of risk stratified followup after urethral reconstruction: a decision analysis. J Urol, 2013. 190: 1292.
https://pubmed.ncbi.nlm.nih.gov/23583856/
561. Jackson, M.J., *et al*. A prospective patient-centred evaluation of urethroplasty for anterior urethral stricture using a validated patient-reported outcome measure. Eur Urol, 2013. 64: 777.
https://pubmed.ncbi.nlm.nih.gov/23664422/
562. Bertrand, L.A., *et al*. Measuring and Predicting Patient Dissatisfaction after Anterior Urethroplasty Using Patient Reported Outcomes Measures. J Urol, 2016.
https://pubmed.ncbi.nlm.nih.gov/26907509/

563. Kessler, T.M., *et al*. Patient satisfaction with the outcome of surgery for urethral stricture. J Urol, 2002. 167: 2507.
https://pubmed.ncbi.nlm.nih.gov/11992068/
564. Maciejewski, C.C., *et al*. Chordee and Penile Shortening Rather Than Voiding Function Are Associated With Patient Dissatisfaction After Urethroplasty. Urology, 2017. 103: 234.
https://pubmed.ncbi.nlm.nih.gov/28065809/
565. Levy, M., *et al*. The Impact of Age on Urethroplasty Success. Urology, 2017. 107: 232.
https://pubmed.ncbi.nlm.nih.gov/28579068/
566. Meeks, J.J., *et al*. Stricture recurrence after urethroplasty: a systematic review. J Urol, 2009. 182: 1266.
https://pubmed.ncbi.nlm.nih.gov/19683309/
567. Angermeier, K.W., *et al*. SIU/ICUD Consultation on Urethral Strictures: Evaluation and follow-up. Urology, 2014. 83: S8.
https://pubmed.ncbi.nlm.nih.gov/24275285/
568. Goonesinghe, S.K., *et al*. Flexible cystourethroscopy in the follow-up of posturethroplasty patients and characterisation of recurrences. Eur Urol, 2015. 68: 523.
https://pubmed.ncbi.nlm.nih.gov/25913391/
569. Seibold, J., *et al*. Urethral ultrasound as a screening tool for stricture recurrence after oral mucosa graft urethroplasty. Urology, 2011. 78: 696.
https://pubmed.ncbi.nlm.nih.gov/21741691/
570. Lozano, J.L., *et al*. [Substitution urethroplasty. Long term follow up results in a group of 50 patients]. Arch Esp Urol, 2015. 68: 424.
https://pubmed.ncbi.nlm.nih.gov/26033762/
571. Abdelhameed, H., *et al*. The long-term results of lingual mucosal grafts for repairing long anterior urethral strictures. Arab J Urol, 2015. 13: 128.
https://pubmed.ncbi.nlm.nih.gov/26413334/
572. Erickson, B.A., *et al*. Changes in uroflowmetry maximum flow rates after urethral reconstructive surgery as a means to predict for stricture recurrence. J Urol, 2011. 186: 1934.
https://pubmed.ncbi.nlm.nih.gov/21944128/
573. Anderson, K.T., *et al*. Defining Success after Anterior Urethroplasty: An Argument for a Universal Definition and Surveillance Protocol. J Urol, 2022. 208: 135.
https://pubmed.ncbi.nlm.nih.gov/35239415/
574. DeLong, J., *et al*. Patient-reported outcomes combined with objective data to evaluate outcomes after urethral reconstruction. Urology, 2013. 81: 432.
https://pubmed.ncbi.nlm.nih.gov/23374824/
575. Erickson, B.A., *et al*. The use of uroflowmetry to diagnose recurrent stricture after urethral reconstructive surgery. J Urol, 2010. 184: 1386.
https://pubmed.ncbi.nlm.nih.gov/20727546/
576. Warren, G.J., *et al*. The role of noninvasive testing and questionnaires in urethroplasty follow-up. Transl Androl Urol, 2014. 3: 221.
https://pubmed.ncbi.nlm.nih.gov/26816769/
577. Morey, A.F., *et al*. American Urological Association symptom index in the assessment of urethroplasty outcomes. J Urol, 1998. 159: 1192.
https://pubmed.ncbi.nlm.nih.gov/9507830/
578. Heyns, C.F., *et al*. Prospective evaluation of the American Urological Association symptom index and peak urinary flow rate for the followup of men with known urethral stricture disease. J Urol, 2002. 168: 2051.
https://pubmed.ncbi.nlm.nih.gov/12394706/
579. Wessels, S.G., *et al*. Prospective evaluation of a new visual prostate symptom score, the international prostate symptom score, and uroflowmetry in men with urethral stricture disease. Urology, 2014. 83: 220.
https://pubmed.ncbi.nlm.nih.gov/24231222/
580. Schober, J.P., *et al*. Effect of Urethroplasty on Anxiety and Depression. J Urol, 2018. 199: 1552.
https://pubmed.ncbi.nlm.nih.gov/29408454/
581. Liu, J.S., *et al*. Practice Patterns in the Treatment of Urethral Stricture Among American Urologists: A Paradigm Change? Urology, 2015. 86: 830.
https://pubmed.ncbi.nlm.nih.gov/26216643/
582. Chung, P.H., *et al*. Evaluation of Generic Versus Condition-Specific Quality of Life Indicators for Successful Urethral Stricture Surgery. Urology, 2019. 126: 222.
https://pubmed.ncbi.nlm.nih.gov/30580004/

583. Evans, P., *et al*. A Prospective Study of Patient-reported Pain After Bulbar Urethroplasty. Urology, 2018. 117: 156.
https://pubmed.ncbi.nlm.nih.gov/29656064/
584. Palminteri, E., *et al*. The impact of ventral oral graft bulbar urethroplasty on sexual life. Urology, 2013. 81: 891.
https://pubmed.ncbi.nlm.nih.gov/23434096/
585. Hoare, D.T., *et al*. Prospective Assessment of Patient-perceived Short-term Changes in Penile Appearance After Urethroplasty. Urology, 2021. 158: 222.
https://pubmed.ncbi.nlm.nih.gov/34461146/
586. Liu, J.S., *et al*. Risk Factors and Timing of Early Stricture Recurrence After Urethroplasty. Urology, 2016. 95: 202.
https://pubmed.ncbi.nlm.nih.gov/27155311/
587. Han, J.S., *et al*. Risk of urethral stricture recurrence increases over time after urethroplasty. Int J Urol, 2015. 22: 695.
https://pubmed.ncbi.nlm.nih.gov/25903524/
588. Zaid, U.B., *et al*. The cost of surveillance after urethroplasty. Urology, 2015. 85: 1195.
https://pubmed.ncbi.nlm.nih.gov/25819624/
589. Bonkat, G. *et al.* EAU Guidelines on Urological Infections. In: EAU Guidelines, edition presented at the annual EAU Congress Milan 2023. ISBN 978-94-92671-19-6.
https://uroweb.org/guidelines/urological-infections/

13. CONFLICT OF INTEREST

All members of the Urethral Strictures Guidelines Panel have provided disclosure statements of all relationships that they have that might be perceived as a potential source of a conflict of interest. This information is publicly accessible through the European Association of Urology website: http://www.uroweb.org/guidelines/.
This guidelines document was developed with the financial support of the European Association of Urology. No external sources of funding and support have been involved. The EAU is a non-profit organisation and funding is limited to administrative assistance and travel and meeting expenses. No honoraria or other reimbursements have been provided.

14. CITATION INFORMATION

The format in which to cite the EAU Guidelines will vary depending on the style guide of the journal in which the citation appears. Accordingly, the number of authors or whether, for instance, to include the publisher, location, or an ISBN number may vary.

The compilation of the complete Guidelines should be referenced as:
EAU Guidelines. Edn. presented at the EAU Annual Congress Madrid 2025. ISBN 978-94-92671-29-5.

If a publisher and/or location is required, include:
EAU Guidelines Office, Arnhem, the Netherlands. http://uroweb.org/guidelines/compilations-of-all-guidelines/

References to individual guidelines should be structured in the following way:
Contributors' names. Title of resource. Publication type. ISBN. Publisher and publisher location, year.

15. COPYRIGHT AND TERMS OF USE

The content of the EAU Guidelines and all products derived from them is made available for personal and educational use only. No commercial usage is authorised. No part of the EAU Guidelines or any related products may be translated or reproduced in any form without written permission from the EAU. Furthermore, the EAU prohibits the usage or upload of its Guidelines, and any material derived from these texts (whether in full or in part) on external websites, bots, pages, portals, servers, software, or external applications, including those employing artificial intelligence technologies and infrastructure, such as large language models and generative AI, deep learning and machine learning, unless written permission has been granted for such by the EAU.

The EAU accepts no responsibility for the content, quality, or performance of materials, applications and products derived from the EAU Guidelines and does not endorse or warrant their use. In the event of any discrepancies the original language version shall be considered authoritative.