

EAU GUIDELINES ON PAEDIATRIC UROLOGY

(Limited text update March 2020)

C. Radmayr (Chair), G. Bogaert, H.S. Dogan,
J.M. Nijman (Vice-chair), M.S. Silay, R. Stein, S. Tekgul
Guidelines Associates: N. Bhatt, L.A 't Hoen, J. Quaedackers

Introduction

Due to the scope of the extended Guidelines on Paediatric Urology, no attempt has been made to include all topics, but rather to provide a selection based on practical considerations.

PHIMOSIS

Background

At the end of the first year of life, retraction of the foreskin behind the glandular sulcus is possible in 50% of boys. The phimosis is either primary (physiological), with no sign of scarring, or secondary (pathological), resulting from scarring due to conditions such as balanitis xeroticaobliterans.

Phimosis must be distinguished from normal agglutination of the foreskin to the glans, which is a physiological phenomenon. If the tip remains narrow and glandular adhesions are separated, then the space is filled with urine during voiding, causing the foreskin to balloon outward.

Treatment

Conservative treatment

Administration of a corticoid ointment or cream is an option for primary phimosis with a success rate of > 90%, but with a

recurrence rate of 17%. Agglutination of the foreskin does not respond to steroid treatment.

Circumcision: indication and contraindication

Childhood circumcision should not be recommended without a medical reason. An absolute indication for circumcision is secondary phimosis. Contraindications for circumcision are acute local infection and congenital anomalies of the penis, particularly hypospadias or buried penis, as the foreskin may be required for a reconstructive procedure.

Plastic circumcision (dorsal incision, partial circumcision) carries the potential for recurrence of phimosis. Associated frenulum breve is corrected by frenulotomy. Meatoplasty is added if necessary.

Paraphimosis

It is characterised by retracted foreskin with the constrictive ring localised at the level of the sulcus. A dorsal incision of the constrictive ring may be required, or circumcision is carried out immediately or in a second session.

UNDESCENDED TESTES

Background

Cryptorchidism or undescended testis is one of the most common congenital malformations of male neonates. In newborn cases with non-palpable or undescended testes on both sides and any sign of disorders of sex development (DSD) like concomitant hypospadias, urgent endocrinological and genetic evaluation is required.

Classification

The term cryptorchidism is most often used synonymously for undescended testes. The most useful classification of undescended testes is into palpable and non-palpable testes, and clinical management is decided by the location and

presence of the testes. Approximately 80% of all undescended testes are palpable.

Palpable testes include true undescended testes and ectopic testes. Non-palpable testes include intra-abdominal, inguinal, absent, and sometimes also some ectopic testes.

Most importantly, the diagnosis of a palpable or non-palpable testis needs to be confirmed once the child is under general anaesthesia, as the first step of any surgical procedure for undescended testes. See Figure 1.

Diagnostic Evaluation

History taking and physical examination are key points in evaluating boys with undescended testes. Localisation studies using different imaging modalities are usually without any additional benefit.

Management

Treatment should be started at the age of six months. After that age, undescended testes rarely descend. Any kind of treatment leading to a scrotally positioned testis should be finished by twelve months, or eighteen months at the latest, because histological examination of undescended testes at that age has already revealed a progressive loss of germ and Leydig cells. The early timing of treatment is also driven by the final adult results on spermatogenesis and hormone production, as well as on the risk of tumour development. See Figure 2.

Medical therapy for testicular descent

Unfortunately, most of the studies on hormonal treatment have been of poor quality, with heterogeneous and mixed patient populations, testis location, schedules and dosages of hormonal administration. Additionally, long-term data are almost completely lacking.

Hormonal therapy using human chorionic gonadotropin

or gonadotrophin-releasing hormone (GnRH) is based on the hormonal dependence of testicular descent, but has a maximum success rate of only 20%. In general, success rates depend on testicular location. The higher the testis is located prior to therapy, the lower the success rate. The Panel consensus is that endocrine treatment to achieve testicular descent is not recommended.

Medical therapy for fertility potential

Hormonal treatment may improve fertility indices and therefore serve as an additional tool to orchidopexy. It is still unknown whether this effect on testicular histology persists into adulthood but it has been shown that men who were treated in childhood with buserelin had better semen analyses compared with men who had childhood orchidopexy alone or placebo treatment.

Identification of specific subgroups of boys with undescended testes who would benefit from such an approach using hormones is difficult. The Panel consensus recommends endocrine treatment with GnRH analogues for boys with bilateral undescended testes to preserve fertility potential.

Surgical Treatment

If a testis has not concluded its descent at the age of six months (corrected for gestational age), and since spontaneous testicular descent is unlikely to occur after that age, surgery should be performed within the subsequent year, at age eighteen months, at the latest.

Palpable testes

Surgery for palpable testes includes orchidofunicolysis and orchidopexy, either via an inguinal or scrotal approach.

Non-palpable testes

For non-palpable testes, surgery must clearly determine whether a testis is present or not. If a testis is found, the decision has to be made to remove it or bring it down to the scrotum.

An important step in surgery is a thorough re-examination once the boy is under general anaesthesia, since a previously non-palpable testis might be identifiable and subsequently change the surgical approach to standard inguinal orchidopexy, as described above. Otherwise, the easiest and most accurate way to locate an intra-abdominal testis is diagnostic laparoscopy. Subsequent removal or orchidolysis and orchidopexy can be carried out using the same approach to achieve the therapeutic aims.

In case of a vanishing testis, the procedure is finished once blind-ending spermatic vessels are clearly identified. If the vessels enter the inguinal canal, one may find an atrophic testis upon inguinal exploration or a healthy testis that needs to undergo standard orchidopexy. A peeping testis can be placed down in the scrotum laparoscopically or via an inguinal incision. Placement of an intra-abdominal testis can sometimes be a surgical challenge. Usually, testes lying > 2 cm above the internal inguinal ring may not reach the scrotum without division of the testicular vessels. Under such circumstances, a Fowler–Stephens orchidopexy might be an option.

Undescended testes and fertility

The association of undescended testes with compromised fertility is extensively discussed in the literature and seems to be a result of multiple factors, including germ cell loss, impaired germ cell maturation, Leydig cell diminution, and testicular fibrosis.

Although boys with one undescended testis have a lower fertility rate, they have the same paternity rate as those with bilateral descended testes. Boys with bilateral undescended testes suffer both lower fertility and paternity rates.

Regarding preservation of fertility potential, early surgical correction of undescended testes is highly recommended before twelve months of age, and by eighteen months at the latest.

Undescended testes and malignancy

Boys who are treated for an undescended testis have an increased risk of developing testicular malignancy. Screening and self-examination during and after puberty is therefore recommended.

Pre-pubertal orchidopexy may reduce the risk of testicular cancer and early surgical intervention is indicated in boys with undescended testes.

Recommendations	Strength rating
The Panel do not recommend medical or surgical treatment for retractile testes but recommend close follow-up on a yearly basis until puberty.	Strong
Perform surgical orchidolysis and orchidopexy before the age of twelve months, and by eighteen months at the latest.	Strong
Evaluate male neonates with bilateral non-palpable testes for possible disorders of sex development.	Strong
Perform a diagnostic laparoscopy to locate an intra-abdominal testicle.	Strong

Hormonal therapy in unilateral undescended testes is of no benefit for future paternity.	Weak
Offer endocrine treatment in case of bilateral undescended testes.	Weak
Inform the patient/caregivers about the increased risk of a later malignancy with an undescended testis in a post-pubertal boy or older and discuss removal in case of a contralateral normal testis in a scrotal position.	Weak

Figure 1: Classification of undescended testes

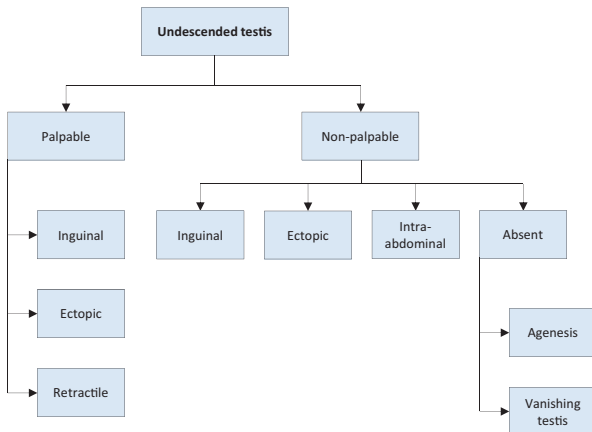
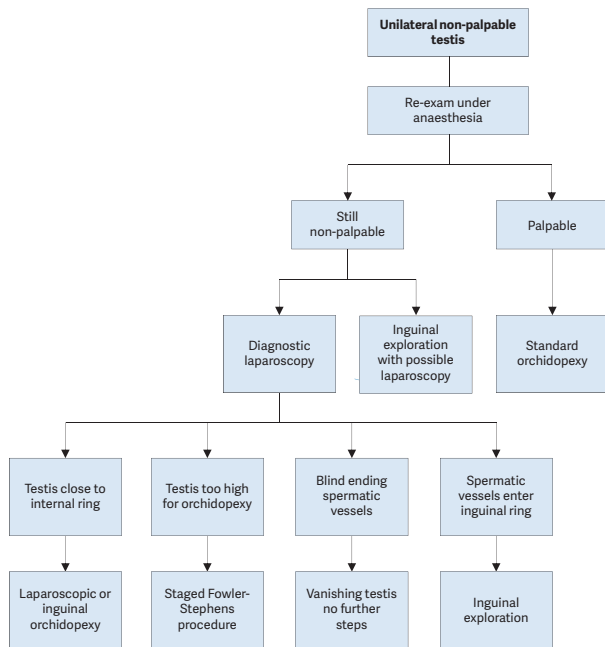


Figure 2: Algorithm for the management of unilateral non-palpable undescended testis



HYDROCELE Background

Non-communicating hydroceles are found secondary to minor trauma, testicular torsion, epididymitis, or varicocele operation, or may appear as a recurrence after primary repair of a communicating hydrocele.

A communicating hydrocele vacillates in size, usually relative to activity. It is diagnosed by medical history and

physical investigation, the swelling is translucent, and transillumination of the scrotum confirms the diagnosis. If there are any doubts about intra-scrotal mass, ultrasound (US) should be performed. Contralateral disease should be excluded.

Surgical Treatment

Surgical treatment of hydrocele is not indicated within the first 12-24 months because of the tendency for spontaneous resolution.

However, early surgery is indicated if there is suspicion of a concomitant inguinal hernia or underlying testicular pathology. There is no evidence that this type of hydrocele risks testicular damage.

The surgical procedure consists of ligation of the patent processus vaginalis via an inguinal incision, leaving the distal stump open, whereas in hydrocele of the cord, the cystic mass is excised or unroofed. Sclerosing agents should not be used because of the risk of chemical peritonitis in the communicating processus vaginalis peritonei.

The scrotal approach (Lord or Jaboulay technique) is used in the treatment of a secondary non-communicating hydrocele.

Recommendations	Strength rating
Observe hydrocele for twelve months prior to considering surgical treatment in the majority of infants.	Strong
Perform early surgery if there is suspicion of a concomitant inguinal hernia or underlying testicular pathology.	Strong
Perform a scrotal ultrasound in case of doubt about the character of an intra-scrotal mass.	Strong

Do not use sclerosing agents because of the risk for chemical peritonitis.	Strong
--	--------

HYPOSPADIAS

Background

Hypospadias are usually classified according to the anatomical location of the proximally displaced urethral orifice:

- distal - anterior hypospadias (glanular, coronal or distal penile);
- intermediate - middle (penile);
- proximal - posterior (penoscrotal, scrotal, perineal).

The pathology may be much more severe after skin release.

Diagnostic Evaluation

Patients with hypospadias should be diagnosed at birth.

The diagnostic evaluation also includes an assessment of associated anomalies, which include cryptorchidism and open processus vaginalis or inguinal hernia. Severe hypospadias with unilaterally or bilaterally impalpable testis, or with ambiguous genitalia, require a complete genetic and endocrine work-up immediately after birth to exclude disorders of sex development, especially congenital adrenal hyperplasia.

Trickling urine and ballooning of the urethra require exclusion of meatal stenosis.

The length of the hypospadiac penis may be distorted by penile curvature, penoscrotal transposition, or may be smaller due to hypogonadism.

Differentiation between functionally necessary and aesthetically feasible operative procedures is important for therapeutic decision-making. As all surgical procedures carry the risk of complications; thorough pre-operative counselling of the caregivers is crucial. The therapeutic objectives are to

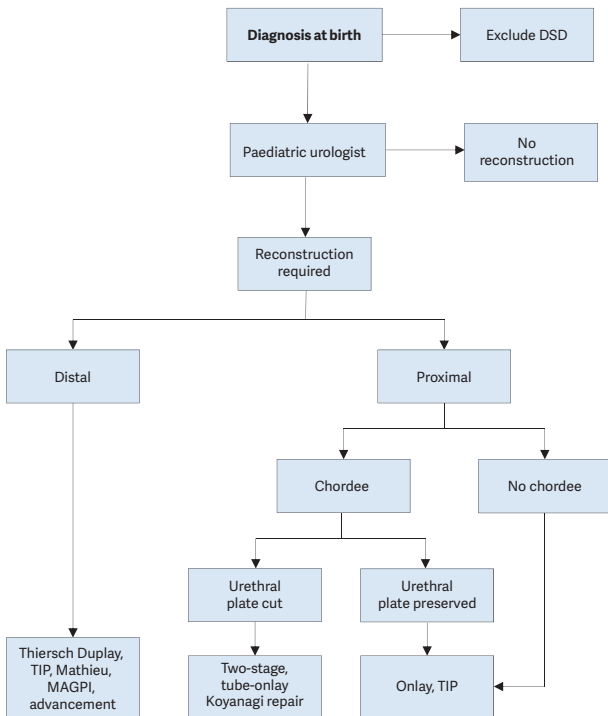
correct the penile curvature, to form a neourethra of an adequate size, to bring the neomeatus to the tip of the glans, if possible, and to achieve an overall acceptable cosmetic appearance. This goal is achieved by using different surgical techniques according to the individual findings.

Surgical Treatment

For repeat hypospadias repairs, no definitive guidelines can be given.

Excellent long-term functional and cosmetic results can be achieved after repair of anterior penile hypospadias. The complication rate in proximal hypospadias repair is higher. Figure 3 provides an algorithm for the management of hypospadias.

Figure 3: Algorithm for the management of hypospadias



DSD = disorders of sex development; GAP = glans approximation procedure; TIP = tubularised incised plate urethroplasty; MAGPI = meatal advancement and glanuloplasty incorporated.

MICROPENIS

Micropenis is defined as a small but otherwise normally formed penis with a stretched length of less than $2.5 \text{ cm} \pm$ standard deviation (SD) below the mean (Table 1).

Age	Mean \pm SD (cm)
Newborns	3.5 ± 0.4
0-5 months	3.9 ± 0.8
6-12 months	4.3 ± 0.8
1-2 years	4.7 ± 0.8
2-3 years	5.1 ± 0.9
3-4 years	5.5 ± 0.9
4-5 years	5.7 ± 0.9
5-6 years	6.0 ± 0.9
6-7 years	6.1 ± 0.9
7-8 years	6.2 ± 1.0
8-9 years	6.3 ± 1.0
9-10 years	6.3 ± 1.0
10-11 years	6.4 ± 1.1
Adults	13.3 ± 1.6

VARICOCELE IN CHILDREN AND ADOLESCENTS

Background

Varicocele is unusual in boys under ten years of age, but becomes more frequent at the beginning of puberty. Fertility problems will arise in about 20% of adolescents with varicocele. The adverse influence of varicocele increases with time.

Testicular catch-up growth and improvement in sperm parameters after varicocelectomy has been reported in adolescents. Varicocele is mostly asymptomatic, rarely

causing pain at this age. It may be noticed by the patient or caregivers, or discovered by the paediatrician at a routine visit. Diagnosis and classification depends upon the clinical finding and US investigation.

Surgical Treatment

Surgical intervention is based on ligation or occlusion of the internal spermatic veins. Microsurgical lymphatic-sparing repairs (microscopic or laparoscopic) are associated with the lowest recurrence and complication rates. There is no evidence that treatment of varicocele at paediatric age will offer a better andrological outcome than an operation performed later.

Conservative treatment and follow-up

During adolescence, testicular size should be checked annually. After adolescence, repeated sperm analysis is recommended. Figure 4 shows an algorithm for the diagnosis of varicocele in children and adolescents, and Figure 5 shows an algorithm for its treatment.

Figure 4: Algorithm for the diagnosis of varicocele in children and adolescents

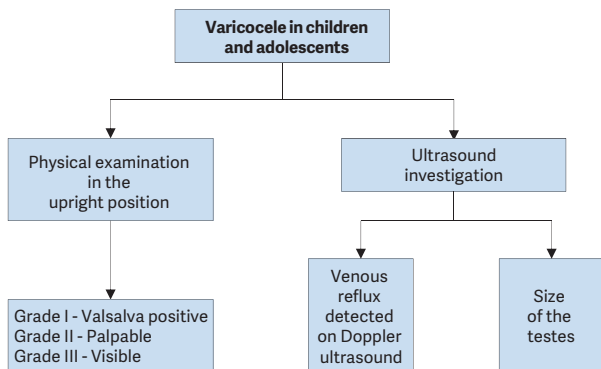
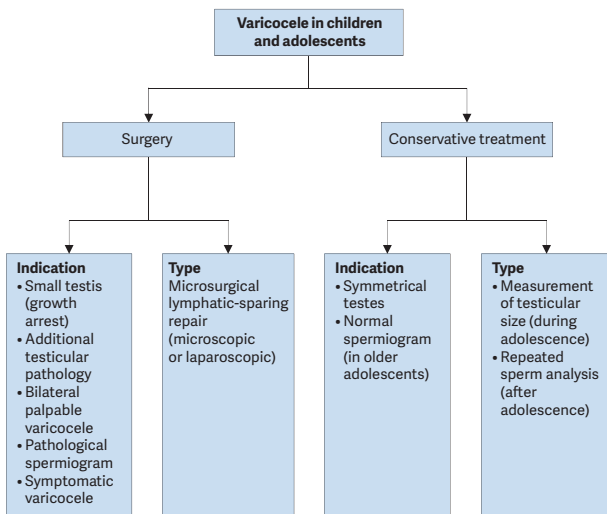


Figure 5: Algorithm for the management of varicocele in children and adolescents



URINARY TRACT INFECTIONS IN CHILDREN

Background

Urinary tract infections (UTIs) represent the most common bacterial infection in children. In neonates, the symptoms differ in many aspects from those in infants and children. The prevalence is higher; there is a male predominance; infections not caused by *Escherichia coli* are more frequent, and there is a higher risk of urosepsis.

- **Site:** Lower urinary tract (cystitis) versus upper urinary tract (pyelonephritis);
- **Episode:** first UTI versus unresolved infection, persistent infection and re-infection;

- **Severity:** simple UTI versus severe UTI;
- **Symptoms:** asymptomatic bacteriuria versus symptomatic UTI;
- **Complicating factors:** uncomplicated versus complicated UTI.

Diagnostic Evaluation

Diagnosis includes a medical history, searching for clinical signs and symptoms and a complete physical examination.

Urine sampling, analysis and culture

Urine sampling has to be performed before any antimicrobial agent is administered. The technique for obtaining urine is important to confirm or exclude UTI. Sampling in neonates, infants and non-toilet-trained children:

- **Plastic bag:** (high incidence of false positive results [85-99%]). Only helpful to exclude a UTI if the dipstick is negative for leukocyte esterase and the culture results are negative, otherwise the UTI has to be confirmed by a more specific method.
- **Clean-catch urine collection:** has a false-positive rate of 5% and false-negative rate of 12% and the contamination rate is higher compared to supra-pubic bladder aspiration (SPA).
- **Bladder catheterisation:** in female infants and in neonates, this technique may be an alternative to SPA, however with a higher contamination rate.
- **Supra-pubic bladder aspiration:** this is the most sensitive method to obtain an uncontaminated urine sample in non-toilet trained children.
- **Midstream urine:** in toilet-trained children who can void on command, could be an acceptable technique for obtaining urine after cleaning the urethral meatus and perineum.

Urinalysis:

- **Dipsticks:** are ready to use and helpful when the result is positive, because it is highly specific.
- **Microscopy:** can be used after centrifugation as well as in uncentrifuged urine and has been demonstrated to be sensitive for UTI. This is rarely done in an outpatient setting.
- **Flow imaging analysis technology:** is being increasingly used to classify particles in uncentrifuged urine specimens and correlates well with manual methods.
- **Urine culture:** is generally not necessary after negative results for dipstick, microscopic or automated urinalysis. If the dipstick result is positive, confirmation by urine culture is strongly recommended.

Pyuria without bacteriuria (sterile pyuria) may be due to incomplete antibiotic treatment, urolithiasis, or foreign bodies in the urinary tract, and infections caused by *Mycobacterium tuberculosis* or *Chlamydia trachomatis*.

Table 2: Criteria for UTI in children

Urine specimen from suprapubic bladder puncture	Urine specimen from bladder catheterisation	Urine specimen from midstream void
Any number of cfu/mL (at least 10 identical colonies)	$\geq 10^3 - 10^5$ cfu/mL	$\geq 10^4$ cfu/mL with symptoms $\geq 10^5$ cfu/mL without symptoms

Imaging

Ultrasound (US): of the kidneys and bladder as soon as possible is advised in infants with febrile UTI to exclude obstruction of the upper and lower urinary tract and post-void residual urine should be measured in toilet-trained children to exclude voiding abnormalities as a cause of UTI.

Radionuclide scanning: changes in dimercaptosuccinic acid (DMSA) clearance during acute UTI (up to four to six weeks) indicating pyelonephritis and renal scars can be detected after three to six months. This correlates well with the presence of dilating reflux and the risk of further pyelonephritis episodes, breakthrough infections and future renal scarring.

Voiding cystourethrography (VCUG): is best practice to exclude or confirm vesicoureteral reflux, due to the risk of renal scarring, VCUG is recommended after the first episode of febrile UTI in boys and girls depending on sex, age and clinical presentation (see Figure 6). Another option is doing DMSA first, followed by VCUG if there is renal cortical uptake deficiency after UTI.

Bladder and bowel dysfunction (BBD): are risk factors for which each child with UTI should be screened for upon presentation. If there are signs of BBD at infection-free intervals, further diagnosis and effective treatment are strongly recommended.

Status of circumcision should be checked in boys and treatment of the phimosis considered in those with pyelonephritis.

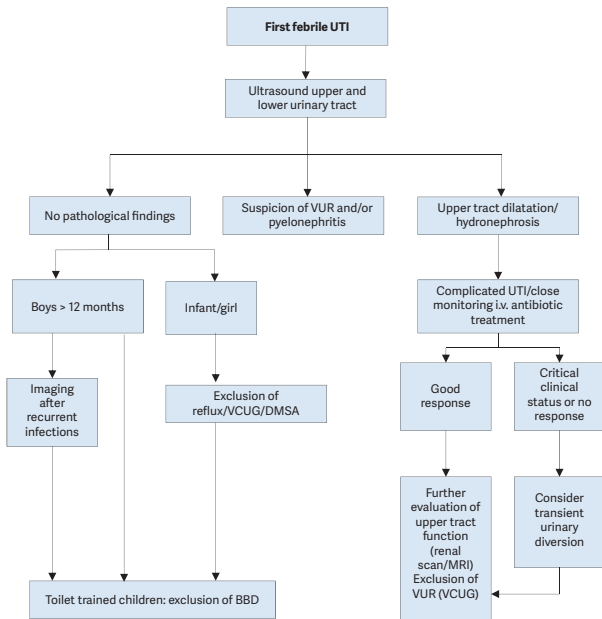
Management

Administration route: the choice between oral and parenteral therapy should be based on patient age; clinical suspicion of urosepsis; illness severity; refusal of fluids, food and/or oral medication; vomiting; diarrhoea; non-compliance; and complicated pyelonephritis (e.g. urinary obstruction). Febrile UTI in early infancy should be treated by i.v. fluids and antibiotics and under close monitoring within the hospital.

Duration of therapy: outcomes of short courses (one to three days) are inferior to those of seven to fourteen days. In late infancy, oral therapy with a third-generation cephalosporin (e.g. cefixime or ceftibuten) is equivalent to the usual two to four days intravenous therapy followed by oral treatment in

uncomplicated UTI's. In complicated UTI parenteral treatment with broad-spectrum antibiotics is preferred.

Figure 6: Algorithm for the management of a first febrile UTI



BBD = Bladder Bowel Dysfunction; DMSA = technetium⁹⁹-labelled dimercaptosuccinic acid; MRI = magnetic resonance imaging; UTI = urinary tract infection; VCUG = voiding cystourethrography; VUR = vesicoureteral reflux; i.v. = intravenous.

Monitoring of UTI

Urine usually becomes sterile after 24 hours, and leukocyturia disappears within three to four days. Normalisation of body temperature can be expected within 24-48 hours after the start of therapy in 90% of cases. In patients with prolonged fever and failing recovery, treatment-resistant uropathogens or the presence of congenital uropathy or acute urinary obstruction should be considered. Immediate US examination is recommended.

Procalcitonin (among other laboratory inflammatory parameters such as C-reactive protein and leukocyte count) is a reliable serum marker for early prediction of renal parenchymal inflammation. In patients with febrile UTI, serum electrolytes and blood cell counts should be obtained.

Recommendations	Strength rating
Take a medical history, assess clinical signs and symptoms and perform a physical examination to diagnose children suspected of having a urinary tract infection (UTI).	Strong
Exclude bladder and bowel dysfunction (BBD) in any child with febrile and/or recurrent UTI and do not delay diagnosis and treatment of BBD.	Strong
The most effective way to collect an uncontaminated urine sample in an infant is through suprapubic bladder aspiration, bladder catheterisation is an alternative with a higher contamination rate.	Strong

Do not use plastic bags for urine sampling in non-toilet-trained children since it has a high risk of false-positive results. Clean catch urine is an acceptable technique for toilet-trained children.	Strong
Urinalysis by dipstick yields rapid results, but it should be used with caution. Microscopic investigation is the standard method of assessing pyuria after centrifugation. Using flow imaging analysis, the numbers of white blood cells, squamous epithelial cells and red cells correlate well with manual methods.	Weak
The choice between oral and parenteral therapy should be based on patient age; clinical suspicion of urosepsis; illness severity; refusal of fluids, food and/or oral medication; vomiting; diarrhoea; noncompliance; complicated pyelonephritis.	Strong
Treat UTIs with four to seven day courses of oral or parenteral therapy.	Strong
Offer long-term antibacterial prophylaxis in case of high susceptibility to UTI and risk of acquired renal damage and lower urinary tract symptoms.	Weak
Treat complicated UTI, with broad-spectrum antibiotics (parenteral).	Weak
In infants with febrile UTI, use renal and bladder ultrasound to exclude obstruction of the upper and lower urinary tract.	Strong

In all infants, exclude vesicoureteral reflux (VUR) after the first episode of febrile UTI, using voiding cystourethrography (VCUG) or a dimercaptosuccinic acid (DMSA) scan first (in case of a positive DMSA-scan, follow-up with VCUG). In boys more than one year of age, exclude VUR after the second febrile UTI.	Strong
---	--------

MONOSYMPTOMATIC NOCTURNAL ENURESIS - BEDWETTING

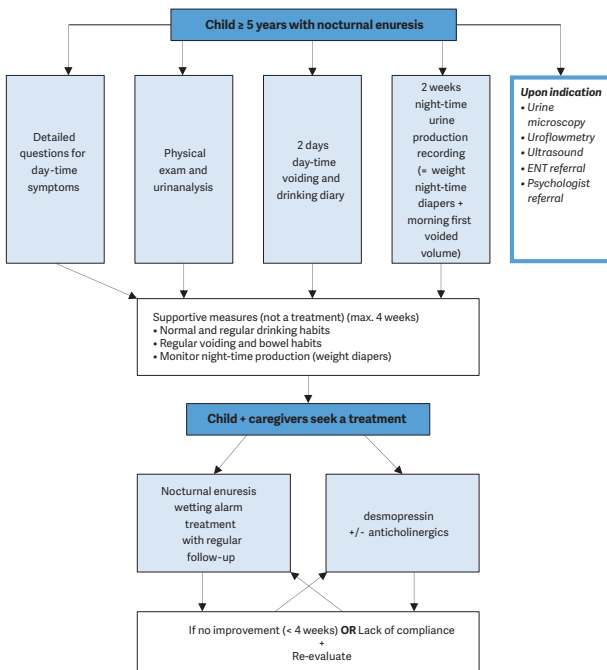
Background

Monosymptomatic nocturnal enuresis is incontinence during the night. Any wetting during sleep above the age of five years is considered nocturnal enuresis. It is important to note that there is a single symptom only. Due to an imbalance between night-time urine output and night-time bladder capacity, the bladder can easily become full at night, and the child will either wake-up to empty the bladder or will void during sleep.

Diagnostic Evaluation

A voiding diary, registering the day-time bladder function and the night-time urine output will help guide the treatment. Measuring the day-time bladder capacity gives an estimate of bladder capacity to compare with normal values for age. Figure 7 presents an algorithm for the diagnosis and treatment of monosymptomatic nocturnal enuresis.

Figure 7: Algorithm for the assessment and management of nocturnal enuresis



ENT = ear, nose, throat

VESICoureTERIC REFLUX IN CHILDREN

Background

Vesicoureteric reflux presents with a wide range of severities, and the majority of reflux (VUR) patients will not develop renal scars and probably will not need any intervention. The main goal in management is the preservation of kidney function.

Diagnostic evaluation

The diagnostic work-up should evaluate the overall health and development of the child. A basic diagnostic work-up includes a detailed medical history (including family history, and screening for lower urinary tract dysfunction [LUTD]), physical examination including blood pressure measurement, urinalysis (assessing proteinuria), urine culture, and serum creatinine in patients with bilateral renal parenchymal abnormalities.

Prenatally diagnosed hydronephrosis

Ultrasound of the kidney and bladder is the first standard evaluation tool for children with prenatally diagnosed hydronephrosis.

It should be delayed until the end of first week after birth because of early oliguria in the neonate. It is essential to evaluate the bladder, as well as the kidneys.

Recommendations	Strength rating
Inform parents of children with vesicoureteric reflux (VUR) that siblings and offspring have a high prevalence of VUR.	Strong
Use renal ultrasound (US) for screening of sibling(s).	Strong
Use voiding cystourethrography if there is evidence of renal scarring on US or a history of urinary tract infection.	Weak
Do not screen older toilet-trained children since there is no added value in screening for VUR.	Weak

Conservative therapy

The objective of conservative therapy is prevention of febrile UTI. It is based on the understanding that:

- VUR resolves spontaneously, mostly in young patients with low-grade reflux. However, spontaneous resolution is low in bilateral high-grade reflux.
- VUR does not damage the kidney when patients are free of infection and have a normal lower urinary tract function.
- There is no evidence that small scars can cause hypertension, renal insufficiency or problems during pregnancy and in the long-term.
- The conservative approach includes watchful waiting, intermittent or continuous antibiotic prophylaxis, and bladder rehabilitation in those with LUTD.
- Circumcision in early infancy may be considered as part of the conservative approach, because it is effective in reducing the risk of infection in normal children.

Surgical Treatment

Surgical treatment comprises endoscopic injection of bulking agents or ureteral re-implantation.

Subureteric injection of bulking agents: Due to the availability of biodegradable substances, endoscopic subureteric injection of bulking agents has become an alternative to long-term antibiotic prophylaxis and surgical intervention.

Open surgical techniques: Overall, all surgical procedures offer similar very high success rates for correcting VUR.

Laparoscopy: A laparoscopic approach cannot be recommended as a routine procedure. It can be offered as an alternative to the caregivers in centres where there is enough experience.

Recommendations	Strength rating
Initially treat all patients diagnosed within the first year of life with continuous antibiotic prophylaxis, regardless of the grade of reflux or presence of renal scars.	Weak
Offer immediate, parenteral antibiotic treatment for febrile breakthrough infections.	Strong
Offer definitive surgical or endoscopic correction to patients with frequent breakthrough infections.	Weak
Offer open surgical correction to patients with persistent high-grade reflux and endoscopic correction for lower grades of reflux.	Strong
Initially manage all children presenting at age one to five years conservatively.	Strong
Offer surgical repair to children above the age of one presenting with high-grade reflux and abnormal renal parenchyma.	Weak
Offer close surveillance without antibiotic prophylaxis to children presenting with lower grades of reflux and without symptoms.	Strong
Ensure that a detailed investigation for the presence of lower urinary tract dysfunction (LUTD) is done in all and especially in children after toilet-training. If LUTD is found, the initial treatment should always be for LUTD.	Strong
Offer surgical correction, if parents prefer definitive therapy to conservative management.	Strong

<p>Select the most appropriate management option based on:</p> <ul style="list-style-type: none"> • the presence of renal scars; • clinical course; • the grade of reflux; • ipsilateral renal function; • bilaterality; • bladder function; • associated anomalies of the urinary tract; • age and gender; • compliance; • parental preference. <p>Refer to Table 3 for risk factors and follow-up.</p>	Weak
<p>In high-risk patients who already have renal impairment, a more aggressive, multidisciplinary approach is needed.</p>	Strong

BASIC PRINCIPLES OF LAPAROSCOPIC SURGERY IN CHILDREN

The use of laparoscopy and robot-assisted laparoscopic surgery is rapidly increasing and has gained widespread acceptance for many urological surgeries in children. Diagnostic laparoscopy for undescended testis, nephrectomy, heminephrectomy, varicocelectomy, pyeloplasty, ureteral reimplantation are some of the indications which are commonly being performed. This expanding scope related to technological advancements allows surgeons to perform more complex procedures in a minimally invasive fashion even in infants and younger children. Generally, well-established benefits of minimally invasive surgery are decreased pain, shorter convalescence and better cosmetics compared to traditional open surgery. Additional advantages of robotic surgery over conventional laparoscopy include ergonomics, 3D vision, better manoeuvrability, decreased tremor and easy learning curve. Limitations to be considered are increased

operative time, smaller working space at young age, cost and experience of the surgeon and anesthesiologist.

As worldwide experience increases, there is an accumulating awareness about the physiological consequences related to intra- and retroperitoneal CO₂ insufflation in children. In contrast to traditional open surgery pneumoperitoneum may have physiological responses which require close monitoring during surgery and should be taken seriously.

Laparoscopy in children requires specific anesthetic precautions. Physiological effects of CO₂ pneumoperitoneum, positioning of the patient and in potentially increased operative time need to be considered by the anesthesiology team. Therefore, a detailed medical examination and risk assessment is mandatory preoperatively. Especially cardiac and pulmonary system should be assessed since increased intra-abdominal pressure may lead to decreased ventricular preload.

Pneumoperitoneal pressure (PnP in mmHg) is one of the critical points that needs to be carefully considered by laparoscopic surgeons. A recent RCT compared two different pneumoperitoneal pressure groups (6-8 mmHg vs. 9-10 mmHg) in infants less than 10 kg. It demonstrated that higher pressures were associated with more pronounced respiratory and hemodynamic changes as well as increased post-operative pain scores and prolonged time to resume feeding.

Recommendations	Strength rating
Use lower intra-abdominal pressure (6-8 mmHg) during laparoscopic surgery in infants and smaller children.	Strong
Use open access for laparoscopy in infants and smaller children.	Strong
Monitor for laparoscopy-related cardiac, pulmonary and diuretic responses.	Strong

This short booklet text is based on the more comprehensive EAU/ESPU Paediatric Urology Guidelines (ISBN 978-94-92671-07-3), available at their website, <http://www.uroweb.org/guidelines>.

Table 3: Management and follow-up according to different risk groups

Risk Groups	Presentation	Initial treatment
High	Symptomatic male or female patients after toilet-training with high-grade reflux (grades IV-V), abnormal kidneys and LUTD	Initial treatment is always for LUTD with CAP; intervention may be considered in cases of BT infections or persistent reflux
High	Symptomatic male or female patients after toilet-training with high-grade reflux (grade IV-V), abnormal kidneys and no LUTD	Intervention should be considered
Moderate	Symptomatic male or female patients before toilet-training, with high-grade reflux and abnormal kidneys	CAP is the initial treatment. Intervention may be considered in cases of BT infections or persistent reflux
Moderate	Asymptomatic patients (PNH or sibling) with high-grade reflux and abnormal kidneys	CAP is the initial treatment. Intervention may be considered in cases of BT, infections or persistent reflux
Moderate	Symptomatic male or female patients after toilet-training, with high-grade reflux and normal kidneys with LUTD	Initial treatment is always for LUTD with CAP. Intervention may be considered in cases of BT infections or persistent reflux

Comment	Follow-up
Greater possibility of earlier intervention	More aggressive follow-up for UTI and LUTD; full re-evaluation after 6 months
Open surgery has better results than endoscopic surgery	Post-operative VCUG on indication only; follow-up of kidney status until after puberty
Spontaneous resolution is higher in males	Follow-up for UTI/ hydronephrosis; full re-evaluation after 12-24 months
	Follow-up for UTI/ hydronephrosis; full re-evaluation after 12-24 months
In case of persistent LUTD, despite urotherapy, intervention should be considered. The choice of intervention is controversial	Follow-up for UTI and LUTD, kidney status; full re-evaluation after successful urotherapy

Moderate	Symptomatic male or female patients after toilet-training with low-grade reflux, abnormal kidneys with or without LUTD	Choice of treatment is controversial. Endoscopic treatment may be an option. LUTD treatment should be given if needed
Moderate	All symptomatic patients with normal kidneys, with low-grade reflux, with LUTD	Initial treatment is always for LUTD with or without CAP
Low	All symptomatic patients with normal kidneys, with low-grade reflux, with no LUTD	No treatment or CAP
Low	All asymptomatic patients with normal kidneys with low-grade reflux	No treatment or CAP in infants

BT = breakthrough; CAP = continuous antibiotic prophylaxis;

LUTD = lower urinary tract dysfunction;

PNH = prenatal diagnosed hydronephrosis;

UTI = urinary tract infection;

VCUG = voiding cystourethrography.

	Follow-up for UTI, LUTD, and kidney status until after puberty
	Follow-up for UTI and LUTD
If no treatment is given, parents should be informed about risk of infection	Follow-up for UTI
If no treatment is given, parents should be informed about risk of infection	Follow-up for UTI